This is a digital copy of a book that was preserved for generations on library shelves before it was carefully scanned by Google as part of a project to make the world's books discoverable online.

It has survived long enough for the copyright to expire and the book to enter the public domain. A public domain book is one that was never subject to copyright or whose legal copyright term has expired. Whether a book is in the public domain may vary country to country. Public domain books are our gateways to the past, representing a wealth of history, culture and knowledge that's often difficult to discover.

Marks, notations and other marginalia present in the original volume will appear in this file - a reminder of this book's long journey from the publisher to a library and finally to you.

Usage guidelines

Google is proud to partner with libraries to digitize public domain materials and make them widely accessible. Public domain books belong to the public and we are merely their custodians. Nevertheless, this work is expensive, so in order to keep providing this resource, we have taken steps to prevent abuse by commercial parties, including placing technical restrictions on automated querying.

We also ask that you:

+ *Make non-commercial use of the files* We designed Google Book Search for use by individuals, and we request that you use these files for personal, non-commercial purposes.

+ *Refrain from automated querying* Do not send automated queries of any sort to Google's system: If you are conducting research on machine translation, optical character recognition or other areas where access to a large amount of text is helpful, please contact us. We encourage the use of public domain materials for these purposes and may be able to help.

+ *Maintain attribution* The Google "watermark" you see on each file is essential for informing people about this project and helping them find additional materials through Google Book Search. Please do not remove it.

+ *Keep it legal* Whatever your use, remember that you are responsible for ensuring that what you are doing is legal. Do not assume that just because we believe a book is in the public domain for users in the United States, that the work is also in the public domain for users in other countries. Whether a book is still in copyright varies from country to country, and we can't offer guidance on whether any specific use of any specific book is allowed. Please do not assume that a book's appearance in Google Book Search means it can be used in any manner anywhere in the world. Copyright infringement liability can be quite severe.

About Google Book Search

Google's mission is to organize the world's information and to make it universally accessible and useful. Google Book Search helps readers discover the world's books while helping authors and publishers reach new audiences. You can search through the full text of this book on the web at `http://books.google.com/`

B 3 9015 00212 204 5
University of Michigan – BUHR

Digitized by Google



Digitized by Google

610.5
P3
S7
L8t

Digitized by Google

Digitized by Google

Digitized by Google

Digitized by Google

610.5
P3
S7
S8t
S-S-9

Digitized by Google

Digitized by Google

12351

TRANSACTIONS

OF THE

PATHOLOGICAL SOCIETY OF LONDON.

VOLUME FOURTH.

INCLUDING THE REPORT OF THE PROCEEDINGS FOR THE SESSION 1852-53.

LONDON:
PRINTED BY J. W. ROCHE, 1, ANN'S TERRACE.
1853.

Digitized by Google

THE COUNCIL have been enabled, by the number and value of the communications made to the Society during the Session 1852–53, to carry out the intention expressed in the last Annual Report, of publishing the Proceedings of the Society in the form of a complete Volume. The present publication—which constitutes the Seventh Annual Report of the Society's Proceedings—now appears as the Fourth Volume of Transactions.

The COUNCIL think it right to repeat that the exhibitors are alone responsible for the descriptions given of the Specimens exhibited by them, the only change made in the reports furnished by the authors, being such verbal alterations as were absolutely necessary.

33, GEORGE STREET, HANOVER SQUARE,
September, 1853.

Digitized by Google

TABLE OF CONTENTS

OF VOLUME IV.

	PAGE
Lists of Presidents; and of Officers and Members during the Session 1852–1853	v
Lists of Specimens Exhibited during the Session 1852–53	xvii
Diseases, &c., of the Nervous System	1
Diseases, &c., of the Respiratory Organs	35
Diseases, &c., of the Heart and other Organs of Circulation	61
Diseases, &c., of the Digestive Organs	121
Diseases, &c., of the Urinary and Generative Organs	180
Diseases, &c, of the Osseous System	242
Diseases of the Ear	251
Miscellaneous Specimens, Tumors, &c.	261
Index	279

Digitized by Google

Former Presidents.

ELECTED		
1846	...	C. J. B. WILLIAMS, M.D., F.R.S.
1848	...	C. ASTON KEY, Esq.
1850	...	P. MERE LATHAM, M.D.
1852	...	CÆSAR H. HAWKINS, Esq.

Digitized by Google

OFFICERS AND COUNCIL

OF

The Pathological Society of London.

ELECTED AT

THE GENERAL MEETING, JANUARY 4, 1853.

President.

BENJAMIN GUY BABINGTON, M.D., F.R.S.

Vice-Presidents.

PETER MERE LATHAM, M.D.
HENRY BENCE JONES, M.D., F.R.S.
JAMES COPLAND, M.D., F.R.S.
THOMAS B. PEACOCK, M.D.
WILLIAM FERGUSSON, Esq., F.R.S.
CÆSAR HAWKINS, Esq.
EDWARD STANLEY, Esq., F.R.S.
JOHN AVERY, Esq.

Treasurer.

ALEXANDER SHAW, Esq.

Council.

EDWARD BENTLEY, M.D.
WILLIAM BRINTON, M.D.
WILLIAM JENNER, M.D.
T. OGIER WARD, M.D.
JOHN HALL DAVIS, M.D.
CHARLES JOHN HARE, M.D.
C. J. B. WILLIAMS, M.D., F.R.S.
HENRY FULLER, M.D.
C. HANDFIELD JONES, M.D., F.R.S.
JOSEPH RIDGE, M.D.
WILLIAM ADAMS, Esq.
WILLIAM COULSON, Esq.
JOHN GAY, Esq.
JAMES DIXON, Esq.
ROBERT WOOLLASTON, Esq.
CARSTEN HOLTHOUSE, Esq.
MITCHELL HENRY, Esq.
EDWIN CANTON, Esq.
CHARLES BROOKE, Esq., F.R.S.
BARNARD HOLT, Esq.

Honorary Secretaries.

RICHARD QUAIN, M.D. | GEORGE POLLOCK, Esq.

Digitized by Google

Digitized by Google

LIST OF MEMBERS OF THE SOCIETY.

Honorary Members.

ALISON, WILLIAM PULTENEY, M.D., F.R.S., Professor of Medicine in the University of Edinburgh.

ANDRAL, G., M.D., Professor in the Faculty of Medicine, Paris.

*BENTLEY, EDWARD, M.D. (formerly Secretary), Physician to the City of London Hospital for Diseases of the Chest, Hackney.

CARSWELL, Sir ROBERT, M.D., Physician to his Majesty the King of the Belgians, Brussels.

CRAMPTON, Sir PHILIP, Bart., Surgeon-General to the Forces in Ireland.

CRUVEILHIER, J. C., M.D., Professor in the Faculty of Medicine, Paris.

HENLE, J., Professor of Anatomy and Physiology in the University of Zurich.

ROKITANSKY, CARL, M.D., Professor of Pathological Anatomy in the University of Vienna.

STOKES, WILLIAM, M.D., Regius Professor of Physic in the University of Dublin.

VOGEL, JULIUS, M.D., Professor of Clinical Medicine in the University of Giessen.

Resident and Non-Resident Members.

(C.) Present Members of Council. * Former Members of Council.

ORIGINAL MEMBERS, AND MEMBERS ELECTED IN SESSION 1846-47.

Adams, William, Esq., (C.) Assistant Surgeon to the Royal Orthopædic Hospital, 5, Henrietta-street, Cavendish-square.

*Arnott, James Moncrieff, Esq., F.R.S., 2, New Burlington-street.

Ashwell, Samuel, M.D., 16, Grafton-street, Bond-street.

Avery, John, Esq., (V.P.) Surgeon to the Charing Cross Hospital, 3, Queen-street, May-fair.

Digitized by Google

Babington, Benjamin Guy, M.D., F.R.S. (President) Physician to Guy's Hospital, 31, George-street, Hanover-square.

Barker, Thomas Herbert, M.D., Priory-terrace, Bedford.

*Barlow, George Hilaro, M.D., Physician to Guy's Hospital, 5, Union-street, Southwark.

Bennett, James Henry, M.D., 60, Grosvenor-street.

*Bennett, James Risden, M.D., Physician to St. Thomas's Hospital, and to the City of London Hospital for Diseases of the Chest, 15, Finsbury-square.

*Birkett, John, Esq., Surgeon to Guy's Hospital, 6, Wellington-street, Southwark.

*Bright, Richard, M.D., F.R.S., (late V.P.) Physician Extraordinary to the Queen, 11, Saville-row.

Brinton, William, M.D., (C.) Senior Physician to the Royal Free Hospital; Brook-street.

Brooke, Charles, M.B., F.R.S., (C.) Surgeon to Westminster Hospital, 29, Keppel-street, Russell-square.

Browne, Joseph Hullett, M.D., Euston-square.

*Busk, George, Esq., F.R.S., Surgeon to the Hospital-ship "Dreadnought," 2, Gloucester-place, Greenwich.

Camps, William, M.D., 52, Park-street, Grosvenor-square.

*Cheevers, Norman, M.D., H.E.I.C.S.

*Cock, Edward, Esq., Surgeon to Guy's Hospital, 12, St. Thomas's-street, Borough.

Cohen, Daniel Whittaker, M.D., Assistant Physician to St. Thomas's Hospital, 6, Cleveland-row, St. James's.

Copland, James, M.D., F.R.S., (V.P., late Treasurer) 5, Old Burlington-street.

Coulson, William, Esq., (C.) Surgeon to St. Mary's and the Magdalen Hospitals, Frederick's-place, Old Jewry.

*Crisp, Edwards, M.D., Physician to the Metropolitan Dispensary, 21, Parliament Street.

Davis, John Hall, M.D., (C.) Physician to the Royal Maternity Charity, 17, Russell-place, Fitzroy-square.

*Davies, Herbert, M.D., Assistant Physician to the London Hospital, 23, Finsbury-square.

*Day, George E., M.D., Professor of Anatomy and Medicine in the University of St. Andrews.

Dixon, James, Esq., (C.) Surgeon to the Royal London Ophthalmic Hospital, 45, Green-street, Park-lane.

Dudgeon, Robert E., M.D., 82, Gloucester-place, Portman-square.

Ellis, Joseph, Esq., Sudbrook Park.

*Erichsen, John E., Esq., Surgeon to University College Hospital, 48, Welbeck-street, Cavendish-square.

Digitized by Google

Fincham, George, M.D., Assistant Physician to Westminster Hospital, 28, Chapel-street, Belgrave-square.

Forster, John Cooper, Esq., Surgeon to the Surrey Dispensary, 11, Wellington-street, London Bridge.

Frere, J. C., Esq., Trinity College, Cambridge.

Fuller, Henry, M.D., (C.) Assistant Physician to St. George's Hospital, 13, Manchester-square.

*Garrod, Alfred Baring, M.D., Physician to University College Hospital, 63, Harley-street, Cavendish-square.

Gay, John, Esq., (C.) Surgeon to the Royal Free Hospital, 10, Finsbury-place South.

Gream, George T., M.D., 2, Upper Brook-street.

Hawkins, Cæsar H. Esq., (V.P., late President) Surgeon to St. George's Hospital, 26, Grosvenor-street.

*Hewett, Prescott G., Esq., Assistant Surgeon to St. George's Hospital, 35, Hertford-street, May-fair.

Hillman, William Augustus, Esq., Assistant Surgeon to Westminster Hospital, 1, Argyll-street, Regent-street.

*Hilton, John. Esq., F.R.S., Surgeon to Guy's Hospital, 10, New Broad-street.

Holman, H. Martin, M.D., Hurstpierpoint, Sussex.

Holthouse, Carsten, Esq., (C.) Assistant Surgeon to Westminster Hospital, 2, Serle-street, Lincoln's-inn-fields.

Jay, Edward, Esq., 51, Park-stret, Grosvenor-square.

*Jeaffreson, Henry, M.D., Assistant Physician to St. Bartholomew's Hospital, and Consulting Physician to the City of London Hospital for Diseases of the Chest, 2, Finsbury-square.

Jenner, William, M.D., (C.) Physician to Hospital for Sick Children, and Assistant Physician to University College Hospital, 8, Albany-street, Regent's Park.

*Johnson, George, M.D., Assistant Physician to King's College Hospital, and Physician to the Bishop's Court Dispensary, 3, Woburn-square.

*Johnson, Henry Charles, Esq., Surgeon to St. George's Hospital, 6, Saville-row.

*Jones, Henry Bence, M.D., F.R.S., (V.P.) Physician to St. George's Hospital, 30, Grosvenor-street.

Jones, Charles Handfield, M.D., F.R.S., (C.) Assistant Physician to St. Mary's Hospital, 1, Southwick-place, Cambridge-square.

Kent, Thomas J., Esq., Guy's Hospital.

*Lloyd, Edward, M.D., Physician to the Royal General Dispensary, 50, Jewin-street.

Digitized by Google

*Macintyre, William, M.D., Physician to the Western General Dispensary, 84, Harley-street.

Marshall, John, Esq., Assistant Surgeon to University College Hospital, 10, George-street, Hanover-square.

Merriman, S. W. J., M.D., Physician to the Royal Infirmary for Children.

Morison, Sir Alexander, Physician to Bethlem Hospital, 26, Cavendish-square.

Morgan, John, Esq., 5, Albion-place, Hyde-park-square.

*Partridge, Richard, Esq., F.R.S., (late V.P.) Surgeon to King's College Hospital, 17, New-street, Spring Gardens.

*Peacock, Thomas Bevill, M.D. (V.P., late Secretary) Assistant Physician to St. Thomas's Hospital, and Physician to the City of London Hospital for Diseases of the Chest, 20, Finsbury-circus.

*Phillips, Benjamin, Esq., F.R.S., Consulting Surgeon to the Westminster Hospital, 17, Wimpole-street.

Pilcher, George, Esq., Surgeon to the Surrey Dispensary, 2, Harley-street.

*Poland, Alfred, Esq., Assistant Surgeon to Guy's Hospital, 3, St. Thomas's-street, Southwark.

Pollock, George D., Esq., (C., late Secretary) Surgeon to North London Eye Infirmary, Assistant Surgeon to St. George's Hospital, 27, Grosvenor-street.

*Quain, Richard, M.D., (Honorary Secretary) Assistant Physician to the Hospital for Consumption and Diseases of the Chest at Brompton, 23, Harley-street, Cavendish-square.

*Ramsbotham, Francis H., M.D., (late V.P.), Physician Accoucheur to the London Hospital, 7, Portman-square.

Ray, Edward, Esq., Dulwich.

Ridge, Joseph, M.D., (C.) 39, Dorset-square.

Robinson, R. R., Esq., Camden-row, Camberwell.

*Roe, Hamilton George, M.D., Physician to the Westminster Hospital, and to the Hospital for Consumption and Diseases of the Chest, at Brompton, 26, Upper Brook-street.

Sankey, W. H. O., M.B., Resident Medical Officer, London Fever Hospital.

*Scott, John, M.D., 13, Stratton-street.

Seaton, Edward C., Surgeon to the Chelsea, Brompton, &c., Dispensary, 33, Sloane-street, Knightsbridge.

Sharp, H. L., Esq., 12, Great Cumberland-street, Hyde-park.

*Shaw, Alexander, Esq., (Treasurer) Surgeon to the Middlesex Hospital, 25, Henrietta-street, Cavendish-square.

*Simon, John, Esq., F.R.S., Surgeon to St. Thomas's Hospital, 3, Lancaster-place, Strand.

*Smith, Ebenezer Pye, Esq., 7, Billiter-square.

Digitized by Google

Smith, Protheroe, M.D., Physician to the Hospital for Women, 25, Park-street, Grosvenor-square.

Stafford, Richard A., Esq., F.R.S., Surgeon to the Marylebone Infirmary, 28, Old Burlington-street.

Tamplin, R. W., Esq., Surgeon to the Royal Orthopædic Hospital, 33, Old Burlington-street.

*Toynbee, Joseph, Esq., F.R.S., Surgeon Aurist to St. Mary's Hospital, 18, Saville-row.

Waite, Charles, M.D., 3, Old Burlington-street.

Walton, Henry Haynes, Esq., Assistant Surgeon to St. Mary's Hospital, 69, Brook-street.

Ward, Joseph, Esq., Epsom, Surrey.

*Ward, Nathaniel, Esq., (formerly Secretary) Assistant Surgeon to the London Hospital, 1, Broad-street-buildings.

Ward, T. Ogier, M.D., (C.) Surgeon to the Kensington Dispensary, 9, Leonard-place, Kensington.

Ware, James T., Esq., Surgeon to the Finsbury Dispensary, 51, Russell-square.

Williams, C. J. B., M.D., F.R.S., (C., formerly President) Consulting Physician to the Hospital for Consumption and Diseases of the Chest at Brompton, 49, Upper Brook-street.

Woollaston, Robert, Esq., (C.) 52, Gloster-terrace, Hyde-park.

MEMBERS ELECTED DURING THE SESSION 1847–48.

Aikin, C. A., Esq., 8, Southwick-street.

Fergusson, William, Esq., F.R.S. (V.P.) Surgeon to the King's College Hospital, 16, George-street, Hanover-square.

Hare, Charles John, M.D., (C.) Assistant Physician to University College Hospital, 9, Langham-place.

Heale, James Newton, M.D., Winchester.

Randall, John, M.D., 14, Portman-street, Portman-square.

Sieveking, E. H., M.D., Assistant Physician to St. Mary's Hospital, 3, Bentinck-street, Manchester-square.

*Solly, Samuel, Esq., F.R.S., Surgeon to St. Thomas's Hospital, 18, St. Helen's-place.

Tuke, T. Harrington, M.D., Manor-house, Chiswick.

MEMBERS ELECTED DURING THE SESSION 1848–49.

Bird, James, M.D., 27, Hyde-park-square.

Carpenter, William Guest, Esq., Surgeon to the City of London Dispensary, 1, West-street, Finsbury-circus.

Chalk, William Oliver, Esq., 3, Nottingham-terrace, Regent's-park.

Digitized by Google

Critchett, George, Esq., (formerly Secretary) Assistant Surgeon to the London Hospital, and to the Royal London Ophthalmic Hospital, 46, Finsbury-square.

Eden, T. E., Esq., 45, Threadneedle-street.

Gray, Henry, Esq., F.R.S., Surgeon to St. George's and St. James's Dispensary, 8, Wilton-street.

Henry, Mitchell, Esq., (Honorary Secretary) Assistant Surgeon to the Middlesex Hospital, 5, Harley-street.

Hogg, Charles, Esq., 14, Finsbury-place South.

Houlton, Joseph, Jun., Esq., 105, Lisson-grove.

*Little, William John, M.D., Physician to the London Hospital, 34, Brook-street.

Purnell, John James, Esq., Surgeon to the Royal General Dispensary, 34, Aldersgate-street, Charterhouse-square.

Sibson, Francis, M.D., F.R.S., Physician to St. Mary's Hospital, 40, Brook-street.

Tebay, William, Esq., Great Smith-street, Westminster.

MEMBERS ELECTED DURING THE SESSION 1849–50.

Ballard, Thomas, Esq., 10, Southwick-place, Hyde-park.

*Beith, Robert, M.D., R.N.

Birkett, Edmund Lloyd, M.D., Physician to the City of London Hospital for Diseases of the Chest, Curator of the Museum at Guy's Hospital, 4, Montague-street, Russell-square.

Blagden, Robert, Esq., Surgeon to the St. George's and St. James's Dispensary, 42, Curzon-street, May-fair.

Canton, Edwin, Esq., (C.) Assistant Surgeon to the Royal Westminster Ophthalmic Hospital, 31 A, Saville-row.

Clarke, John, L.R.C.P., Physician Accoucheur to St. George's and St. James's Dispensary, 3, Clifford-street.

Cooper, George F., M.D., Brentford.

Fincham, Warren, Esq., 5, Spring-gardens.

Foreman, R.C.. M.D., Colville House, Lowestoft.

Habershon, Samuel O., M.D., Demonstrator of Anatomy at Guy's Hospital, 48, Finsbury-circus.

Holt, Barnard, Esq., (C.) Surgeon to the Westminster Hospital, 5, Parliament-street.

Latham, Peter Mere, M.D., (V.P., late President), 37, Grosvenor-street.

Liddell, Sir John, C.B., M.D., F.R.S., Medical Inspector, Greenwich Hospital.

Littler, J. W., Esq., Edmonton.

MEMBERS ELECTED DURING THE SESSION 1850–51.

Baly, William, M.D., Physician to the Penitentiary, Millbank, 45, Queen Ann-street, Cavendish-square.

Benwell, Henry D., Esq., 2, Kent-place, Blackheath-hill.

Digitized by Google

Bowman, William, Esq., F.R.S., Assistant Surgeon to King's College Hospital, and to the Royal London Ophthalmic Hospital, 5, Clifford-street.

Bristowe, J. S., M.B., Demonstrator of Morbid Anatomy, and Curator of the Museum at St. Thomas's Hospital, North Addington-place, Camberwell.

Bullock, Henry, Esq., 15, Cumberland-street, Hyde-park.

Cooper, William White, Esq., Surgeon Oculist to St. Mary's Hospital, and Surgeon to North London Eye Infirmary, 19, Berkeley-square.

Dampier, Nathaniel John, Esq., Surgeon to the Farringdon General Dispensary, 50, Woburn-place, Russell-square.

Garrett, Mark Brown, Esq., 3, New-road, St. George's East.

Hodgson, Joseph, Esq., F.R.S., 60, Westbourne-terrace.

Hore, Henry A., Esq., House Surgeon, Bristol Infirmary.

Langmore, J. C., M.B., Surgeon to the Paddington Dispensary, 20, Oxford-terrace.

Obré, Henry, Esq., 1, Melcombe-place, Dorset-square.

Ogle, J. W., M.B., Physician to St. George's and St. James's Dispensary 13, Queen-street, Mayfair.

Pollock, James Edward, M.D., Physician to the Western General Dispensary, 4, Chandos-street, Cavendish-square.

Pyle, John, Esq., Surgeon to the North London Eye Infirmary, 56, Oxford-terrace, Hyde-park-square.

Simmons, James B., Esq., Royal Veterinary College.

Snow, John, M.D., 18, Sackville-street.

Stanley, Edward, Esq., F.R.S., (V.P.) Surgeon to St. Bartholomew's Hospital, 23 A, Brook-street.

Sutherland, Alexander John, M.D., Physician to St. Luke's Hospital, Richmond-terrace.

Tatum, Thomas, Esq., Surgeon to St. George's Hospital, 3, George-street, Hanover-square.

Wagstaff, W. R., M.D., 21, Langham-street.

West, Charles, M.D., Physician Accoucheur to St. Bartholomew's Hospital, 96, Wimpole-street.

Wood, John, Esq., Demonstrator of Anatomy, King's College.

MEMBERS ELECTED DURING THE SESSION 1851–52.

Allchin, W. H., M.B., 7, Pembridge-villas, Westbourne-grove.

Ashton, T. J., Esq., Surgeon to the Blenheim-street Dispensary, 31, Cavendish-square.

Barclay, A. White, M.D., Physician to the Chelsea, &c., Dispensary, 23 A, Bruton-street.

Beale, Lionel J., M.B., Professor of Physiology in King's College, 27, Carey-street, Lincoln's-inn.

Brodhurst, Bernard, Esq., Assistant Surgeon to the Royal Orthopædic Hospital, 14, Brook-street.

Digitized by Google

Childs, G. B., Esq., Surgeon to City Police Force, 11, Finsbury-place South.

Chowne, W., M.D., Physician to the Charing Cross Hospital, 8, Connaught-place West, Hyde-park.

Devenish, S. W., M.B., 7, Billiter-square.

Drury, J. S., M.B., 44, Albion-street, Hyde-park.

Duff, —, M.D., 53, Upper Seymour-street, Portman-square.

Ely, G. E., M.D., Rochester.

Field, C. A., Esq., 4, Stanhope-terrace, Hyde-park.

Forbes, J. Gregory, Esq., Surgeon to the Western General Dispensary, 14, Devonport-street, Hyde-Park.

Gant, Frederick J., Esq., 13, Old Cavendish-street.

Hacon, E. Dennis, Esq., Mare Street, Hackney.

Hale, Robert, J., M.D., Physician to the Western General Dispensary, 117, Westbourne-terrace.

Halley, Alexander, M.D., 14, Queen Anne-street.

Hansard, Richard, Esq., Surgeon to the Radcliffe Infirmary, Oxford.

Hawkins, Charles, Esq., 22, Saville-row.

Kingdon, J. Abernethy, Esq., Surgeon to the City Dispensary, 2, New Bank-buildings.

Lee, Henry, Esq., Assistant Surgeon to King's College Hospital, 13, Dover-street.

Lonsdale, Edward, Esq., Surgeon to the Royal Orthopædic Hospital, 26, Montague-street, Russell-square.

Mackenzie, F. W., M.D., Physician to the Paddington Dispensary for Diseases of Women, &c., 11, Chester-place, Hyde-park-square.

Markham, W. O., M.D., Assistant Physician to St. Mary's Hospital. 33, Clarges-street.

May, George, M.B., 21, George-street, Greenwich.

M'Shane, Charles, Esq., R.N., Greenwich Hospital.

Rook, H. T., M.D., Assistant Surgeon to the Hospital-ship "Dreadnought."

Smith, Tyler, M.D., Physician Accoucheur to St. Mary's Hospital, 7, Upper Grosvenor-street.

Taylor, Robert, M.D., Physician to the St. Pancras Royal General Dispensary, 82, Guildford-street.

Thompson, Theophilus, M.D., F.R.S., Physician to the Hospital for Consumption and Diseases of the Chest at Brompton, 3, Bedford-square.

Todd, R. B., M.D., F.R.S., Physician to King's College Hospital, 26, Brook-street.

Trotter, J. W., Esq., Resident Medical Officer, St. Mary's Hospital.

Walker, J., Butterworth, Esq., 8, Hamilton-place, St. John's-wood.

Welch, H. James, Esq., 1, Dalston-terrace.

Digitized by Google

MEMBERS ELECTED DURING THE SESSION 1852–53.

Barnett, R., Esq., 26, Maddox-street.

Bartlett, William, Esq., Notting-hill.

Beck, T. S., M.D., Physician to the Farringdon Dispensary, 9A, Langham-place.

Burton, J. M., Esq., Lee-park, Blackheath.

Charles, T., Esq., Holborn-bars.

Cormack, J. R., M.D., F.R.S.E., Essex-house, Putney.

Cousins, Edward, Esq., 49, Camden-road-villas.

Hassall, A. H., M.D., Physician to the Royal Free Hospital, 8, Bennett-street.

Hogg, Jabez, Esq., 6, Gower-street.

Humby, Edwin, Esq., Windsor-terrace, Edgware-road.

Hutchinson, J., Esq., Jun., Liverpool-street, City.

Kershaw, N. W., Esq., Kingston-on-Thames.

Leggatt, Alfred, Esq., 13, William-street, Lowndes-square.

Lloyd, E. A., Esq., Assistant Surgeon to St. Bartholomew's Hospital, 14, Bedford-row.

Ludlow, Harvey, Esq., Surgeon to the Metropolitan Free Hospital, 12, Paternoster-row.

Martyn, S., M.D., 27, George-street, Euston-square.

Moseley, George, Esq., Surgeon to the Dispensary, Sandgate.

O'Connor, W., M.D., 26, York-street, Portman-square.

Ogle, James Adely, M.D., Regius Professor of Medicine, Oxford.

Rees, G. A., M.D., 2, Artillery-place, Finsbury.

Richardson, B. W., Esq., Mortlake.

Salter, Henry Hyde, M.D., Demonstrator of Anatomy at King's College, 6, Montague-street, Russell-square.

Sanderson, H. I., Esq., 26, Upper Berkeley-street.

Semple, H., M.D., Torrington-square.

Thompson, H., Esq., Surgeon to the Blenheim-street Dispensary, 16, Wimpole-street.

Tulloc, James, M.D., 1, Pembridge-place, Bayswater.

Wright, E., Esq., Kennington.

Digitized by Google

Digitized by Google

LIST OF SPECIMENS

EXHIBITED AT THE MEETINGS OF THE SOCIETY

DURING THE SESSION 1852-1853.

DISEASES, &c., OF THE NERVOUS SYSTEM.

1. Case of Fracture of the last Dorsal Vertebra, with Destruction of the Spinal Marrow.	Dr. J. W. Ogle.
2. Case of Encephaloid Carcinomatous Growths from the Dura Mater around the Foramen Magnum, reducing the passage for the Spinal Cord to the size of the Little Finger.	Dr. J. W. Ogle.
3. Caries of the Dorsal Vertebræ—Scrofulous Liver.	Mr. J. W. Trotter.
4. Encephaloid Cancer of the Dura Mater, and of the Periosteum of the Spine, Ribs, &c.	Dr. Peacock.
5. Extravasation of Blood into the Substance of the Spinal Cord in two separate places.	Dr. J. W. Ogle.

Digitized by Google

5. Preparation showing Extravasated Blood into the Pons Varolii and Cerebellum.	Dr. J. W. Ogle.
6. Tumor at the Base of the Brain.	Mr. Gay.
Report on this Specimen.	Mr. Toynbee.
7. Ossification of the Cerebral Arteries — Apoplectic Clots in a patient addicted to Onanism.	Dr. Ogier Ward.
8. Small Scrofulous Tumors in the Brain, together with a Kidney and a portion of the Liver from the same Patient.	Dr. Fuller.
9. Specimen of Extravasation of Blood into the substance and upon the surface of the Brain.	Dr. J. W. Ogle.
10. Scrofulous Deposit occupying the Right Optic Thalamus and the Right Crus Cerebri.	Dr. J. W. Ogle.
11. Pus in the Orbit, and Diseased Ear—Fibrin in the Sinuses of the Brain — Softening of the Brain.	Dr. J. W. Ogle.
12. Disease of the Spinal Marrow, consequent on the arrest of a piece of Bone in the Œsophagus, with Ulceration of an Intervertebral Cartilage.	Dr. J. W. Ogle.

Digitized by Google

13.

Apoplexy of the Pons Varolii—Fatty and Earthy Degeneration of the Vessels. — Mr. W. F. Barlow.

14.

Fibrinous Substance, supposed to have been a Deposit detached from the Mitral Valve, obstructing the Middle Cerebral Artery, in a case of Softening of the Brain. — Mr. Shaw.

15.

Congenital Absence of the Middle Portions and Left Hemisphere of the Cerebellum, in a Case of Chronic Hydrocephalus. — Dr. Hyde Salter.

DISEASES, &c., OF THE ORGANS OF RESPIRATION.

1.

Co-existence, in the Lungs, of Cancer and Miliary Tubercle (?) — Dr. Bristowe.

Report on this Specimen. — Dr. Jenner and Dr. Brinton.

2.

Secondary Deposits of Medullary Cancer on the Free Surface of the Pulmonary and Diaphragmatic Pleura of the Left Chest; and Small Cancerous Nodule on or in the Endocardium of the Right Ventricle. — Mr. Hutchinson.

3.

Tuberculous Deposits in Lungs, Spleen, and Kidneys. — Dr. Markham.

Digitized by Google

4.

Tuberculous Infiltration of the Lungs and Spleen, together with Fatty Liver.	Dr. Crisp.

5.

Hydatids from the left Lung, subsequently to the occurrence of Typhoid Fever, complicated with Double Pneumonia.	Dr. Quain, for Dr. Black.

DISEASES, &c., OF THE HEART, AND OF THE OTHER ORGANS OF CIRCULATION.

1.

Pericarditis, probably caused by Circumscribed Abscess of the Periosteum.	Dr. B. Jones.

2.

Enlargement of the Heart, with Earthy Deposit — Adherent Pericardium, and an Opening in it through which the Appendix of the Left Auricle protruded — Enlargement of the Liver — Fatty Degeneration of the Heart and Liver.	Mr. R. R. Robinson.

3.

Enumeration of instances, taken accidentally, of "Fatty condition" of the Heart in various Diseases.	Dr. J. W. Ogle.

4.

Granular and Incipient Fatty Degeneration of the Heart, causing sudden death.	Mr. W. F. Barlow.

5.

Diseased Heart and Kidneys.	Dr. Fuller.

Digitized by Google

6. Fatty Degeneration of the Heart —Death by Chloroform.	Dr. R. Quain.
7. Fatty Degeneration of the Heart —Death by Rupture of the Left Ventricle.	Dr. R. Quain.
8. Fatty Degeneration of the Heart of a Child.	Dr. Ogier Ward.
9. Malformation of the Heart—Complete Closure of the Orifice of the Pulmonary Artery —Very Small Foramen Ovale —Cyanosis.	Dr. Hare.
10. On the Mode of Closure of the Foramen Ovale after Birth.	Dr. Peacock.
11. Case of a Heart with a Single Ventricle, with Observations on the Production of Cyanosis.	Dr. Hale.
Report on this Specimen.	Dr. Peacock.
12. Malformations of the Aortic Valves in an Infant—Sudden Death—Fatty Degeneration (?)	Dr. R. Quain.
13. Diseased Aortic Valves with Fibrinous Deposits.	Mr. Obre.
14. Atheromatous Deposit, and Rupture of one Valve of the Aorta —Congenital Union of two of the Valves.	Dr. Sieveking.

Digitized by Google

15. Malformed Aortic Valves.	Mr. Obre.
16. Diseased Aortic Valves.	Dr. Markham.
17. Three Specimens of Malformation by excess of the Pulmonary Sigmoid Valves.	Dr. Jenner.
18. Diseased Mitral Valve.	Dr. Markham.
19. Contraction of the Mitral Orifice, with Diastolic Murmur.	Mr. J. W. Trotter.
20. Aneurism of the Ascending Aorta.	Mr. Birkett.
21. Aneurism, involving Malformed Aortic Valves and the Commencement of the Aorta.	Dr. Bristowe.
22. Aneurism of the Abdominal Aorta.	Mr. Henry Thompson.
23. Aneurism of the Ascending Aorta bulging considerably into the cavity of the Right Ventricle, and commencement of the Pulmonary Artery, the channel of which it almost entirely blocked up.	Dr. J. W. Ogle.
24. Specimen of Aneurism of the Ascending Aorta communicating with the Pulmonary Artery.	Dr. J. W. Ogle.

Digitized by Google

25. Ossification of the Small Arteries and Capillaries of the Brain.	Dr. Bristowe, for Mr. Rainey.

DISEASES, &c., OF THE ORGANS OF DIGESTION.

1. Epithelial Cancer of the Tongue in a Gouty Subject.	Dr. R. Quain, for Mr. M'Shane, R.N.
2. Ulceration at the Pyloric Orifice of the Stomach.	Dr. Ogier Ward.
3. Perforation of the Stomach.	Dr. John Clarke.
4. Instances of Degeneration of the Mucous Membrane of the Stomach.	Dr. Handfield Jones.
5. Chronic Thickening of the Stomach and Omentum, somewhat resembling Malignant Disease.	Dr. Pollock.
Report on this Specimen.	Dr. R. Quain.
6. Hypertrophy of the Stomach.	Dr. C. J. Hare.
Report on this Specimen.	Dr. Lionel G. Beale.
7. Extensive Ulceration of the Stomach; Malignant (?) — Repeated Hæmatemesis; Anæmia —Chronic Hepatic Peritonitis; Fatty Liver, &c.	Mr. R. R. Robinson.
Report on this Specimen.	Dr. Brinton and Dr. Lionel G. Beale.

Digitized by Google

8. Enormously Dilated Stomach.	Dr. Miller, for Mr. Humby.
9. Perforation of the Stomach—Cicatrized Ulcers.	Dr. Ogier Ward.
10. Poisoning by Bichloride of Mercury.	Mr. J. W. Trotter.
11. A specimen of Intestine in Typhoid Fever.	Dr. Brinton.
12. Instance of Fibrinous Deposit on the Surface of the Intestine in connection with Disease of the Kidney, &c., bearing on the theory of a Fibro-albuminous Diathesis.	Dr. J. W. Ogle.
13. Internal Strangulation, caused by adhesion of the Vermiform Process to the Ovary.	Dr. Risdon Bennett.
14. Intestinal Obstruction—Operation for Artificial Anus.	Mr. Shaw.
15. Rupture of the Jejunum and Laceration of the Mesentery.	Mr. Simon.
16. Ulceration—Stricture—Perforation of Small Intestines.	Dr. Bristowe.
17. Villous Cancer of the Large Intestine.	Mr. Birkett.

Digitized by Google

18. Almost complete Obstruction of the Small Intestine from injury.	Mr. Avery.
19. Deposit of Tubercle in the Peritoneum and Fallopian Tubes.	Dr. Bristowe.
20. Primary Scirrhus of the Peritoneum.	Dr. Bristowe.
21. Calcareous Concretions of the Peritoneum.	Dr. Crisp.
22. Numerous Abscesses in the Liver, associated with Ulceration of the Portal Vein.	Dr. Markham.
23. Hæmatoid Crystals in an Hydatid Cyst of the Liver.	Dr. Bristowe.
24. Tumors of large size in the Liver (Medullary Cancer?) masked by and mistaken for simple Pregnancy.	Mr. R. R. Robinson.
25. Instance of Unorganized Deposit in the Spleen, in connection with Typhus Fever.	Dr. J. W. Ogle.
26. Case of Lobular Hepatitis, terminating in extensive Suppuration.	Dr. R. Quain.
27. Fibrinous Deposits in the Spleen, Thoracic Glands, &c.	Dr. Markham.
Report on this Specimen.	Dr. Bristowe.

Digitized by Google

DISEASES, &c., OF THE URINARY AND GENERATIVE ORGANS.

1. Enchondroma of the Left Testicle.	Mr. Jabez Hogg.
2. Hernia of the Bladder into the Scrotum.	Mr. Pilcher.
3. Specimen of Encephaloid Cancer of the Kidneys.	Mr. Obre.
4. Renal Calculi, the one at the Beginning and the other at the Ending of the Ureters.	Dr. Bence Jones.
5. Cyst in the Kidney, containing Cholesterine Crystals.	Dr. Bence Jones.
6. The Contents of a Cyst in the Kidney.	Dr. Lionel G. Beal
7. Calculus and Cyst in the Kidney.	Mr. Gay.
8. Calculous Abscess in the Pelvis.	Dr. Peacock.
9. Large Cyst connected with the Right Kidney.	Dr. Hare.
10. Peculiar Form of Uric Acid Crystals.	Dr. Handfield Jones.
11. Peculiarly-shaped and Encysted Calculus.	Dr. R. Quain, for Mr. Heath.
12. Large Calculus from a Boy.	Mr. Jabez Hogg.

Digitized by Google

13.
Quasi-organized Fibrin discharged by the Urethra. — Dr. R. Quain.

14.
Case of complete Obstruction of the Urethra. — Mr. Henry Gray.

15.
Excessive Enlargement of the Clitoris. — Mr. Shaw.

16.
Fatty Degeneration of the Uterine Fibres. — Dr. Bristowe.

17.
Uterine Tumors. — Dr. Ramsbotham.
Report on this Specimen. — Dr. R. Quain.

18.
Fibrous Tumors of the Uterus—Uterine Polypi. — Mr. William Adams.

19.
Uterine Polypi. — Dr. Ramsbotham.

20.
Fibro-Cystic Tumor of the Uterus. — Mr. Gray.

21.
Unusually Large Fleshy Mole expelled from the Uterus. — Mr. Hutchinson.

22.
Muscular (so-called Fibrous) Tumors of the Uterus. — Dr. Bristowe.

23.
Encephaloid Cancer of the Uterus, with secondary affection of the neighbouring Lymphatic Glands. — Dr. Bristowe.

24.
Tubarian Pregnancy. — Dr. J. Hall Davis.

Digitized by Google

25.

A Large Ovarian Tumor — A Uterine Polypus. — Dr. Brinton, for Dr. Tanner.

26.

Ovarian Tumor, with Cysts, containing Fat and masses of long Hair. — Dr. Hare.

27.

Fatty Matters discharged from a Tumor situated between the Rectum and Vagina. — Dr. Ramsbotham.

28.

Specimen of Degenerated Placenta. — Dr. Handfield Jones.

29.

Malformations of the Umbilical Cord. — Dr. Crisp.

DISEASES OF THE OSSEOUS SYSTEM.

1.

Chronic Hip-Joint Disease, in which the Head of the Femur was dislocated and separated from the Shaft. — Dr. Bristowe.

2.

Disease of the Ungual Phalanx of the Great Toe. — Mr. Gay.

3.

Disease of the Hip Joint. — Mr. Coulson.

4.

Arthritic Enlargement of the Head of the Thigh Bone and Patella. — Mr. Solly.

5.

Encephaloid Disease of the Femur. — Mr. Mitchell Henry.

Digitized by Google

6.

Dissection of a Dislocation of the First Phalanx of the Thumb, complicated with Fracture of the Metacarpal Bone. — Mr. John Wood.

7.

Section of a Knee Joint affected with Membranous Anchylosis. — Mr. John Wood.

DISEASES OF THE EAR.

1.

Case of Ulceration of the Fibrous Lamina of the Membrana Tympani. — Mr. Toynbee.

2.

Case of complete Bony Anchylosis of the Stapes to the Fenestra Ovalis. — Mr. Toynbee.

3.

A Case of Perforate Membrana Tympani, treated by the substitution of an Artificial Membrane. — Mr. Toynbee.

4.

On the mode of Dissecting the Ear for the purpose of Pathological Investigation. — Mr. Toynbee.

5.

Neuroma of the Auditory Nerve. — Mr. Toynbee.

MISCELLANEOUS SPECIMENS, TUMORS, &c.

1.

Excessive number of White Cells in the Blood. — Dr. R. Quain.

Digitized by Google

2.	
Large Phlebolithes from a Horse.	Mr. Simonds.
3.	
Cysto-Sarcoma of the Mamma.	Mr. Shaw.
4.	
Lobular Hypertrophy and Scirrhus in the same Breast.	Mr. Simon.
Report on this Specimen.	Mr. Fergusson and Mr. Dixon.
5.	
Morbid Growth involving the Walls of the Chest.	Dr. Sieveking.
6.	
Medullary Cancer of the Leg.	Mr. Birkett.
7.	
Two Large Tumors of the Breast.	Dr. Lionel Beale.
8.	
Gelatiniform Cancer of the Breast — Removal — Return of the Disease in the Cicatrix, after five years and a half—Death by Effusion into the Chest.	Mr. R. R. Robinson.

Digitized by Google

REPORT.

Digitized by Google

Digitized by Google

REPORT.

SESSION 1852—53.

I.—DISEASES, &c., OF THE NERVOUS SYSTEM.

1.—*Case of Fracture of the Last Dorsal Vertebra, with Destruction of the Spinal Marrow.*

THE specimen showed extensive comminuted fracture, with displacement; the entire diameter of the medullary canal was occupied by portions of the body of the vertebra, firmly and intimately united together, which were driven back into it. There was of course rupture of the neighbouring ligamentous structures, and an entire "trapping," with destruction of the medulla spinalis opposite to the fracture, by means of the comminuted fragments. The dura mater was entire.

The specimen was from a man who had fallen down a great height and pitched on his back. When removed from the ground, it was found that he had lost all sensation and mobility in the lower limbs. He was brought into the hospital, and it was then ascertained that he had lost all power over the rectum and bladder. Two days after his admission alkaline urine made its appearance, and twelve days afterwards bed-sores came on. These increased, and he died of exhaustion consequent upon them about eight weeks after the accident. The catheter was had recourse to daily, but he never at any time felt its introduction, and never at any time was anything like priapism excited by it or without it. Moreover, it was never possible, by tickling or pricking the skin of the feet or legs, to excite any involuntary or reflex motor actions, indicating the extent of the injury done to the spinal cord, the seat of the excito-motory system. Dr. J. W. OGLE, *15th of February*, 1853.

Digitized by Google

2.—*Case of Encephaloid Carcinomatous Growths from the Dura Mater around the Foramen Magnum, reducing the passage for the Spinal Cord to the size of the Little Finger.*

The patient, a woman aged forty-nine, was admitted into St. George's Hospital under the following conditions:—About eight or nine months previously she had been seized with "a fit," and remained unconscious for some time. It was found that she was paralyzed on the left side. Of this paralysis she gradually recovered to a great extent, but latterly the right side had become similarly affected, and was even worse than the left side. When brought into the hospital she could neither walk, stand, nor feed herself, without help. When in bed, it was found that she could move any of her limbs, &c., although she could not do this at once on being asked; and that no limb fell down lifeless when lifted up. After exciting her will for a little time and waiting, then her muscles would move responsive to her own desires, but not until a short time had elapsed. It was the same with the muscles of the tongue, for her speech was exceedingly slow and deliberate, but each word distinctly and clearly articulated. On trying to drag her legs up in bed she could not pull them up together, but first one and then the other yielded tardily. She had very strange sensations of numbness over the entire body, but there was no want of common sensation,—no want of power to appreciate impressions made on the skin. These symptoms had much the appearance of hysteria at first, as along with them the general health was good, and the functions of life well performed. Cough, with dyspnœa and accumulations of mucus in the bronchial tubes, came on, and on one occasion the evacuations were passed involuntarily. Her power over her muscles became even weaker, but no pain, no paralysis, or anæsthesia, or convulsive action, came on; sleepless nights, involuntary evacuations, and feelings of faintness supervened, and she gradually but quietly sank until she died.

Post mortem examination.—The lungs were generally congested, and the bronchial tubes contained much mucus. The bones of the head were natural. The brain was firm and dry,

Digitized by Google

and its convolutions flattened. The ventricles contained an increased quantity of turbid serum. Attached to the right surface of the falx cerebri and indenting the corresponding portion of brain, was a vascular encephaloid tumour, of the size of a large bean, and a similar tumour was also attached to the dura mater, covering the olivary process of the sphenoid bone, slightly elevating the optic commissure. To the dura mater, also connected with the right and anterior border of the foramen magnum, was attached a large, smooth, rounded encephaloid tumour, of the same character as the others, and of the size of a small walnut, indenting the cerebellum and encroaching much on the foramen magnum, and having hooking round it the seventh and eighth pair of nerves on this side. There was also a small flattened mass of a similar structure attached to the dura mater at the opposite border of the foramen, and these together so far encroached on the opening as to reduce it to a triangularly-shaped space, through which the little finger could only just pass. All these growths were covered by a thin layer of arachnoid membrane. There was, moreover, extreme softening of a portion of the spinal cord in the upper part of the dorsal region; in fact it was quite diffluent.

The history of this case seems to offer one or two important points of interest.

1st. The fact that disease showed itself without exciting cause, in the form of "a fit," sudden loss of consciousness coming on; it being somewhat unusual for tumours, owing to their slowness of growth, to indicate their presence in this manner, without some additional and ostensible cause. It is, however, not uncommon for scrofulous tumours to remain without suspicion, until, by a fall or other injury, or any cause setting up vascular excitement and susceptibility to any irritation in the system generally, the tumour acts as a foreign body and declares itself. Still this was not acknowledged to be the case in our instance.

2nd. The peculiarity in regard to the motor power exhibited: it seemed as if, the power existed fully, but with a weakness in the will to act; or as if from obstruction to conducting fibres, the volition was not properly directed along them. The anterior

Digitized by Google

or sensory portions of the spinal cord would obviously be affected mainly by the tumours at the foramen magnum.

3rd. The supervention of distressing cough, dyspnœa, &c., with other bronchial disturbances, pointing to some interference with the pneumo-gastric nerve; and which, from the relation between the above described tumour and the medulla oblongata, might well be supposed to have existed.

Several cases have existed lately in St. George's Hospital, in which in the course of disease affecting the base of the brain, urgent bronchial symptoms have been excited. Again, it is possible that the disintegrated state of the dorsal portion of the spinal cord may have had its influence in producing the lung affections by depriving correspondent sections of the thorax of due innervation. It is remarkable that no more active symptoms of the diffluent state of the cord existed.

Dr. J. W. Ogle, 1*st of March*, 1853.

3.—*Caries of the Dorsal Vertebræ.—Scrofulous Liver.*

The patient, a boy aged thirteen, from whom this preparation was taken, was admitted for the first time into St. Mary's Hospital, on the 4th of July, under Dr. Alderson's care. He dated his illness four months back, at which time he was apprenticed to a cigar maker. On admission, he appeared to be suffering from mesenteric disease; his abdomen was very tense and tympanitic, and not till the 4th of August could any fair examination of the cavity be made, when, however, there were found distinct clusters of enlarged mesenteric glands. On the 29th of August, he spat up some mucus from his lungs, mixed with blood, and at same time there were râles over the right side. He left the hospital, relieved, on the 12th of September: up to this time he had never complained of pain in the back. He was not seen again till the 22nd of October, 1852, when he again presented himself at the hospital, complaining of a swelling in his right side which had appeared a month previously, and pain in the back, which had caused him to leave off his work two weeks later, having however had it altogether seven weeks. On examination there was found a swelling the size of a small

Digitized by Google

orange, situated over the three lower ribs, and five inches from the spinous processes, of which there was not any displacement; the skin over it was unaffected, and there were distinct indications of its containing fluid; pressure on it, or on the corresponding situation on the opposite side, caused pain. Slight enlargement of some of the cervical glands existed. He had neither cough, nor night-sweats. On the 23rd of October, a valvular opening was made, and some fluid discharged, which was of a seropurulent character. November 7th.—Up to this date, the quantity of discharge had varied greatly, sometimes being very profuse, and at other times scanty. To-day, a diluted injection of tincture of iodine was thrown into the part, which was not followed by any irritation; and this was repeated several times at intervals of a few days. On the 13th, two sinuses which had formed, were laid open. He caught cold on the 23rd, from which time he was more or less annoyed with cough, expectoration, and hectic symptoms, which ultimately proved fatal on the 19th of February, 1853. Once or twice, on probing the wound during his life, it was found to pass upwards and backwards for nearly five inches, and was followed by a copious discharge of pus; at one time the discharge had nearly stopped, and then he expectorated very freely, and sometimes a very large quantity in a very short time. He never complained much of pain in the back, unless pressure or percussion was employed, which was done at one period; and then over this part there was dulness and absence of any respiratory murmur. He never showed the slightest signs of paralysis of the lower extremities, nor were any twitchings observed; urine was always acid, and voided naturally; no impairment of sensation in any part; the bowels,with the exception of one day, when he had slight diarrhœa, were always obstinately costive.

Post-mortem examination.—The body was found greatly emaciated, and there was slight œdema of the feet. On examining the wound with a probe, it was found to pass upwards and backwards for five inches, when it was arrested by exposed bone. The six lower dorsal vertebræ were now removed from behind, and the bodies of these as well as the seventh (at which disease appeared to stop) were found carious on their

Digitized by Google

surface, but quite perfect in form; the articular facets of some of the transverse processes were also carious, and there was hardly a trace of any of the inter-vertebral substance left between these bones. The bodies of these vertebræ had formed the posterior boundary of an abscess, which extended from the first to the last dorsal; the anterior boundary was formed by the roots of the lungs, and part of the lungs themselves, which were separated from the cavity by an adventitious membrane. In the left lung there were not any tubercles; in the right there were tubercles at that portion which was in relation with the cyst, which was separated from it by a more imperfect membrane than at the left side, though on account of the way in which the vertebræ had been removed, no certain evidence of communication between any of the bronchi and cyst could be obtained. Only slight adhesions existed over other parts of the lung. The liver was much enlarged, extended across the abdomen, and weighed 5lbs. 13½ ounces; it was a good specimen of the scrofulous liver, and was universally adherent over its anterior surface. Gall-bladder filled with bile of a deep yellow, which contained slight traces of cholic acid. Spleen, weight 12½ ounces; kidneys mottled. The mesenteric glands small, and externally of an ash-grey colour; on cutting into them, they were found to consist of a cheesy tuberculous-looking matter. The points of interest in this case appear to be the state in which the mesenteric glands were found at time of death, having twelve months before been so large as to be easily detected through the abdominal walls; also the condition of the lungs, no tubercles having been found in either apex, but only in that portion of the right which appeared to be in direct connection with the cyst; the scrofulous liver, enlarged glands in the neck, and the vertebræ, all showing how thoroughly the patient was saturated with scrofula. Then, the condition of the vertebræ, they being so slightly affected, whilst all the inter-vertebral substance of the affected bones was nearly entirely destroyed; with, during his whole illness, the absence of any sign of injury or affection of the spinal cord; the means of diagnosis being the state of his health, the situation of the swelling, and the pain produced there on percussion. Mr. J. W. Trotter, 1*st of March*, 1853.

Digitized by Google

4.—*Encephaloid Cancer of the Dura Mater, and of the Periosteum of the Spine, Ribs, &c.*

The subject of this case was a girl, sixteen years of age, who, being delicate from early life, had till ten years of age been subject to convulsive attacks. After that period she grew strong, and continued well till towards the autumn of 1851, when she fell down stairs and bruised her back and thigh. She did not suffer materially after this accident, but occasionally complained of soreness in the back. At Christmas, 1851, she had a fit, but was apparently quite well after it till February, 1852, when she was seized with feverish symptoms, attended with pains in the limbs. This attack was stated by her medical attendant, at the time, to be rheumatic fever; but she had not any redness nor swelling of the joints. At this time she began to complain of pain in the middle of the abdomen, extending thence to the spine of the back; and this pain never after entirely left her. The feverish symptoms continued for six or seven weeks and then abated; but recurred, at intervals, till November, when she had a succession of convulsive attacks, and was insensible in the intervals. The fits continued for about ten days. During this time it was observed that she had lost the use of her lower extremities, and they were ever after entirely deprived of the power of motion and of sensation. She passed her evacuations unconsciously, the fæces being at first retained. On the 8th of December she was sent to Guy's Hospital, and continued there till her admission into St. Thomas's. While in that institution she had another fit, and was entirely blind after it, and the left eye was much everted. The power of vision returned at the end of a few days in the right eye, and less rapidly in the left. Bed-sores had began to form on the back and hips before she was removed from home, and these afterwards enlarged. When admitted into St. Thomas's Hospital on the 8th of March, she was very much emaciated and entirely paraplegic, all power of motion and sensation being entirely lost in the lower extremities. Her intelligence did not appear at all impaired. Both pupils were very much dilated, and the left eye was everted; vision

Digitized by Google

was extremely imperfect with the left eye, but she saw tolerably well with the right. The sacrum and hips, and indeed, all parts of the back and lower extremities, exposed to pressure, were more or less ulcerated. She suffered from profuse diarrhœa, and passed both the stools and urine unconsciously. There was no material deficiency of resonance on percussion in any part of the chest, and the respiratory sounds were natural except at the right apex, where there was slight bronchial breathing. She died at half-past-two o'clock on the morning of the 17th of March, and was quite sensible up to twelve o'clock that night.

Autopsy.—The body was extremely emaciated; the lower extremities, especially the left, were œdematous. The greater part of the sacrum and both greater trochanters were laid bare, apparently by bed-sores; both thighs and legs presented sinuses communicating with diseased bone, and one of considerable size was situated on the left heel.

Head.—The dura mater was adherent to the calvaria in circular patches from the size of a sixpence to that of half-a-crown; on removing it the attached surface was seen to be rough, and thickened by a yellowish-white, slightly translucent, pulpy substance, portions of which were left adhering to the corresponding and slightly eroded osseous surface. Opposite each of these patches, the free surface of the dura mater presented a hemispherical tumor, varying in size from that of a split pea to that of half a small marble; their surface was smooth and polished, and they appeared to have been developed in the substance of the dura mater, as no distinct layer of it could be traced either over, under, or through them; their tendency seemed to be to extend vertically when unopposed by pressure, as on the free surface of the dura mater, but laterally when resisted in that direction, as on the attached surface. There were about a dozen or eighteen of the tumors, several being situated in the vault, but most in the base, of the skull; opposite the larger ones the brain was distinctly depressed. A growth of the same kind enveloped the pituitary body. Springing from the cribriform plate of the œthmoid bone, or rather from the dura mater immediately over it, was an irregular tumor

Digitized by Google

nearly as large as a pigeon's egg; it consisted of two lobes, a right and left, very little, if at all, connected with one another. The left, about as large as a small chestnut, sprang from the dura mater covering the left half of the cribriform plate and partly from the falx major; the right, twice or thrice as large, had a similar attachment on the right side. The under part of the anterior lobes of the brain was much hollowed-out to receive them, and the brain-substance in contact with them was somewhat softened, reddened, and in places adherent to them. The anterior part of the olfactory nerves appeared to be destroyed. This tumour was essentially similar in character to the smaller ones, consisting like them of a yellowish-white, slightly translucent, pulpy, creamy juice-yielding material; but its central and upper parts were infiltrated with blood. There appeared to be a more than normal amount of fluid in the subarachnoid tissue. The brain was exceedingly pale, and moderately firm throughout. It contained no tumors in its substance.

Chest.—Pericardium and heart healthy; both pleuræ presented a few old adhesions; in the apex of the right lung were two or three minute cavities, several small masses of yellow cheesy material, and a few grey miliary deposits, which had the appearance of tubercle. There was no abnormal deposit in any other part of this lung, and none whatever in the left; both were pale and highly œdematous throughout. The bronchial tubes were loaded with thin frothy mucus, and their lining membrane was pallid.

Abdomen.—The peritoneal cavity contained nearly a pint of thin, slightly milky fluid; the liver was large, pale, and fatty; the spleen was of natural size, pale, of moderate consistence, and thickly studded with minute whitish spots (malpighian corpuscles); pancreas, stomach, and intestines healthy; right kidney healthy; the left kidney was much increased in size; its capsule was not more adherent than natural; its surface was for the most part smooth, but presented occasional elevated spots and patches of a dull white colour; the spots varied from points barely visible to the eye, to a line in diameter; the patches were formed by the confluence of these, and had therefore a somewhat spotted

Digitized by Google

appearance; were irregular in shape, and ran more or less into one another. The diseased surface was much less abundant than the healthy, and perhaps occupied one-fourth of that of the entire kidney. On section, the cortex appeared about natural in thickness, and the abnormal deposit was seen to extend vertically though irregularly into it, and in some parts to encroach on the bases of the cones; the medullary portion seemed healthy; the pelvis, infundibula, and calyces, were considerably dilated.

At the back of the abdominal cavity, opposite and adherent to the third lumbar vertebra, and partly to the second and fourth, was a somewhat lobulated tumor, apparently as large as a small orange. It was firmly connected with the spinal column, the front and sides of which it embraced as far back as the roots of the transverse processes; it was divided by the aorta and vena cava into two lobes, of which the left was considerably the larger; on each side it was covered by the psoas muscles, and the left ureter was considerably displaced by it; the second and third lumbar nerves on each side passed through its substance; on its anterior surface were several enlarged and blackened lymphatic glands. On section it was found to be soft and pulpy, somewhat lobulated, and yielding copious cream-like juice; it presented also several circumscribed patches of a firmer and almost cheesy character; it appeared to grow from the periosteum, the bone below being scarcely, if at all, affected. The fibres of the anterior common ligament could be traced through its substance, dividing it more or less completely into a superficial and a deep portion. On examining the spinal canal, the tumor was found to grow in the same manner from the posterior part of the bodies of the vertebræ, and to occupy fully one half of the calibre of the canal; the theca vertebralis being quite unaffected. The cauda equina must clearly have been compressed, though there was no apparent alteration in its structure; the pressure exerted on each third lumbar nerve in its passage through its intervertebral foramen was very decided. No alteration whatever either in the walls or contents of the aorta, vena cava, or ureter, could be detected in those parts of them lying on the tumor; though from the fact of the lower extremities being œdematous, and from the

Digitized by Google

kidney being in a state of commencing hydro-nephrosis, it is clear that the passage of fluid along them was somewhat interfered with.

From the periosteum of the anterior surface of the left twelfth rib grew a small, flat tumour, having precisely the same characteristics as those before mentioned. It had the size and shape of a nux-vomica seed. The uterus, fallopian tubes, &c., were healthy.

Microscopic Examination.—"The juice from the tumors of the dura mater consisted entirely of nuclei; that is, of round or oval bodies, for the most part equal in size to a blood-corpuscle, with a well-marked and even outline, and one, two, or three minute nucleoli. Their substance was formed almost wholly of these nuclei, and a delicate, scarcely-perceptible, fibrous reticulum. The tumor attached to the spine presented similar elements, the nuclei, however, were, for the most part, larger, about the size of a white corpuscle. The nuclei in the growth springing from the rib equalled those just mentioned in bulk, but differed from them in shape; they were for the most part elliptical, the long diameter being three, four, five, or six times that of the short. The firmer portions of the lumbar growth presented nuclei of the same size as those found in the rest of the tumor, but they were more granular, more opaque in mass, and mixed with a considerable quantity of free granular matter. The cheese-like deposit in the lung consisted of nuclear bodies about as large as those found in the spinal tumour, but agreeing equally in size with the nuclei of the cells of the bronchial mucus. They differed from both, however, in being more granular, less regular in shape, and less defined in outline; they were also mixed with abundance of granular matter and nucleus-like bodies of smaller and varying size. In the grey miliary deposit, the cells were more perfect and the granular matter less, but even here there was, for the most part, a tolerably well marked distinction between the even and sharp outline of the nuclei of even the most imperfect portions of the lumbar tumor, and the irregular and confused margin of those of the miliary deposit. The portions of kidney that appeared healthy to the eye, appeared also normal

Digitized by Google

under the microscope. The parts in which the white deposit was situated seemed infiltrated with nuclei very much resembling those of the spinal tumor, and, at the same time, not very unlike pus-cells, but they were not similarly affected by acetic acid. It was difficult to determine what tissue was the seat of this deposit. I believe, however, that the whole structure of the diseased portions was infiltrated, and that it occupied both the tubes and inter-tubular spaces.

"There can be little doubt, I think, that the tumors growing from the dura mater and from the periosteum of the spine and rib were identical in their nature and truly cancerous. They resembled one another in being soft and white, in yielding a cream-like juice, and in being built up of nuclei. The differences were slight, and due simply either to extravasation of blood or degeneration, and to unimportant varieties in the size and shape of their nuclear elements. But in all, even in their variable characters, the tumours had an exact resemblance to encephaloid cancer. This appears, then, to have been a case well illustrating that peculiar tendency often observed in cancer, of confining itself, even in its secondary manifestations, to one particular tissue, instead of following the ordinary course of the circulation, and making its appearance in the lungs or liver. Thus we find cancer at one time confining its ravages to the lymphatic system; at another, to the serous membranes; at a third, to the tegumentary structure, and so on. In this case, the tissue primarily and chiefly affected was the periosteum, the periosteum of the skull, and that of the spine and rib. Not improbably also the sinuses in the lower extremities were connected with similar affection of periosteum. The sloughy sores on the hips and sacrum, however, seemed to be true bed-sores.

"There may be some question as to the nature of the deposit in the lungs. It had all the ordinary characters of tubercle, and in microscopic structure it had an equal resemblance; still I cannot say that it was very unlike the degenerated parts of the cancerous lumbar tumour. My own belief is, that it was true tubercle. The character of the disease in the left kidney is another somewhat doubtful point. A slight degree of hydro-

Digitized by Google

nephrosis had taken place, apparently from obstruction to the flow of urine caused by pressure of the lumbar tumor on the ureter; and in such a state of affairs the supervention of inflammation does not seem unnatural. The difficulty is, as to whether the deposit was simply inflammatory, or whether it was specific and malignant. I believe the latter to have been the case."—Dr. Bristowe.

Dr. Peacock, 19*th of April*, 1853.

5.—*Extravasation of Blood into the Substance of the Spinal Cord in two separate places.*

The specimen exhibited consisted of a portion of the spinal cord, including the part opposite the tenth dorsal vertebra, into which blood had been extravasated, occupying as well the grey as the white portions of the posterior segments. There was also found extravasated blood in the substance of the medulla oblongata, occupying the central part of the left side of the medulla, about an inch below the margin of the pons Varolii. The whole of the cord was somewhat diminished in consistency, but not very manifestly so. No unusual appearances were observed in the cord when examined with the microscope, but the larger subdivisions of the vertebral arteries contained atheromatous deposits in their parietes.

The cranium and its contents were quite healthy.

There was found engorgement of the lungs and of the bronchial membrane, and considerable bloody fluid in the pleural and pericardial sacs. The heart was healthy, weighing nine ounces.

The intestinal tract was congested as to the mucous membrane. The kidneys were very large, weighing 18½ ounces, and were full of blood. Their capsules were easily displaced. In the cortical parts a few very small cysts existed, and several deposits of a yellowish colour, in some cases, appeared on the surface of the gland. These were found to consist of amorphous and granular matter, in which but few gland-tubes existed, and they were full of the same granular matter, with but few epithelial nuclei. The pelves of the kidneys, as well as the

Digitized by Google

mucous membrane of the ureters, were very vascular. The mucous membrane of the bladder was of a dark greenish-brown colour, being in some places quite ulcerated, and in others coated by a layer of yellowish soft fibrin. The blood in the body was very fluid.

The patient, a man aged thirty-nine years, had suffered from supposed rheumatic pains for one or two months, when he suddenly found that he had some difficulty in passing his urine; the next morning he was unable to walk to his medical man. The difficulty in voiding his urine, and the loss of power in the legs, gradually increased, until about ten days after the beginning of these symptoms, at which time he was brought into St. George's Hospital. He was then quite unable to move either leg, but in one leg only was sensation lost. No pain existed, and the upper extremities were unaffected. The urine, which was highly ammoniacal and contained pus, was drawn away by catheter regularly twice a-day. Three days after admission the loss of sensation had become more complete and had extended as high as the loins. Subsequently, pain at the stomach was experienced, and his respirations became long and sighing. The general health gradually failed, the respiration becoming more difficult, but the mental faculties remained entire, and the upper extremities remained unaffected. There was at no time, notwithstanding the tardy respiration, &c., any lividity or suffusion of the face. He died ten days after his admission into the hospital.

Though a diseased condition of the very small nourishing vessels of the spinal marrow was, microscopically, not observed, yet it doubtless did exist, as well from the fact of the larger vessels being atheromatous, as from what we know of extravasations within the cranium. How this diseased state of the vessels arose, is another consideration. Extravasation having occurred into the lower part of the dorsal region of the cord, it is very easy to perceive how the loss of sensation and motility followed. The interference with the respiratory functions, associated with the morbid state of the lungs and air-passages, and probably, also, the uneasy sensations referred to the stomach, were dependent on the extravasation into the medulla

Digitized by Google

oblongata, with which the pneumogastric nerve is so intimately connected.

The question arises as to the position which the pathological state of the kidneys should hold in considering the progress and sequence of morbid actions set up. The diseased condition of the bladder, then of the ureters and pelves of the kidneys, is obviously traced to the paralysis of the bladder; and it is possible that the kidneys may have been greatly injured by the same cause; yet, at the same time, it is more than probable that the affection of the kidneys was coincident with that of the blood-vessels, having a common origin.

Dr. J. W. Ogle, *3rd of May.*

5.—*Preparation showing Extravasated Blood into the Pons Varolii and Cerebellum.*

The specimen was taken from a man aged sixty-five years, whose previous history was unknown. He was taken in "a fit" early in the morning, whilst at work, and lay insensible for some hours, his fellow-workmen thinking him to be drunk. He was brought into the hospital about the middle of the same day, in the following state:—He was insensible, with pupils contracted, and powerless as to the left hand and arm. There was stertor, but no convulsive action. His pulse was full and bounding, and rapid. He was bled, and had calomel given to him and enemata. He died the same night.

Post-mortem examination.—There was found extravasated blood under the arachnoid, at surface of right cerebral hemisphere; also at the base of the brain generally, under the arachnoid. Blood was also found to be extravasated into the substance of the right portion of the pons Varolii, and slightly into the contiguous part of the cerebellum. The ventricles were distended with bloody fluid. On minute examination, as was seen also by Dr. Sieveking, and Mr. Barlow of the Westminster Hospital, the larger vessels of the brain were atheromatous, and the smaller ones contained fatty and calcareous matters attached to their walls in abundance.

Digitized by Google

There was a thickened state of the parietes of the left ventricle of the heart, and a generally fatty condition of the muscular fibres. The kidneys were also fatty.

Dr. J. W. Ogle, 21*st of December*, 1852.

6.—*Tumor at the Base of the Brain.*

Mr. Gay presented this specimen for Dr. G. A. Rees, who gave the following history:—

The lad, aged seven, was healthy to the age of seven and a-half; when he began to decline, with loss of appetite, restlessness, and frequent desire to evacuate. It was observed by his mother that his left arm was frequently drawn backwards, and fixed in that posture. In the summer of 1852, a change of air proved serviceable to him, and he began to recover his lost flesh. In the September of that year, however, he was attacked with diarrhœa, began to complain of slight headache, again became restless and very talkative, stuttering as he spoke. His gait became unsteady, his character more childish, and his features assumed a constant expression of laughter.

His appetite became voracious, although at the same time he began to vomit the contents of his stomach after each meal. Dr. Rees saw him in October. He was then pale and emaciated; extremely restless and talkative, without delirium: there was slight strabismus, with total loss of sight in the right eye. He was desirous of constantly moving about, which he did with a rolling, tottering gait; constantly talking of surrounding objects; whilst his face continued to assume an expression of unmeaning laughter. His tongue was clean; bowels torpid; and he had a frequent desire to pass his urine. Pulse 96, and regular.

After this interview, Dr. Rees did not see him again alive; but heard that his symptoms became rapidly worse. He began to scream violently; his sickness became more constant; blindness extended itself to both eyes; and he became drowsy, and then comatose. His bowels were obstinately confined,

Digitized by Google

and his bladder impatient of the smallest quantity of water. Having had periodic rigors and profuse perspirations, he at length died of extreme exhaustion on the 27th of December.

Post mortem.—The body was extremely emaciated.

The dura mater was found slightly adherent to the skull; membranes healthy; no fluid in the ventricles; on removing the brain, a tumor was found occupying the space between the middle and anterior cerebral lobes. It was pear-shaped, about 3 inches in length, and 1¼ inches at its greatest diameter. The small extremity lay within about three lines of the pons Varolii, between the crura cerebri and the middle lobes of the brain; whilst the front and largest portion lay beneath, and, indeed, was partially imbedded in the right anterior lobe; the portion of the lobe forming its bed having lost its grey matter, apparently by absorption consequent on pressure. The right optic nerve could not be found; and it is to be regretted that the post-mortem changes had so altered the consistence and structure of the thalamus opticus and adjoining portion of brain before it was examined, that the precise condition of these parts could not be made out. The left optic nerve was adherent to the side of the tumour, and considerably diverted from its normal course. The posterior extremity appeared to lie on the third ventricle, the floor of that cavity having been removed, whilst the opposite portion of the tumour was adherent to the contiguous brain-surface by some slight cellular tissue. The thoracic viscera were healthy, with the exception of the lower lobe of the left lung, which was solid, but had no tuberculous deposit. The mesenteric glands were enlarged, but these also had no tubercle in their substance.

Mr. Gay remarked on the interest attached to the case, especially on account of the symptoms, which, with tolerable accuracy, might be assumed to mark the rise and progress of this tumor; which would appear to have commenced near the right crura cerebri, from the rigidity of the arm which was observed at the outset of the disorder; and as it extended itself forwards and in line, so it involved the optic nerve, the third pair, the right olfactory (which was also gone), and the grey matter of the right anterior lobe, as was marked

Digitized by Google

by the concurrent loss of vision, the strabismus, and the subsequently impaired state of intellect.

Mr. Gay, *4th of January*, 1853.

Report on the Preceding Case.—The tumor was pear-shaped, and measured 4 inches in length, 1½ inch in diameter at its larger extremity, and 1 inch at the smaller. Upon being gently pressed by the finger, it had the feel of being semi-fluid, except at its larger extremity, where it was somewhat more solid. Upon making a section, it was observed to consist of:—1, a dense capsule; 2, a matter about as firm as the healthy recent pons Varolii, and having somewhat its colour and consistence; 3, a pulpy matter having a dark grey colour, and containing a large number of blood-vessels, distended by dark-coloured blood. The white matter formed a mass about the size of a walnut at the larger end of the tumor, and a small portion about half its size occupied the smaller end. Upon microscopic examination, the capsule was found to consist of dense fibres; some placed side by side, others crossing them at various angles.

The harder portions were almost wholly composed of extremely delicate fibres, among which a few nucleated cells were interspersed. (See Plate I, fig. 1, *a*.) The softer gelatinous substance consisted of granulated cells, nucleated cells, and some delicate fibres of the same size and structure as those seen in the harder portion. Many of the nucleated cells had fibres prolonged from them. Some of them had a fibre attached to each extremity. In many instances the cell appeared to be so much elongated that it had had the aspect of a fibre with granules in its substance. (See Plate I, fig. 1, *b* & *c*.)

The tumor had the general appearance and character of encephaloid growths; the granular cells and fibres being more abundant than in ordinary specimens.

Mr. Toynbee, 18*th of January*, 1853.

Digitized by Google

7.—Ossification of the Cerebral Arteries. Apoplectic Clots in a patient addicted to Onanism.

A. B., aged thirty-eight, married, with eight children, all girls, the youngest aged two years, all weakly; has practised onanism since his seventh year. He had an attack of paralysis four years ago, after a week of great excitement, which affected the right side. During the attack the sight was double, and the right eye was everted. From this attack he recovered pretty well, when, exactly a year after, he had a second on the same side, which still more disabled him in mind as well as in body. Some months afterwards he had a third seizure, attended with great faintness; but this soon passed off, and he regained his former condition, being able to walk and converse, but not freely, and never starting a conversation. Seven weeks before his death he had a fourth attack, more severe than the preceding ones, though he was able to walk home from church when it occurred. The symptoms were great faintness at first, succeeded by reaction in a few hours; the pulse becoming fuller and more rapid; mouth drawn to the left side, and tongue protruded to the right: eyes alike; right arm and leg much weaker than left, but not paralysed; speech low and indistinct; intelligence perfect; some drivelling from the mouth, and choking on swallowing a gulp of fluid. In a few days he recovered sufficiently to walk about his room and sit up for an hour or two, but he then began to grow more feeble, and lost flesh rapidly, the pulse being between 90 and 100, and the tongue always brown. On January the 2nd, he had a convulsion, chiefly affecting the right side, and from this time he never quitted his bed—his head hot, the arteries and veins of the scalp distended, and the pulse varying from 78 to 100. A few days before his death he had a slighter convulsive attack, and died on the 14th, after a protracted agony. After these attacks of convulsion he never remained still for a minute while awake, the left side being almost continually in motion, with occasional spasms of both right and left limbs. For several years he had complained of oppression at the back of the neck; and he had hypertrophy of the heart, but no valvular

Digitized by Google

disease. At one period the depression of spirits (the consequence of his habits) nearly induced suicide. Previous to the first attack, his intellect was above the standard, though he never was a person of strong will; and latterly his head seemed to grow higher in the opinion of his intimate friends.

Post-mortem examination, eighty hours after death.—Scalp very thick and firmly adherent. Skull of variable thickness. Dura mater rather thickened. Pia mater and sinuses not much congested. Arachnoid at base of brain formed a strong but transparent membrane. Right carotid larger than left; both ossified. Right vertebral artery also was dilated more than left, and both were ossified, as also were all the larger arterial trunks; corpus callosum, fornix, and optic thalami much softened. Left crus cerebri contained an empty cyst, and close to it, on the outer side, a recent coagulum; and in the left corpus striatum was an old clot the size of a hazel nut, of a deep brown, the surrounding tissue being also stained brown; and towards the internal side of the left corpus striatum was a fourth recent coagulum, the size of a small pea. In the centre of the right corpus striatum was a discoloured spot like that on the left side, and a small cavity the size of a split pea. The discoloured brown spot seemed to be the stain left by the removal by absorption of a former clot. The substance of the brain was firm, but studded with more red points than usual. The cerebellum was quite healthy.

The interest of this case is increased by the fact that the brother of the patient, also a victim to the same vice, is lying in a state of imbecility. The eldest girl at fourteen had a paralytic attack when six years old, from scarlatina maligna; the second, at twelve, has spinal disease; the youngest, at two, can neither speak nor walk. Several have their father's habits, and all are unhealthy.

Dr. Ogier Ward, 18*th of January*, 1853.

8.—*Small Scrofulous Tumors in the Brain, together with a Kidney and a portion of the Liver from the same Patient.*

These specimens were taken from a woman aged forty-one, who was admitted into St. George's Hospital on the 2nd of Feb-

Digitized by Google

ruary, 1853. She was a thin, delicate looking woman, and for many months had been subjected to much privation. Her chief symptoms on admission were pain in the hepatic region, of two weeks' duration, with slight jaundice, extreme restlessness, constant nausea, and debility. The urine was albuminous, and the stethoscope revealed the existence of tubercles (not softened) in the lungs. Two days after her admission she had two or three fits of an epileptic character, which left her almost unconscious, and partially paralysed on the right side. On the following day the fits recurred, and continued to recur at short intervals until the time of her death, which took place on the 9th instant. During the last three days of her life, she lay in a state of coma interrupted only by the fits.

The body generally was emaciated. The lungs, more especially the left, contained some masses of greyish-black tubercles, one portion of which, about the size of a pea, in the left lung, had begun to soften. The heart was flabby, soft, and under the microscope, somewhat fatty; its valves healthy. There was a large accumulation of fat, about an inch thick, on the interior wall of the abdomen: the liver was of enormous size, extending down to the right iliac region; of a pale yellowish-white appearance; and under the microscope the hepatic cells were seen gorged with fat; the kidneys were granular on their surface, their cortical structure was shrunken, and their pelves filled by large masses of fat. The membranes of the brain were healthy: the brain itself somewhat paler than natural and extremely wet, a quantity of fluid escaping at each incision; the ventricles contained a small quantity of fluid. In the posterior lobe of the left hemisphere were two small scrofulous tubercles, one situated on the surface, the other about the centre of the lobe. The substance of the brain around these tumors was not softened, nor was there any evidence of their having given rise to any local symptoms.

The points of interest connected with the case are:—

1st. The curious accumulations of fat—the fatty masses, which existed in the pelves of the kidneys, and on the interior walls of the abdomen, coincidently with considerable emaciation of the extremities.

Digitized by Google

2nd. The consideration as to what was the efficient cause of death. The existence of the tubercles in the left hemisphere of the brain, when viewed conjointly with the hemiplegia of the left side, might lead to the supposition that the "head-symptoms" were referable to the presence of these tubercles; but the total absence of softening round the tubercles, and the state of utter inactivity in which they were found, coupled with the wet condition of the brain and the disorganised state of the kidneys and other excretory organs, induced Dr. Fuller to regard a state of toxæmia resulting from the defective action of the diseased excretory organs as the true cause of the epilepsy, coma, and death. Dr. FULLER, 15*th of February*, 1853.

9.—*Specimen of Extravasation of Blood into the substance and upon the surface of the Brain.*

The brain was taken from a man aged sixty-nine years, who had been the subject of two previous attacks of apoplexy. He went from home one morning to his work at about seven o'clock, and was found in the streets by a policeman at nine o'clock, quite insensible. He was removed to the police station, and had emetics given to him, under the idea that he was intoxicated. Not being relieved, he was brought to St. George's Hospital at about twelve o'clock, and it was found that he was quite insensible, and collapsed. He was making, as the nurse said, "a very curious noise in the throat," and had his eyes closed. There was no appearance of convulsive action in any part of the body. He had turpentine injections; mustard poultices also were resorted to, which caused him to move his legs and the left arm, but the right arm was never moved, and until his death remained perfectly contracted and rigid. Subsequently a blister was applied to the nape of the neck, and croton oil given to him. His bowels were freely opened, but he continued in the same comatose state until he died, twenty-nine hours after his admission into St. George's Hospital.

Post-mortem examination.—The dura mater was firmly adherent to the calvaria in various places. Under the arachnoid

Digitized by Google

membrane, covering the upper and outer side of the right cerebral hemisphere, was a thin coat of extravasated blood. This was also the case over the entire cerebellum, and at the base of the brain. On section, the brain was found to be of diminished consistence, but the corpus cavernosum, the fornix, and all the structures bounding the lateral ventricles, were exceedingly softened; moreover, the ventricles were full of fluid and weakly coagulated blood, and had their septum destroyed. The blood had obviously poured forth from the corpus striatum and optic thalamus, which, along with the outer wall of the left ventricle, were considerably broken down into a defluent shreddy substance. Many of the blood-vessels examined, especially those from the pia mater, had quantities of fatty matter adherent to them; and in many cases also a number of red and reddish-brown coloured bodies, of various sizes and forms, having the appearance of being calcareous. There was a slightly fatty condition of the heart's fibres and of the kidneys, as seen by the microscope; also an atheromatous state of the coronary vessels of the heart and of the abdominal aorta.

Dr. J. W. Ogle, *15th of February*, 1853.

10.—*Scrofulous Deposit occupying the Right Optic Thalamus and the Right Crus Cerebri.*

A girl of the age of twenty-two years was admitted, more than once, into St. George's Hospital, with abscess at the upper part of the right arm. This was supposed to be connected with scrofulous disease of the shoulder joint. On one occasion, shortly after admission, she was affected by intense headaches and loss of consciousness, which continued for some time, and subsequently she had other similar attacks of but short duration. She also had strabismus; the face was drawn to the right side; and there was inability to retain the evacuations. By means of nourishing food and stimulants the patient recovered so far as to leave the hospital with only occasional headache and a vacant expression of countenance.

Digitized by Google

When readmitted into St. George's Hospital the face was much drawn to the right side, and there was perfect ptosis of the left eyelid. She was in a semi-comatose state, but when spoken to could answer rationally, though in an unusual tone. The evacuations were passed involuntarily. There was also constant moaning, but no pain was complained of, and only a sensation of "pricking" in both arms. The abscess before spoken of was still discharging. The patient remained for eighteen days in this state, but up to the day of her death she recognised those around her, when roused. She gradually sank, and died without any convulsive action or paralysis having come on.

Post-mortem examination.—The body was in good condition. Extensive caries of the bony elements of the right shoulder-joint was found, and slight scrofulous deposit existed in the apices of both lungs; but beyond this, no general indications of tuberculosis were discovered. There was evidence of considerable bronchitis having occurred, and posteriorly the lungs were very lacerable and engorged. The heart was healthy. The abdominal viscera—excepting the kidneys, which were unusually large and firm, and contained several small cysts—were healthy. The bones of the cranium were healthy; much sub-arachnoidean fluid existed; and on section the brain proved to be "wet," and to contain many congested vessels. The right optic thalamus was occupied by a large mass of scrofulous deposit, which gave this ganglion the appearance of being twice as large as it should be, and consequently occupied all the body of the right ventricle. Its surface was quite smooth and even. On examination, it was found to pass down into the third venticle, and so far to press downwards as to protrude the floor of this ventricle, pushing to the left the optic commissure and the corpora albicantia, displacing them considerably. Moreover the right crus cerebri seemed entirely involved in the malignant mass.

We may remark in this case the freedom from hemiplegic paralysis, which seems generally to result from injury or disease of either optic thalamus, and also the "pricking sensations" experienced in the upper extremities, as connected with the

Digitized by Google

acknowledged office which the thalamus bears, as one of the centres or foci of sensation.

Dr. J. W. Ogle, 1*st of March*, 1853.

11.—*Pus in the Orbit, and diseased Ear. Fibrin in the Sinuses of the Brain. Softening of the Brain.*

The patient, a woman, aged twenty-two, was married and had one child. She had been into some hospital for a chest disease, and on one occasion had attempted to commit suicide by taking poison; stating at the same time that her husband had given it to her. Subsequently, she made overtures to another man, who being ignorant of her true position, married her, about four months before her death. The reservation on this subject of course depressed the patient greatly, and she only confessed her conduct a few days before death. It is uncertain how it was before her second marriage, but since that time she was the subject of very severe epileptic fits. At one time she vowed she would murder her second husband.

About three weeks before her death she was attacked by persistent retching and vomiting, and excessive discharge from the left ear, though she had often complained of pain in the ear and headache since her marriage. Delirium came on, and she was brought into St. George's Hospital. At that time the face was much flushed, and there was considerable swelling on the left side of the neck and face. The left eyeball was exceedingly protruded, and there was ptosis of the left eyelid. The eye could be slightly moved in all directions, but was permanently drawn inwards. The conjunctiva was vascular, and all the external part of the eye wrinkled and œdematous. The eyelids were red and œdematous. The left pupil was dilated to a slight extent, but answered well to the stimulus of light. The right eyelid was natural, and the movements of the ball natural; the pupil was greatly dilated, and only slightly responded to its stimulus. The patient asserted that she could see the best with the *left* eye. There was total deafness on the left side, and a very offensive discharge from the left ear. There was great difficulty in opening the mouth, and in swal-

Digitized by Google

lowing, as well as occasional hiccoughing and slight cough, which was without expectoration. On forcible closure of the mouth the left side appeared to be the weakest. The pulse was regular, and 150 in a minute, the respiration being 68. The tongue and lips were very dry and baked. Excepting that the cardiac sounds were heard over a rather large extent, there was nothing observable on auscultation as to the thoracic viscera.

During the night the patient became very delirious, and much difficulty of swallowing came on. Coma preceded death, which took place but a few hours after admission into the hospital.

Post-mortem examination.—The dura mater was found to be much adherent to the bone over the summit of the left cerebral hemisphere, and the sub-arachnoid tissue generally contained much bloody fluid. The tentornium cerebelli on the left side was firmly adherent to the upper portion of the cerebellum, and at the base of the brain the dura mater was covered by a layer of soft yellow fibrin. On section, the substance of the brain was found to contain great numbers of bloody puncta; and on the right cerebral hemisphere, a little above the level of the corpus callosum, and about an inch from the external surface, was an oval patch of softened tissue, of a pinkish colour. The ventricles contained much limpid fluid. The lateral, as well as both parietal sinuses, and the cavernous veins on the left side, contained much particoloured fibrin, which was in places very firmly adherent to their parietes. Moreover, the ophthalmic vein on the left side contained fibrin adherent to its walls; and within the orbit, and pushing forwards the eyeballs, was a quantity of purulent fluid. There was considerable disease of the tympanum, with destruction of the membrane, on the left side, but the internal ear was unaffected.

There was recent fibrin in the pleural sacs, and in one or two isolated places the lungs were hepatized. The heart was natural; the kidneys were fatty, but the other abdominal organs presented nothing worthy of note.

Dr. J. W. Ogle, *5th of April*, 1853.

Digitized by Google

12.—*Disease of the Spinal Marrow, consequent on the arrest of a piece of Bone in the Œsophagus, with Ulceration of an Intervertebral Cartilage.*

The patient, a man, aged fifty, got a large portion of a mutton-bone impacted in the œsophagus. This was spontaneously disgorged a short time afterwards, but its removal was followed by much cough, and the evacuation of a quantity of purulent matter. When first treated, he was suffering from severe febrile symptoms, also dysphagia, and great pain at the back of the neck, which was much increased on motion. Purgatives and tartar emetic were given to him. The evacuation of purulent matter continued, and great debility came on, the pain at the neck on motion or pressure remaining as before. Subsequently, severe vomiting came on and rigors, and he took the ammoniated saline medicine with sedatives. He became better and was getting on favourably, when suddenly he found that there was inability to move his arms, so that he was unable to feed himself. This was about five weeks after the accident. Eventually there was loss of motility in the legs, and the sphincters ceased to act, but it was not until a few days before death that he experienced any loss of sensation in any part of his body. He retained his mental powers, but gradually sank and died, the dysphagia becoming great.

Post-mortem examination.—The œsophagus was found at one point, for about 1½ inch, to be greatly constricted, but no opening remained through which pus had escaped. There was rather a large amount of purulent matter behind the œsophagus; and between the fourth and fifth cervical vertebræ the cartilage was perforated by an ulcerated opening which passed backwards into the spinal canal. The whole intervertebral cartilage was vascular, and so were the cartilages covering the opposed articulating processes of these vertebræ, and the ligamentous structure surrounding them was entirely destroyed. Opposite to the ulceration of the intervertebral cartilage the dura mater and other membranes were very much thickened and adherent to each other, as well as to the bone and to the spinal cord in this neighbourhood. The dura

Digitized by Google

mater for some distance was covered by recent soft fibrin. The spinal chord was generally somewhat softened, but for a short distance opposite to the fourth and fifth cervical vertebræ it was almost diffluent, and this was the case also in the lower part of the dorsal region.

In the cranium the dura mater was found in parts to be somewhat adherent to the bone, and the arachnoid to be also thickened and opaque, having much limpid fluid beneath it. The structure of the brain was "wet," and the central white parts somewhat softened.

In the thorax recent fibrin was found in the pleural cavities, and the lower portion of the lungs were in a so-called state of hepatization; and in one portion of the lung there was a condition passing under the name of lobular pneumonia. The heart and abdominal viscera were healthy.

Dr. J. W. Ogle, *5th of April*, 1853.

13.—*Apoplexy of the Pons Varolii.—Fatty and Earthy Degeneration of the Vessels.*

Mr. Barlow presented the pons Varolii of a woman, aged thirty-four, who fell down suddenly, on the 18th of April, and was brought to the Westminster Hospital, where she was admitted under the care of Dr. Basham. There were *right* hemiplegia with anæsthesia of the paralysed parts, and paralysis of the left side of the face, which was drawn to the right side by any movement of the latter; whilst, at one time, volition was noted to be able to close the right eyelids, although quite powerless over the left. Reflex actions of the paralysed lower extremity were very readily excited, and contrasted greatly with the form put on by the voluntary movements of the fellow limb. The circulation was feeble from the first; the tongue soon began to be dry and furred. It was remarkable that consciousness was maintained, and even intelligence, until two or three hours previous to her death, which happened on the 23rd of April. There was no arcus senilis.

On examination, no effusion was found in the cerebrum or cerebellum, but a section of the pons Varolii discovered a clot

Digitized by Google

in it as large as a filbert-shell, with a jagged, shreddy, slightly softened boundary of nervous tissue, which presented numbers of bloody points. A section of the pons in the mesial line passed nearly through the centre of the effusion, which by rupture had found way into the fourth ventricle. The vessels at the base of the brain were extremely degenerated, so were the small ones in the pons Varolii about the clot, and those also of the medulla oblongata. By the use of the microscope, aided with acetic acid, the degeneration was found to be partly fatty and partly calcareous; and scarcely any healthy vessels were seen. Some of the smallest vessels presented almost every form of dilatation; here a vessel was seen bulging at a particular point, there it was dilated into a complete pouch; both sides of the channels had yielded in some places, one only in others; a series of sacs were noted, in a few spots, to run along the walls; but nothing could be more positive than the various evidences of the weakening of the coats through degeneration.

Only the head was allowed to be examined, so that the associated condition of the heart could not be ascertained. Mr. Barlow referred to another case in which he found both calcareous degeneration of the blood-vessels of the brain and fibres of the heart. Acetic acid dissolved the matter in both instances. The earthy matter was within the sarcolemma of the fibres. It should be added, however, that some friends of his failed to discover the calcareous degeneration in portions of the heart given them for examination.

Mr. W. F. Barlow, *3rd of May*, 1853.

14.—*Fibrinous Substance, supposed to have been a deposit detached from the Mitral Valve, obstructing the Middle Cerebral Artery, in a case of Softening of the Brain.*

The right middle cerebral artery was seen blocked up at the point of its division into its branches, by a fibrinious body, dense and wart-like, resembling the deposits so often met with on the valves of the left side of the heart. The mitral valves of the patient from whom the artery was taken, were also shown,

Digitized by Google

on the free edges of which several of the same kind of deposits were formed, some of them being attached so slightly, that they were easily broken off. The middle cerebral artery was much swollen at the part where the body was impacted within it; but its coats, and those of the other vessels of the brain, were perfectly sound. The body was irregular in shape, with a smooth glistening surface, and about the size of a grain of wheat: it did not adhere to the coats; a thin, worm-like coagulum occupied an inch and a half of the proximal side of the vessel. On examining with the microscope a thin section of the body, and comparing it with a similar section of one of the warty excrescences from the mitral valve, the structure appeared identical in both. In the right side of the centrum ovale, over the anterior part of the lateral ventricle, was an oval portion of the brain, about the size of a small nut, where the colour was visibly duller than in the adjacent parts; and the tissue was so much softened, that when a section was made, the part sank and left a well-marked pit or depression. The specimens were taken from a female, aged fifty-one, who, when under treatment for fistula in ano, was attacked with hemiplegia, which came on slowly, and without the loss of consciousness; and she died in about twenty-four hours from the commencement of the attack. Mr. Shaw also exhibited a portion of heart, removed from a patient of his colleague, Dr. Crawford, in which the mitral valves were seen thickly fringed with warty deposits, some of them attached by very fine pedicles to their base. In this case, the right middle cerebral artery was completely blocked up by a little yellowish body, of the size of a grain of wheat, attached to the walls of the vessel by adhesions which were easily broken down; the coats of the artery, and those of the other vessels of the brain, were quite sound. As in the other case, the patient died with symptoms of softening of the brain; and in the anterior part of the right hemisphere was a portion of the brain, of the size of a large walnut, so much softened, that it could be washed away under a stream of water. Mr. Shaw considered these specimens interesting, from their illustrating the important and novel observations of Dr. Kirkes, as related in his paper, "On the effects resulting

Digitized by Google

from the detachment of fibrinous deposits from the interior of the heart," published in the last volume (xxxv.), of the "Transactions of the Medical and Chirurgical Society." Further details of the cases may be found in the "Medical Times and Gazette," vol v. p. 412. Mr. Shaw, 19*th of May*, 1853.

15.—*Congenital Absence of the Middle Portions and Left Hemisphere of the Cerebellum, in a Case of Chronic Hydrocephalus.*

"Philippe Lidstone, aged forty-four, was admitted into the workhouse department of the Guernsey Hospital on the 11th of November, 1829: he presented a mass of deformities which would take too long to describe, but of which the accompanying sketch may give some idea. The spinal column was curved anteriorly and to the right side, forming almost an acute angle; both legs were drawn up backwards on the thighs, and the right fore-arm was drawn up anteriorly on the upper arm, forming almost a right angle with it. Both his parents were drunkards, but otherwise healthy; their other children were healthy and well formed. Regularly, once a fortnight, he was seized with epileptic fits, which were ushered in with severe pain, for he used to scream out frightfully, and put his hands to his head, exclaiming, "Oh, ma pauvre tête!" He was in the habit of repeating the Lord's Prayer, and one or two other short prayers, every day: he did not start a conversation, but if asked any simple questions about himself, such as—Was he hungry? Did he suffer?—he would answer in a very rational manner. Taste, sight, hearing, smell, and touch, were all perfect. He never walked, but he could use his arms so far as his deformity allowed him. He had at no time delirium, paralysis, coma, or any other spasm than that attending the epileptic fits. The organic functions were more or less normal; he was frightfully passionate, and, from what I can make out, had long been addicted to masturbation. The largeness of the head was congenital, but the deformity of the body appears to have increased with his growth. From the death of his parents, and the death and absence of those who had attended to him, it was impossible to ascertain his history previous to his

Digitized by Google

admission into the hospital. His death resulted from exhaustion brought on by constantly recurring bed-sores.

"The circumference of the head was 2 feet 4 inches; there were very few hairs on the head, and the integument alone covered the cranium. There was no cranial aponeurosis or occipito-frontalis muscle: the dura mater was firmly attached to the bones. On raising the skull-cap, the brain was perceived to fluctuate; on wholly detaching it, six pints of fluid escaped through an accidental opening at its posterior part; in fact, the brain was nothing more than a large bag full of fluid. On removing the brain entirely away from the skull, the middle fossa was remarkable for being very deeply pitted on both sides. The bones of the skull were perfect, and not thinner than usual; all the sutures were, however, very distinct; the shape of the head from before backwards was an almost perfect oval: the lungs and liver were more or less diseased: all the other viscera were in a normal condition.

"The brain was not weighed, and the fluid was only examined with the naked eye: it presented much the appearance of the fluid drawn from a hydrocele slightly tinged with blood.

"Such is the history of the case, and the general post-mortem appearances of the subject, whose brain I send you for more particular attention. I regret that, from there being no records kept of any of the cases in the Guernsey Hospital, and no conveniences for post-mortems, they should be so meagre and imperfect."

The above account was sent by Dr. Cockburn, together with the brain, from Guernsey; and the following is a description of the appearances the brain itself presented on more minutely examining it. See Plate I., fig. 2.

External appearance.—The convolutions were very much flattened and smoothed out, especially above and on the left side, where, in one situation, they were almost effaced; and the lamina of brain was so thin in some parts as to be quite translucent. The longitudinal fissure was effaced, and gone from the expansion of the corpus callosum, and its elevation to the level of the upper surface of the cerebral convolutions.

Digitized by Google

Internal structures.—The whole of the internal surface of the brain formed one large cavity, by the expansion of all the ventricles, their free communication, and the destruction of the structures in the middle line.

The corpus callosum was entirely gone, being expanded into the general surface of the top of the brain. There was no septum lucidum. The remains of the fornix were only visible on the right side, where it was recognizable by the attachment of its margin to the choroid plexus, and the descent of its crus into the inferior cornu of the lateral ventricle. On the left side, the cornua of the ventricle could not be recognised, they were so completely opened out.

The posterior and middle commissures were perfect; the anterior was not visible.

The pineal gland and its peduncles were perfect.

The passage from the third to the fourth ventricle was not at all dilated.

The optic thalamus and corpus striatum of the right side had preserved a good deal of their natural shape: those on the left could hardly be recognized, they were so completely flattened out into the even surface of the general cavity.

The corpora quadragemina were perfect and symmetrical.

But the most remarkable condition was connected with the cerebellum; the central parts and the left hemisphere were altogether wanting; the right hemisphere being the only representative of it (See Plate I. Fig. 2.) There was no superior or inferior vermiform process, nor any of the structures that enter into the formation of the hemisphere on the left side, and no traces of superior, inferior, or middle peduncles. On the right side these were all perfect, and the hemisphere as well developed and of the same shape as natural; the floccules and amygdalæ distinct; the inferior peduncle of the natural size; the middle small, as there were no transverse or commissural fibres passing from hemisphere to hemisphere.

The pons was, necessarily, very small, in consequence of the absence of its transverse fibres: it looked ill-shaped and lop-sided, being stunted and shortened on the left side from the absence of the middle cerebellar peduncle. The fifth nerve

Digitized by Google

arose from the free margin of the pons, and was of the same size as the other; but of the seventh there was no trace, either of the portio mollis or dura; and the part of the pons from which they should have arisen, was atrophied and wasted.

The medulla oblongata was very large; and this, together with the smallness of the pons, gave the mesocephale something the appearance of that of a lower animal.

The space occupied on the right side of the cerebellum was on the other occupied by the expanded convolutions of the cerebrum, covering-in the dilated posterior cornu of its lateral ventricle, so that on this side there could have been no tentorium; and there could have been very little on the other side, as there was no fixed point of tension.

The general condition of the brain is such as is quite consistent with the general symptoms of the patient; and the contracted state of the right arm is interesting in connection with the condition of the centres on the left side. But there are one or two circumstances that seem rather discrepant. In the first place, it is strange that the power of co-ordinated movement should have been retained at all, with such a mere apology for a cerebellum. Again, of the integrity of the sense of hearing there seems no doubt, and yet the nerve of hearing on the left side did not exist; it is equally strange, too, that there was no facial palsy. Again, the degree in which the optic thalamus on the left side was flattened down and effaced, seemed too great to be consistent with perfect sight; but we are told that this sense was not affected.

Probably all the *deficiencies* were congenital, though the *derangements* from the fluid were of gradual and subsequent growth. The whole case is a good example of the extent to which the brain may be disarranged, if the process be gradual, without being fatal to life, or materially interfering with the functions of the organ. The condition of the cerebellum is undoubtedly the most curious of all the morbid appearances, and in this particular I think the case is unique.

Dr. Hyde Salter, *19th of May*, 1853.

Digitized by Google

Digitized by Google

DESCRIPTION OF PLATE I.

FIG. 1 illustrates Mr. Toynbee's report on Mr. Gay's case of tumor at the base of the brain. Page 16.

FIG. 2 illustrates Dr. Hyde Salter's case of congenital absence of the middle and posterior portions of the cerebellum, in a case of chronic hydrocephalus. Page 31.

Digitized by Google

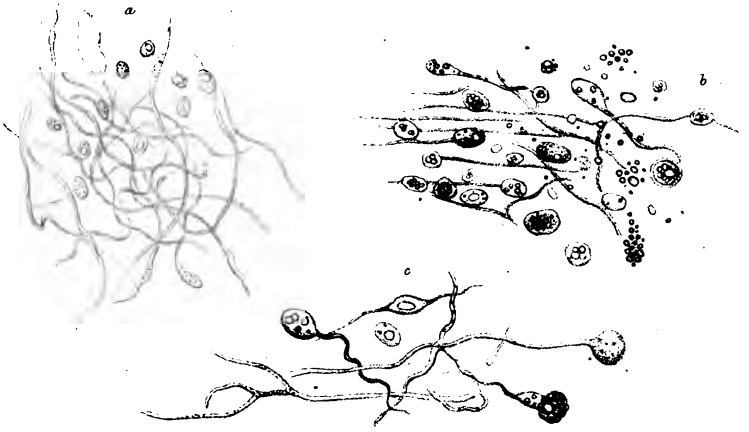

H Toynbee & J S Bristowe MD. del.

Fig 2

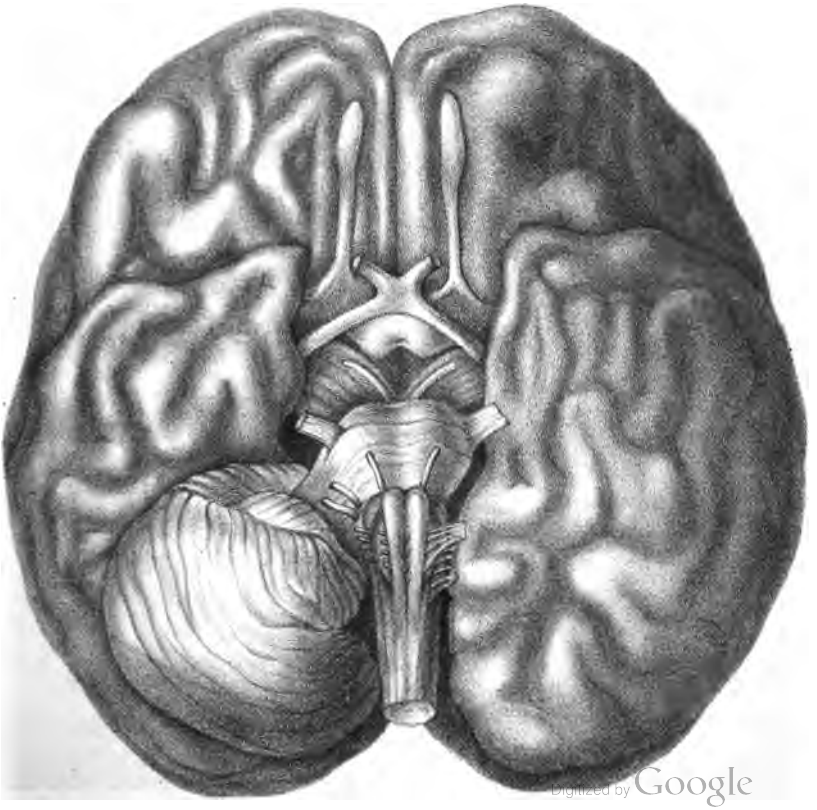

Digitized by Google

Dr Hyde Salter del Tuffen West lith.

Ford & West Imp 54 Hatton Garden

Digitized by Google

II.—DISEASES, &c., OF THE ORGANS OF RESPIRATION.

1.—*Co-existence, in the Lungs, of Cancer and Miliary Tubercle (?)*

The specimens exhibited were taken from the body of William Roe, a mason, aged forty-eight, who was admitted into St. Thomas's Hospital, under Dr. Barker's care, and died about a week afterwards, with symptoms resembling those of phthisis. There were a few old adhesions in the left pleura. The surface of the left lung was studded with moderately firm, greyish-white, slightly translucent granules, about as large as a small pin's head. Each was surrounded by a patch of blackened solidified lung structure. On section the lung was found to present a large number of these bodies, more or less clustered, and forming hard projecting masses of various size. They were grey, tough, yielded no sort of fluid on pressure, and presented to the eye all the characters of grey miliary tubercle. No other disease existed in this lung. The right pleura was extensively and firmly adherent, and presented two small abscesses communicating with cavities in the base of the lung. The upper and middle lobes of the right lung contained numerous bodies like those observed in the left lung. In addition to this, however, in the middle lobe there was found extending from the root, some little distance into the lobe, a mass of cancerous deposit which appeared to have been developed around its larger bronchial tubes and vessels. The lowest lobe was very extensively diseased. The malignant growth was in considerable and irregular masses, through which the vessels and ducts passed without being obliterated. In some places the walls of the ducts were so involved in the disease that the mucous membrane only remained; but in many they were ulcerated and destroyed so as to give the lung, on section, the appearance of being riddled with cavities. These deposits had all the characters of soft cancer—they yielded a cream-like juice, had a greyish-white colour, with a slight degree of translucency; were mottled in places with opaque yellow spots and streaks,

Digitized by Google

and presented occasional but not marked vascularity. In the walls of the cavities the opaque material was in excess, so that it assumed somewhat of the appearance of tubercle. In several places the disease was but slightly advanced; the lung structure, though infiltrated with it, being still easily distinguishable. The bronchial glands were also affected with cancer.

An irregular mass of encephaloid cancer occupied the left lobe, and another the lobulus Spigelii of the liver; the former as large as an orange, the latter half that size; both were formed by the confluence of several tumors.

The stomach and small intestines were healthy. The ileo-cœcal valve was partially destroyed by an ulcer as large as half-a-crown; it was irregular in shape, with sinuous, somewhat tumid margins; its surface was irregularly hollowed out; there was little or no thickening about it, and no fungoid granulations or growths. It had much the character of a tubercular ulcer, but there was no tubercle deposited in its neighbourhood. The large intestine presented numerous superficial ulcers, but they were all seated on the prominent parts, and had the appearance of being excoriations.

A small ulcerated opening existed at the posterior part of the left vocal chord; it communicated with a small abscess, into which projected the anterior angle of the arytenoid cartilage, ossified and necrosed.

There was undoubted cancer in the above case, both in the liver and in the lungs; even the cavities in the latter, though at first sight resembling tubercular cavities, were unquestionably cancerous. The question to be decided is: "Were the grey granular bodies, which were found in the left, and in a great portion of the right lung, really what they appeared to be, viz., miliary tubercles, or were they malignant growths, simulating that form of tubercular deposit?" The naked eye appearances (in which I am disposed to put more faith than in the microscopic) were, I conceive, altogether in favour of the deposit being tubercular. And I think the microscopic characters were not against but rather in favour of this view. The cancer in the liver was almost wholly formed of small oval nuclei, about as large as blood corpuscles; there were a

Digitized by Google

few nuclei twice this size, and a few granule cells; when the nuclei were separate, a little flocculent matter was seen adhering to them, but no trace of cell-wall. The cancer in the lung consisted almost entirely of nuclei, rather larger however then those in the liver, and in those parts where the disease was comparatively little advanced, the fibrous material of the lung tissue was distinctly visible, but infiltrated and crowded with densely aggregated nuclei. It was somewhat different with the miliary tubercles. It seemed as if the deposit, whatever it was (at least in the earliest stage), was seated in the air cells, and not infiltrating the tissues. The deposit contained numerous nuclei, and these nuclei were about the size and shape of those in the liver, but then they as much resembled those in the non-cancerous cells of the bronchial mucus. Again, they were by no means so closely aggregated, but were separated from one another by a considerable amount of granular matter and fibrils; indeed it seemed to me that the deposit consisted in an accumulation of closely packed and disintegrating cells in the air cells. In short, it resembled the cancer of the liver in the character of its nuclei, but in that respect equally resembled the bronchial mucus. It differed from the cancer in not infiltrating the tissues, and in the fact of the nuclei only forming a comparatively small portion of its bulk; and lastly, so far as my experience goes, it presented no microscopic character, no amount of organization incompatible with tubercular deposit. I may add that, though I believe the ulcer on the ileo-cœcal valve not to have been malignant, its nature may admit of some doubt. The affection of the larynx, however, much more resembled scrofulous disease than that of the intestine did malignant disease.

Dr. Bristowe, 19*th of October*, 1852.

Report on the preceding Specimen.—The liver was evidently cancerous, and in the pultaceous purulent-looking matter which occupied the cavities of the lower lobes of the lungs, the small and numerous cancer cells were only complicated by the admixture of pus corpuscles, and other products of inflammation, in sparing quantity.

Digitized by Google

The bulk of the upper masses, which looked so like miliary tubercles, consisted of small cells, precisely identical with those of the lower cavities. As far as could be ascertained, they differed only in being unaccompanied by pus or exudation corpuscles, and in being still bounded by the proper pulmonary texture. It is true that, here and there, this appeared disorganized, and was mixed with minute refracting granules and amorphous substance—appearances somewhat resembling those met with in tubercle. But the date at which the examination was made, and the somewhat putrid state of the specimen resulting therefrom, will not permit much stress to be laid upon such an admixture; while, since these masses not only contained a large quantity of cell growth, but of cells which could be recognized as similar to those of the evidently cancerous portions of lung, there do not seem to be sufficient grounds for considering them tubercle.

With reference to the incompatibility of cancer and tubercle, we would advert briefly to the facts and opinions of some of the most recent observers. Dr. Walshe, in his work "On Cancer," published in 1846, remarks that he had collected the histories of seven trustworthy narratives of cases in which cancer and tubercle were found after death in the same subject. Dr. Bennet, in 1849, wrote:—"Instances are common where individuals have tubercles in youth, and cancer in adult age; but," he continues, "I have not seen or heard of a well-authenticated case where recent tubercle and cancer were associated."

Lebert, in his "Treatise on Cancer," published in 1851, says that in the examination of 173 subjects, some of the organs of which were the seat of cancer, he found recent tubercles in 15. The second part of Virchow's "Archives" for the present year contains a paper by the same observer on colloid cancer, in which he gives the details of 11 cases of that disease. The second case is that of a man in whose body colloid cancer of the pylorus and tubercles in the lungs were conjoined. The conclusion at which Lebert arrives is, that individuals affected with cancer are as liable to become tuberculous as those of the same age who are free from cancer. But in regard of the

Digitized by Google

supervention of cancer in the progress of phthisis, he believes it to be very rare, as no example of it has yet fallen under his observation.

Rokitansky thinks that it is, on the whole, more usual for cancer to follow tubercle than the reverse. He seems to doubt whether the two have any real relation to each other beyond that of coincidence. And he expressly mentions suppurating cancer as being sometimes accompanied by a whitish glutinous tubercle, which he regards as the tuberculous disease of the already cancerous fibrine.*

Drs. JENNER and BRINTON, *2nd of November*, 1852.

2.—*Secondary Deposits of Medullary Cancer on the Free Surface of the Pulmonary and Diaphragmatic Pleura of the Left Chest, and Small Cancerous Nodule on or in the Endocardium of the Right Ventricle.*

W. B., aged thirty-three, a native of London, gaining his livelihood by cleaving wood, died from the exhaustion consequent on a large cancerous ulcer on the left side of the face, on December 3rd, 1852.

A year previously, he had first noticed a painful enlargement of the left side of the lower jaw, and soon afterwards was a patient in St. Bartholomew's Hospital, on account of it. At that time he had a pale earthy complexion, was emaciated, and looked most miserably ill. The bone was removed by operation, and its layers were found to be split up by the extensive interstitial deposit of soft cancer. The wound healed, but within two months an induration appeared above the cicatrix, which grew to a large size, and ultimately ulcerated. It was not thought advisable to attempt any further operation, and he left the hospital. The ulceration progressed, and his cachexia increased; the pain caused was very severe, and at last wore him out. There had been no particular chest symptoms, save

* See the report on a case in which tubercles and cancer co-exsisted, in vol. iii. p. 256 of the Pathological Society's "Transactions."

Digitized by Google

an occasional stitch and slight difficulty of breathing, and the stethoscope is not known to have been ever used.

Post-mortem examination.—Body emaciated to the last degree. The lower half of the left cheek destroyed by a large ulcer, with ragged ridges and sloughy base. The neighbouring glands enlarged.

On opening the thorax, both lungs collapsed more than usual. Nothing abnormal could be detected on the right side. The layers of the left pleura were adherent posteriorly. On the pulmonary layer, especially in the lower thirds, were numerous flattened nodules, varying in size from that of a split pea to that of a shilling, tolerably firm, and presenting a smooth and glistening surface. At the free edge of the lower lobe, they formed a continuous projecting border. On the pleura covering the diaphragm, they were both more abundant than elsewhere, and more raised. A few existed on the costal pleura, near to the spinal column, but that membrane was in all other parts quite free from them. When cut across, a creamy juice exuded, which presented, under the microscope, very numerous elongated cells, containing from one to three nuclei, crammed with large granules: some of the cells were caudate and acuminate; many nuclei floated free in the fluid. The nodules were on the free surface of the pleura, and might be scratched off, leaving that membrane entire. They were enclosed in a delicate glistening cellular envelope. No deposit could be found in the bronchial glands, or in any part of the lung tissue.

The heart was large, flabby, and almost covered with a thin layer of fat: its pericardial investment was everywhere smooth, and in a healthy condition. On opening the right ventricle, there was seen projecting from the lining membrane a pea-sized semi-transparent nodule, with a smooth exterior, and very defined border. On making a section across it, it was found to dip into the muscular structure, to which it firmly adhered. There was, however, not the least infiltration around it. No similar deposits could be found in any other part of the viscus, the whole of which was carefully sliced up.

The liver, pancreas, stomach, kidneys, intestines, bladder, and testes, were examined, but no cancerous deposition detected.

Digitized by Google

The cortical structure of both kidneys was thin, and whiter than natural.

Some blood was removed, and examined microscopically, but no cancer-cells detected.

The nodule in the heart, when scraped, yielded sparingly a juice which contained large round cells, with from one to three nuclei, and also some well-marked caudate cells.

Mr. HUTCHINSON, *7th of December*, 1852.

3.—*Tuberculous Deposits in Lungs, Spleen, and Kidneys.*

J. C., a chimney-sweep, aged thirty, had always enjoyed good health until a few months before his death. He at that time caught cold, coughed much, but sought no medical advice; unable to work, he wandered about exposed to wet and cold, badly clothed and fed, and at length sought admission into St. Mary's Hospital. He came in on the 19th November and died on December 9th. Treatment appeared to have no effect in arresting the progress of the disease; pericarditis and pleuritis came on a few days before his death.

The lungs were found to be studded with grey tuberculous deposits, from the size of a pin's head up to that of a pea, particularly towards their apices; some of them projecting beneath the pleura, which membrane was slightly roughened over the lower and posterior part of both lungs.

Pericardium contained about eleven ounces of serum tinged with blood; the anterior surface of the *heart* was slightly roughened over the right ventricle; some deposits of fibrin existed on the posterior surface; the roots of both arteries much roughened. The internal surface of the heart healthy; clots of blood very strongly adherent to internal surface of the ventricles and auriculo-ventricular valves.

Spleen and *Kidneys* both studded with yellow tuberculous deposits, but the spleen more so than the kidneys.

The other organs and brain were free from tuberculous deposits; in those organs affected, the tissue immediately surrounding the tubercles appeared perfectly healthy.

This case presents a marked example of what might be called,

Digitized by Google

from its rapid destruction of life, the malignant progress of tuberculous disease.

Two interesting observations were noticed in respect of the diagnosis. The amount of tuberculous deposits at the apices of the lungs was about equal in each, bnt the dulness produced by percussion was markedly greater beneath the right than beneath the left clavicle, and was observed to be so on several different occasions; the autopsy showed that the right apex was everywhere adherent to the thoracic walls, the left unattached; might it not hence be concluded, that the adhesions interfere with the vibration of the walls?

Again, the double murmur heard over the roots of the aorta and pulmonary artery, and extending to the top of the sternum, was of such a character that the most practised ear could scarcely have assigned to it, with certainty, its proper origin; indeed, those who observed it rather believed it to be an *endocardial* murmur; the dissection proved it to be *exocardial*.

Dr. MARKHAM, 21*st of December*, 1852.

4.—*Tuberculous Infiltration of the Lungs and Spleen, together with Fatty Liver.*

The subject of these diseases was a child aged three months: it had been under the care of Mr. Skegg, of St. Martin's Lane, and until a week before its death no symptoms of importance were observed. Occasional cough and diarrhœa were present, but these generally yielded to a few doses of medicine. The child was nourished by the breast; the mother, aged twenty-five, was pallid in appearance, but otherwise healthy. No hereditary predisposition to tubercle appeared to exist, but the parents lived in a narrow and badly ventilated street.

A few days before death the breathing became somewhat embarrassed, and the respiratory murmur was then observed to be indistinct over both lungs. The child became collapsed and died on the 16th of April, 1853; medical advice having been first sought on the 11th.

The body was plump and very pallid: the size greater than that of most children of the same age. A large quantity of fat

Digitized by Google

covered the anterior parietes of the chest and abdomen; the left pleural cavity contained about two ounces of clear serum: left ventricle of the heart was hypertrophied, and the general condition of the organ pale, lax, and lacerable.

The stomach and intestines normal: the mesenteric glands slightly enlarged.

Both lungs were closely studded with small yellow tubercles, the greater number being soft, but some were of a cheesy consistence. The spleen was about one-third larger than natural, and tuberculous spots could be seen through its capsule.

The Malpighian bodies were large, and some of them contained tuberculous matter; tubercles were also seated between these bodies. The liver was rather beyond its normal size and was fatty throughout, resembling in colour and consistence that of a cod-fish. The gall-bladder was empty. The brain and kidneys were not examined.

Microscopical Appearances.—The corpuscles of the blood collected from the fresh specimens sent to Dr. Crisp were all white, and rather larger than natural. The tuberculous matter of the lungs and spleen was composed of un-nucleated cells, rather smaller than the blood-corpuscles, and less regular in form. A large quantity of granular matter was combined with these cells, and the softer tubercles of the lungs contained many pus-globules. The liver retained but little of its normal structure, adipose degeneration existing to a great extent. The microscopical appearances, &c., were illustrated by drawings.

Dr. Crisp remarked that there were several points of interest in this case, viz., the almost total absence of symptoms to indicate these extensive lesions; the plump condition of the child, the presence of tubercles in the spleen, and their absence in the liver, a circumstance in this, and in many other cases, of some physiological importance.

Dr. Crisp, 19*th of April*, 1853.

Digitized by Google

5.—*Hydatids from the left Lung, subsequently to the occurrence of Typhoid Fever, complicated with Double Pneumonia.*

The extreme rarity of pneumenia being followed by the expectoration of pulmonary hydatids, and the pathological interest necessarily attached to the latter bodies, induce me to present the following interesting case.

H. C., aged forty-five, of nervo-lymphatic temperament, married, mother of ten children, had just completed the sixth month of her eleventh pregnancy, when she was seized, on May 17th, 1852, with typhoid fever complicated with double pneumonia. She had, until this time, enjoyed good health, had always recovered quickly from her confinements, and had for twenty years, weighed from 11½ to 12 stones. She was 5 feet high, well proportioned, and had great capacity of chest.

On visiting her, I found her suffering from extreme shortness of breath, which amounted, by paroxysms occurring at intervals of eight or ten minutes, to a sensation of threatened suffocation, accompanied by an indescribable feeling of syncope. She complained, in broken sentences, of a sensation of weight and of intolerable heat in both scapular, infra-scapular, infra-mammary, and axillary regions; but particulary on the left side. The following notes were taken at the time:—

Thorax.—Breathing short, laboured, and catching; inspirations forty-four per minute; expansion of the lower half of the chest less on the left than on the right side; percussion considerably duller in the left than in the right regions of the thorax already named; duller in the latter than in perfect health; auscultation reveals complete absence of the vesicular murmur in the lower posterior half of the left lung, in which a rough tubular respiration and bronchophony are well marked; in the corresponding portion of the right lung vesicular murmur is diminished in intensity, whilst tubular respiration and bronchophony are distinctly recognised; cough incessant, short, and dry.

Circulatory system.—Action of the heart abrupt; but sounds perfectly distinct, and free from any exocardial or endocardial

Digitized by Google

murmur; pulsations 125 per minute; radial pulse small, soft, and easily compressed.

Digestive and Urinary systems.—Tongue large, congested with venous blood, covered with a thick, dirty-white, creamy load at the sides, yellowish-brown in the centre; great thirst; no appetite; liver normal; bowels natural; urine scanty and high coloured; no sediment on cooling.

Cerebro-spinal system.—Feeling of constriction over the brow, and of complete languor and prostration; restlessness; some degree of loquacity; occasionally slight incoherence.

Countenance.—Expression of great anxiety; conjunctiva slightly injected; pupils natural; alæ nasi in visible action; lips somewhat blue; face bedewed with a cool perspiration.

General surface.—Temperature of skin slightly increased; diaphoresis commencing.

From the above threatening condition it was evident, that unless the present respiratory capacity could be quickly increased, the patient must shortly perish. With this view, therefore, the circulation through the skin was augmented by additional clothing, extensive counter-irritation to the chest was made by mustard poultices, again and again repeated; whilst a free circulation of cold air through the apartment was obtained by keeping the window and doors open. The hair was cut short, and kept constantly wet with cold vinegar and water, the chest was gently raised, and perfect quietude enjoined. A grain of the chloride of mercury, together with a mixture containing the acetate of ammonia, camphor mixture, and mucilage, was given every two hours; whilst the diet consisted of cold milk and water as a common drink, fowl broth, and raw egg beaten up in common gruel.

On the following day the number of respirations had fallen to thirty-four per minute, and the pulse to 108. The breathing was less laboured; expectoration was being established, and a distinct submucous rhonchus was audible in limited spots over the affected portion of the left lung. On the right side, where an indistinct vesicular murmur was heard the night before, there was now a complete absence of such murmur, and

Digitized by Google

nothing but rough, tubular breathing and bronchophony could be detected.

The sputum, as yet scanty in quantity, was of a deep rust-colour; and on microscopic examination, exhibited great numbers of blood-discs, epithelial patches, exudation-masses, isolated exudation-cells, and masses of simply coagulated fibrine, together with an increase of mucus-cells, all of which I have elsewhere figured.*

On the third day the chest affection was improving in both lungs; expectoration was fully established, the quantity of sputum expelled amounting to eight ounces by measure in twenty-four hours. It was of the same colour and presented the same structures under the microscope as before named. The respirations were thirty per minute; breathing less laboured.

The fever symptoms, however, had increased. There were increased heat of the head, particularly of the forehead, delirium, dry brown tongue, tenderness of the epigastrium extending to the umbilical region, but no diarrhœa. Pulse 104, small, yet less easily compressed.

On the fifth day the vesicular murmur could be heard in the affected portion of the right lung; but its intensity and duration were, in point of comparison, but half those of the healthy sound. With this return of the vesicular murmur a subcrepitant rhonchus was audible in the minute bronchi and cells; whilst a coarse mucous rhonchus pervaded the whole of the larger tubes. In the posterior half of the left lung the vesicular murmur was still absent; and a coarse mucous rhonchus only was audible over the isolated points above indicated.

The quantity of sputum expelled in twenty-four hours amounted to ten ounces by measure, and its colour and morphological character were similar to those already described.

On the sixth day the symptoms were steadily improving; the number of respirations had fallen to twenty-eight per minute, the breathing was less laboured, cough less frequent;

* See Papers "On the Pathology of the Bronchio-pulmonary Mucous Membrane," published in the "Monthly Journal of Medical Science" for the current year, by the Author.

Digitized by Google

expectoration easy, and blood beginning to disappear from the sputum; delirium was less urgent; the tongue, for the last three days, dry and brown in the centre, showed a disposition to become moist at the edges; the skin, which for the same length of time had been hot and dry, was now bedewed with gentle perspiration; the epigastrium was less tender, and the pulse had fallen to ninety-eight, becoming, at the same time, larger in its volume and firmer under the finger.

On the morning of the seventh day a measle-like eruption was observed on the trunk, and, for the first time, a deposit of urate of ammonia appeared in the urine. On the ninth day blood disappeared entirely from the sputum.

Having thus established the fact of the existence of typhoid fever and double pneumonia, suffice it to say, that the single application of two leeches to the inside of the nostrils and four to the epigastrium, followed by a blister to the latter region—the continued admission of cold air into the patient's apartment; the steady use of alkalies; mercury, stopping short of its specific effect; camphor, henbane to allay inordinate cough; light, vegetable tonics on the cessation of inflammatory action; repeated blisters to the chest, and a light, nourishing diet throughout, restored the patient to convalescence by July 18th, the case having, during its course, observed many fluctuations.

The lungs, however, and particularly the left one, were not by any means restored to their natural condition. From one inch below the spine of the left scapula downwards, there were distinct and isolated portions of the surface, over which the vesicular murmur could not be heard in the slightest degree, and only rough, distant, bronchial respiration during a forced inspiration; whilst, between such isolated points, a mucous rhonchus was audible during the greater part of the respiratory movement. On the right side the vesicular murmur was audible during easy inspiration; but it was accompanied by a degree of roughness and harshness, and followed by prolonged expiration, all of which showed that the interior of the cells was still irregular from inflammatory exudation, that the walls of such cells were yet in a thickened condition, and that

Digitized by Google

the free movement of their individual fibres was thereby impeded.

I now, at the request of my patient, who thought herself sufficiently well to dispense with my services, discontinued my attendance. For sometime she still continued to improve; and on the 16th of the following August, she was delivered of a fine, healthy child, and subsequently had a good recovery. On February 23rd, of the present year, I was once more requested to visit her. She now told me, that in October, 1852, her cough and expectoration returned with a "slight cold;" that the former had gradually increased in severity, and the latter in quantity; and that, for four months, she had frequently "coughed up small bladders of water," which invariably burst immediately before passing into the mouth, and filled the latter with a "kind of salt water." She further remarked that, on the expulsion of these "bladders of water," a quantity of blood, varying from a teaspoonful to a wine glassful, together with now and then a quantity of pus, was also expelled by cough; that for some days previously to their expulsion the quantity of sputum was diminished, and the cough more troublesome; and that she could tell, by her sensations, the route by which the hydatids were expelled, which she pointed out as extending from the lower angle of the left scapula, along the inferior margin of the base of the corresponding mamma, to the lower part of the sternum.

Her appearance, at this time, bespoke considerable emaciation. Her countenance was pale and haggard; her eyes were sunk, conjuctivæ pale, and the pupils slightly dilated; the alæ nasi were in visible motion; the teeth seemed to project; the malar bones were prominent, and in the skin over these there occasionally lingered a hectic flush. The skin was generally hot; the pulse 110, small, feeble, and very easily stopped; the tongue was covered with a slight, white fur; more or less thirst, together with loss of appetite, always existed; the bowels were regular; and the urine, natural in quantity, was loaded with lithiates. Profuse perspirations harassed her during the night, whilst her debility, during the day, was so great, that she was frequently unable to leave her bed; and

Digitized by Google

when she did leave it, she betook herself to a sofa, on which she reclined.

On examining the chest, there appeared to be a little fulness in the lower posterior half of the left side; the mensuration of which side, as compared with the corresponding portion of the right, showed, at the extreme of the ordinary expiratory effort, an increase of $\frac{3}{12}$ths of an inch beyond the latter. On comparing the two sides, however, at the extreme points of forced inspiration and expiration, it was found that the range of action of the lower half of the right side was $\frac{5}{12}$ths of an inch greater than that of the left, thus showing that the tissue of the left lung was constantly kept in a state of medium distension, by a cause foreign to the function of that organ. The upper parts of the chest, on both sides in front, had an equal play, which appeared to be somewhat greater than that which is manifested in the ordinary respiratory movements of the female. Percussion here elicited a clearer sound than in ordinary health; in the posterior part of the right lung, as nearly as possible the sound of health; in the corresponding portion of the left lung, a sound considerably lower than the latter. At a point five inches in the perpendicular direction from the spine of the left scapula, and three inches in the lateral direction from the vertebral spine, distinct cavernous respiration and pectoriloquy were present. From a point two inches below the spine of the left scapula downwards, the respiration, except over the site of the cavern, was absent during the ordinary respiratory movement; but, during forced inspiration, rough, low, bronchial respiration and a mucous rhonchus were heard at several isolated points. Immediately beneath the spine of the left scapula the vesicular murmur was somewhat reduced in intensity, and accompanied by a crackling and crumpling, thereby indicating vesicular emphysema of this portion of the lung. In front, from the supra-clavicular fossa downwards to the nipple, there was augmented vesicular murmur, which was also present in a less degree, in the upper half of the right lung; whilst, in the lower posterior half of this organ, a slight degree of roughness during the respiratory movement, was all that indicated the existence of previous disease in that situation.

Digitized by Google

The quantity of sputum expelled in twenty-four hours varied, sometimes amounting to two, at other times to four ounces. It presented a dirty-white, or yellowish-green colour, was more or less viscid and tenacious, of irregular consistence, and of the specific gravity of 1·028, at a temperature of 63° Fahr.

Microscopically examined, it was seen to consist of numerous exudation-masses and exudation-cells, plastic and pus-cells, and portions of nerve-tubes and of lymphatic vessels, irregular masses of opaque matter, a few bronchial casts and epithelial patches, together with an ordinary proportion of mucus-corpuscles, as represented at Plate II, Fig. A.

The analysis of this specimen gave the following composition:—

	In 100 parts.
Water	96·93
Organic matter	2·77
Chlorides of Sodium and Potassium Alkaline Sulphates and Phosphates	·27
Sulphate and Phosphate of Lime	·03
	100·00

Such, then, generally, was the microscopic and chemical nature of the sputa at this period. Early in March, both nerve-tubes and lymphatics disappeared from the sputum, and, thenceforward, the case has observed a progressive improvement. On the 13th of May, the day after the last expulsion of hydatids, a careful examination of the chest and of the sputum was again instituted. The only difference in this examination, as compared with the one above detailed, was, with respect to the physical signs of the chest, a diminution in the intensity of the vesicular murmur in the upper portion of the left lung, which murmur was now less distinctly heard than the healthy respiratory sound. The extent of the cavern in the lower lobe of this lung, as ascertained by admeasurement on the 15th of March, and again on the 13th of May, was 2½ inches in the perpendicular, by 2 inches in the transverse direction. At the latter date the number of respirations was 20 per minute, the breathing was only sensibly hurried on exertion, and the cough was much less troublesome than formerly. The pulse was 86, small and somewhat feeble; the tongue moist and covered

Digitized by Google

with a slight, white fur; there was little or no thirst; the bowels were regular; and the appetite, deficient in the morning, was reported to be very good in the latter part of the day.

The quantity of sputum expelled in twenty-four hours amounted to two ounces by measure; its colour being yellowish-white; and, on the 13th of May, it had the specific gravity of 1·026. Microscopically examined, at this period, it exhibited great numbers of pus-cells, varying in size from $\frac{1}{2500}$th to $\frac{1}{4000}$th of an inch in diameter; plastic-cells of similar growth; exudation-masses and exudation-cells, large, well-developed mucus-corpuscles, and here and there a basement patch. Immediately, however, before the expulsion of the hydatids, a few bronchial casts were, in addition to the above structures, present in the sputum.

Fig. B, Plate II, represents the microscopic character of the sputum at the date above-mentioned.

A careful analysis gave the following composition :—

	In 100 parts.
Water	97·29
Organic Matter	2·29
Chlorides of Sodium and Potassium . . . . } Alkaline Sulphates and Phosphates . . . . }	·36
Lime (mixed as Chloride)	·06
	100·00

On comparing the above analysis with the previous one, it will be seen, that the sputum of the 13th of May, contained less organic matter and more salts than that of the 23rd of February. The reason of this is discoverable in the microscopy of the sputa at these periods, which shows that, in the sputum of the 23rd of February, a considerable portion of the organic matter was due to the presence of portions of the different structures composing the pulmonary tissue; whilst that of the 13th of May consisted almost entirely of structures in the process of growth, the required conditions of which involve the necessity for the presence of the alkaline salts of the blood in greater proportion than is observed in structures which have already completed their development. Now as, in the sputum of the 13th of May, cell-growth was in excess of that observed

Digitized by Google

in the sputum of the 23rd of February, the excess of salts in the former, as compared with the latter, is but the further confirmation of a law which obtains with respect to inflammatory exudations in the lungs, and which I have elsewhere developed.*

In passing to the special consideration and examination of the hydatids discharged, it may be remarked, that in the early part of their history, their expulsion took place at intervals of from two to five days; that, since the beginning of April, an interval from two to three weeks has elapsed; that their expulsion is preceded by a violent fit of coughing, a single paroxysm of which was formerly sufficient to effect the dislodgment, but which now requires to be again and again repeated, and not unfrequently extends over a period of several days; that, whenever one of the largest size has to be expelled, the breathing, during its transit through the windpipe and glottis, is greatly obstructed; so much so, indeed, that a momentary sensation of impending suffocation is excited; that, apparently at the moment of its passing the glottis, it bursts and fills the mouth with a fluid, which is described by the patient as being extremely salt to the taste.

Examined by the naked eye, the bodies in question represent semi-transparent, white, yellowish, or bluish-white, collapsed sacs, which vary in size from a small pea to a pigeon's egg. One, however, which was expelled on the 12th of May, and which is now in the possession of this Society, is equal in size to a hen's egg. The walls of these sacs are irregular as to their thickness; rough and flocculent on their outer surface; smooth within; consisting, in some, of several layers, and presenting an angular aperture at the seat of rupture.

Microscopically examined, they are seen, in point of structure, to approach, as nearly as possible, to that of a mucous membrane, and consequently to consist of an external fibrous tissue, within which rests a basement structure, surmounted by an imperfectly developed epithelium.

A fibrous tissue, however, cannot be detected in every spe-

* "Monthly Journal of Medical Science," 1852.

Digitized by Google

cimen examined; but when present, which is very frequently the case, it is seen in bands, and isolated, slightly-branching, fibrillæ. The former are generally from $\frac{1}{1000}$th to $\frac{1}{3000}$th of an inch in breadth, and are composed of fibrillæ varying from $\frac{1}{18,000}$th to $\frac{1}{18,000}$th of an inch in diameter, which run side by side, sometimes in a slightly wavy direction, without branching or altering their relative distance to each other. The latter, on the contrary, pursue an isolated course, are about $\frac{1}{3000}$th of an inch in diameter, slightly tubular, present nuclear enlargements at irregular distances, and give off, here and there, a single branch. These fibres correspond in structure to the yellow fibrous tissue; whilst the others are similar to those constituting the white fibrous tissue. As a general rule, neither blood-vessels, lymphatics, nor nerves form a part of this layer of the hydatid; nevertheless, I have twice seen, in specimens the most organised, a few isolated capillaries present.

The layer within this, which corresponds to the basement structure of mucous membrane, is not so uniformly set with nuclear points as the latter; consequently the epithelium does not observe such regularity and uniformity of extension as the epithelium of mucous membrane. It, on the contrary, exists in patches, which leave intervals occupied by irregularly developed cells and minute, opaque, and semi-transparent bodies, most of which show a disposition to cell development. Some of these cells are non-nucleated; others present one, and sometimes several nuclei. Hence the former correspond with the exudation-cell, and the latter with the plastic-cell. Acetic acid and liquor potassæ render them more transparent. By prolonged contact with the latter they are ultimately destroyed.

To ascertain chemically the proximate constituents of these bodies, five of medium size were boiled for two hours in distilled water, in a porcelain capsule, over a spirit lamp, after which the fluid was evaporated to a drachm by measure, and then set aside to cool. After having cooled to the temperature of the surrounding air no jelly-like consistence of the fluid was observed. On adding three drops of the tincture of galls to one half of it, no palpable precipitate was produced; whilst the same quantity of the tincture, added to a solution of one grain

Digitized by Google

of gelatine in half a drachm of water, threw down a copious precipitate. On evaporating the other half drachm of water in which the hydatids had been boiled, a small quantity of white, or brownish-white solid residue remained, which, however, was too small to afford satisfactory evidence, by the usual chemical re-agents, of its protein character.

The hydatids were next boiled for half an hour in alcohol, which was then set aside to cool. On cooling, no trace of fat was observed on the surface; and on evaporating the alcohol, but a slight trace of extractive matter remained. During the immersion of the hydatids in the boiling alcohol their bulk was reduced to one-third.

The hydatids in question were now thrown into 4 drachms of pure acetic acid, in which they immediately began to swell, and to become more transparent. After having boiled in this fluid for half an hour, they were removed, and the fluid was slowly evaporated. When half this fluid had been dispersed the remainder became milky, and immediately afterwards, under the continuance of heat, a thin pellicle, which subsequently broke into small flocculi, appeared on the surface of the acid. On exhausting the acid by evaporation, a white powder, weighing a little less than half a grain, was left, which redissolved in boiling acetic acid, exactly in the same manner as the coagulated albumen of the egg under similar circumstances.

The remaining portions of the hydatids were next subjected to the action of liquor potassæ, which, aided by heat, effected their complete disintegration, and acquired the colour of a rather strong solution of burnt sugar, thus demonstrating the characteristic action of the solvent on fibrine. The presence of the protein compounds was further shown by the addition of strong nitric acid to a fresh hydatid, which became yellow at the point of contact from the formation of the xanthoproteic acid.

Several hydatids were incinerated, and the ashes thus left, were digested in warm distilled water for a short time, after which nitrate of silver and chloride of barium were added to separate portions of the fluid. These, by the precipitates

Digitized by Google

thrown down, indicated the presence of chlorides and sulphates; whilst the presence of lime was demonstrated by adding to the insoluble residue of the ashes in water, first a drop of hydrochloric acid, afterwards the same quantity of a solution of oxalate of ammonia, immediately after which a copious precipitate of oxalate of lime was produced.

Thus, then, the chemistry of the walls of the hydatids showed that their proximate constituents consisted essentially of the protein-compounds in combination with the different salts which are necessary for their development into cells or tissual formations; whilst their microscopical examination as clearly indicated that such constituents had already acquired a considerable amount of organization.

On subjecting to the microscope the fluid of a small hydatid which had not burst during its expulsion, great numbers of exudation-masses and isolated exudation-cells were observed. The former were undergoing development into cells—the latter were well formed, and were of all sizes, as we see in the sputum of bronchitis. Besides these structures, there were also a few plastic, but no pus-cells—a few basement patches, and irregular black nodules and masses of the sulphate and phosphate of lime.

In this fluid the nitrate of silver detected the presence of chlorides—the chloride of barium, that of sulphates—and the oxalate of ammonia, preceded by the addition of hydrochloric acid, a strong impregnation with lime.

In commenting upon this case, the various points which, at this period, require special notice, resolve themselves into the following propositions:—

1. The pathology and nature of the hydatids discharged.
2. Their import as influencing the prognosis.
3. The treatment which they, in conjunction with the physical signs, indicate.

With respect to the first proposition, it is clear, from the physical signs of excavation in the lower lobe of the left lung, from the presence, at one time, of nerve-tubes, lymphatics, and other bodies of the sputa, as confirmatory of an ulcerative action in the pulmonary tissues,—and from the microscopical

Digitized by Google

and chemical nature of the hydatids expelled, as compared with the exudation of bronchitis,—that the hydatids in question have their origin in exudation-plasma, which is thrown out upon that surface of the excavated portions of pulmonary tissue which may be said to form the walls of each individual cavern. It there coagulates and forms a perfect lining for each excavation; and having thus obtained a *locus standi* and the necessary conditions for germination and growth, it undergoes those morphological changes of which it is capable from its own inherent vitality, modified by the tissues on which it is placed. Hence the formation of fibrillæ, exudation-cells, plastic-cells, and an imperfect epithelium. This imperfection of the epithelium, in reference to continuity of extension, has, as a necessary condition, portions of the basement-structure of the hydatid perfectly bare, on which the fluid exudation, which permeates the walls of the hydatid, coagulates and subsequently passes into cell-development. In this way only can we account for the presence of organic bodies within the sac of the hydatid. The existence of such structures in the fluid of the hydatid, and the chemical nature of the contents of the latter body, correspond, in these particulars, to the bodies found in the exudation of bronchitis and to the chemical nature of such sputa; whilst the absence of pus-cells from the fluid of the hydatid is readily explained by the non-vascular condition of the walls of the sac, and, therefore, by the want of that supply of oxygen to the structures contained within the hydatid, which is necessary for the degeneration of the plastic into the pus-cell. Still it is very possible that, with a non-vascular condition of a hydatid, the contained plastic-cells might degenerate into the pus-type; but this possibility seems to imply the necessity for a direct communication with the air taken into the lungs. This condition only occasionally existed in the above case; and its occurrence invariably took place on the expulsion of one or more large hydatids, and for several days afterwards, during which time only cavernous respiration and pectoriloquy were well marked. About the fourth day after the expulsion of hydatids the physical signs of pulmonary excavation became more obscure, and this obscurity in-

Digitized by Google

creased until the physical signs indicated, in a very indistinct manner, the existence of such excavation, with here and there the sounds indicative of a patent bronchus stretching partly through the consolidated mass.

From these facts, and from the presence of bronchial casts in the sputum immediately before the expulsion of hydatids, it seems very probable that, during the formation of the latter bodies, the bronchi leading to the seat of excavations were temporarily obstructed, by inflammatory exudation, at the point of communication with the caverns, and that by this means, a direct communication between the external air and the hydatids was prevented. Hence, then, the reason why the organic structures within the sac of the hydatids could not pass into the pus-type.

It has been before remarked, that the walls of some of the hydatids were of irregular thickness, and that they consisted of layers placed one within another. In explanation of this fact, it is easy to conceive, that, after a single layer of exudation, plasma has undergone partial organization, and has thus formed a lining for the excavations; its connection with the surface on which it is formed, may be disturbed by cough, and may thus admit of a further layer of exudation subjacent to it, which, in its turn, may undergo partial organization, and subsequent disturbance by cough or other causes, thus continuing the formation of layers to the third or fourth series. The partial separation, however, may not take place to the full extent of surface involved in the formation of the hydatid; and, in this case, a second exudation will be limited to those points of the surface between which and the corresponding points of the hydatid the connexion has been disturbed. Hence, then, the reason of the frequent irregularity of thickness in the walls of the hydatids.

In reference to the second proposition, *i. e.*, the influence which these bodies ought to have on our prognosis, I conceive that, as their organization demonstrates a strong disposition in the exudation-plasma to assume a permanently structural form, it is very possible that an undisturbed connection between the hydatids and the surfaces on which they are formed, may take place, and that a limit may thereby be given to the further

Digitized by Google

destruction of pulmonary tissue. Their formation, therefore, is, in my opinion, to be regarded as favourable to prognosis; but whether the favourable termination which they seem to indicate, shall or shall not be realized, will depend on the degree and extent of disease in the surrounding portions of lung, on the activity or inactivity of such disease, on the amount of reduction in the respiratory function, and its consequent effect upon the constitutional powers, and on the influence of external causes. In the above case it has been shown, that there remains considerable consolidation of the lower lobe of the left lung; that the greater portion, however, of the exudation is in a quiescent state; that the increased action of the right lung compensates, in a great measure, for the deficient action of the lower diseased lobe of the left; that the respiratory function has, in consequence, approached more nearly the standard of perfect health, and that the nutrition of the body is observing a proportionate ratio. A hope may, therefore, be entertained that the patient will recover. Should such be the case, what are the pathological changes that are likely to attend such a result? Will the hydatids last formed, remain as such, maintaining their *status quo* in every respect? Will they, on the contrary, become further organized, receive blood-vessels, be subject to molecular nutrition and decay, as are all living structures, and ultimately effect their own obliteration by the absorption of their fluid contents, and the gradual approximation and adhesion of their opposite surfaces? Or will a communication be established between their sacs and the bronchi, in the direction of which they lie, the inner surface of the hydatid at the same time taking on the function of a modified mucous membrane?

That, on the supposition of recovery, the hydatids will maintain their condition as such, is opposed to their present degree of structural development, which plainly indicates that the ultima linea of their organization is a close approximation to that of a mucous membrane.

That, on the same supposition, they will undergo a further degree of organization is certain; and this further organization will place them in the category of vascular structures (a result

Digitized by Google

already indicated by the occasional presence of a capillary blood-vessel in the outer or fibrous coat of the hydatid) under which condition they will, like all other living structures, be subject to the ultimate molecular action in the process of nutrition and decay. This action would consequently imply the capability of absorption, and the power of deposition; therefore occlusion of the hydatids may occur by

1. The shedding of their scattered epithelium.
2. The exudation of blood-plasma upon the whole of the basement structure of the hydatids thus laid bare.
3. The subsequent absorption of the fluid contents of the hydatids and the organization of the coagulated portion of the exudation, by which the opposite surfaces of their sacs will become united.

Again, it is very possible that, instead of the shedding of the scattered epithelium of the hydatid as just mentioned, this structure might become perfect, and thus form one continuous lining to the hydatid, owing to the acquirement, by the whole basement structure, of the necessary conditions for epithelial growth. In this case it is probable that the hydatid would exist as a permanent sac, which, having served the purpose of its formation, would manifest no ulterior object in the organism.

But the presence of an epithelium points to another result as the probably legitimate termination of such a case. It shows that the structure of which it forms a part, is destined to maintain an independent existence amongst the living tissues; therefore, on the supposition of recovery, it is probable that a permanent communication will be established between the sac of each hydatid and an adjacent bronchus by the expulsion of the obstructing cast of the latter, and the mechanical rupture of the contiguous wall of the former; that the lining of the hydatid will thenceforth assume the function of an adventitious mucous membrane, and that the pulmonary excavations will ultimately represent so many saccular dilatations of the bronchi.

Adopting then the view, that the formation of pulmonary hydatids is favourable to ultimate recovery, the indications of treatment have for their object—

Digitized by Google

1. To maintain the connection between the hydatids and the surfaces on which they are formed, in order that they may become vascular, and, to a certain extent, independent structures.
2. To maintain the *status quo* of the exudation which has been poured into the pulmonary tissues around the excavations, and to heal bronchial ulceration in the few tubes which are yet patent in the lower lobe of the left lung.

Now, the first indication will be fulfilled by maintaining a brisk circulation through the skin, and thereby guarding against pulmonary congestion, by allaying cough, which would disturb the connection between the hydatids and their parent surfaces, and by restoring the vital tonicity of the capillaries from which the exudation, necessary for the formation of hydatids, takes place. Hence the necessity for the use of warm clothing, the occasional exhibition of anodynes and sedatives, the observance of quietude of the voice, of a light, nutritious, but unstimulating diet, and of the steady perseverance in mild tonics, together with the maintenance of slight counter-irritation over the seat of disease.

To fulfil the second indication it will, in addition to the means already specified, be necessary to maintain a uniformity of temperature of the air breathed, which should be cool rather than otherwise, in order that the vital tonicity of the capillaries of the affected bronchi may be gradually excited to a healthier degree of action, by which the pathological condition of the vessels, necessary to the occurrence of further exudation, would be destroyed.

Here, I conceive, that the use of the alkalies, which have elsewhere been shown to exert such beneficial influence in the removal of inflammatory exudation, is powerfully contra-indicated; inasmuch as they, by the chemical action which they would exert upon such exudation, would not only tend to destroy the connection between the hydatids and their parent-surfaces, but also to excite the latent tendency to germination in the exudation surrounding and constituting the walls of the pulmonary excavations, and thereby to favour the extension of the latter. This objection, however, to the use of alkalies will

Digitized by Google

only hold good until the hydatids shall have acquired the condition of vascular structures, after which their exhibition will favour the disintegration of that portion of exudation, the quiescent state of which it is one object of the present treatment to preserve.

Having conducted the above case according to the views and principles here enunciated, I have the satisfaction of being able to state that a great improvement has already occurred; that this improvement is manifested by a less frequent expulsion of hydatids; a total cessation of all febrile movement, diminished cough, and expectoration; a diminution in the frequency of the respirations and of the pulse; an enlarged respiratory function, and a considerable addition to the weight of the body. In this last-mentioned respect, the difference between the weight of the body at the time of its greatest reduction and the present moment (May 19th), amounts to an increase of twenty-three pounds.

Such, indeed, is the manifest improvement which the patient has undergone, and so sensible is she herself of it, that she not unfrequently disregards advice by taking an active part in the management of her household duties.

Dr. QUAIN, for Dr. BLACK, *of Chesterfield, 19th of May*, 1853.

III.—DISEASES, &c., OF THE HEART, AND OF THE OTHER ORGANS OF CIRCULATION.

1. *Pericarditis, probably caused by Circumscribed Abscess of the Periosteum.*

P. L., aged thirty-three, was admitted, 1st of November, 1852, into St. George's Hospital.

He said that he had been ill for four weeks, and during three weeks he was confined to bed and treated for ague. He attributed his illness to cold, but he had no cough. He complained of pain in the epigastrium, extending towards the left side. His face was sallow and emaciated. The pulse, 112,

Digitized by Google

weak. Tongue coated at the back. Bowels rather confined. There was no jaundice, and he was found to have healthy respiratory murmur on each side of the chest. The heart's sounds were free from murmur.

On the 2nd of November he directed attention to a swelling in the epigastrium which, he thought, had been caused the previous night by a mustard poultice. It was situated just below the ensiform cartilage, and was elastic on pressure, but it was not sufficiently permanent to allow any fluctuation to be perceived.

During the following fortnight he suffered from nausea, vomiting, and oppression at the chest. Scanty, deep-coloured urine, without bile. He had, slightly, daily chills not amounting to rigors. The tumour rapidly increased in size.

On the 19th, the tumour was punctured, and 24 ounces of pus were drawn off. The breathing improved during the operation; towards evening the oppression of the chest and the difficulty of breathing returned. It increased the following day, and he died on the 21st of November.

Post-mortem examination, sixteen hours after death.—The body was in a tolerable condition. The integuments generally were rather of a yellowish hue. The costal cartilages were rather ossified, and on removing the sternum it was found at the lower part adherent to the surface of the liver. In the right pleural cavity some deposits of tolerably firm yellowish fibrin existed on the pleura pulmonalis. The lung was natural. The left lung and pleura were healthy. There was much thickening of the pericardium, which was lined by recent, soft, yellow fibrin; and when this was scraped off, there was much vascularity.

The heart was universally covered by recent yellow fibrin of considerable thickness, having a roughened, spongy fibrous surface, and it was very extensively adherent to the pericardium.

The pericardium was also extensively adherent to the diaphragm, and distended by very much purulent fluid. The heart's cavities were rather large, and the left ventricular walls very much thickened. Its valves and orifices were healthy.

Digitized by Google

Around the openings of the coronary arteries and in their walls there were several atheromatous deposits. A few ounces of amber-coloured fluid existed in the abdominal cavity. The stomach and intestines were congested, otherwise natural. The liver was adherent, at the left upper surface, to the abdominal walls, and to a considerable extent to the under surface of the diaphragm. This adhesion to the diaphragm, being interrupted by a thickish yellow, purulent fluid, contained a cavity with thick fibrous walls, shreddy with recent lymph, and formed by the upper surface of the liver and the under one of the diaphragm. It was into this cavity that the opening during life had been made. The diaphragm of this part was condensed and converted into a thick fibrous structure. The surrounding part of the diaphragm was partly in a fatty condition.

The liver was generally healthy, but near the surface, corresponding with the circumscribed abscess of the pericardium, were two abscesses in its substance. One of the hepatic abscesses was of large size, holding several ounces of purulent fluid. The walls were very thick and corrugated, of a yellowish-white colour. This fibrin was seen by the microscope to contain much fat. The other abscess contained much fatty matter. There was much fat in the hepatic cell-structure of contiguous portions of the liver; and the larger vessels in the neighbourhood were surrounded by more than an ordinary amount of fibrous texture. The gall-bladder and contents were healthy. Kidneys healthy.

Dr. B. JONES, *7th of December*, 1852.

---

2. *Enlargement of the Heart, with Earthy Deposit—Adherent Pericardium, and an Opening in it through which the Appendix of the Left Auricle protruded—Enlargement of the Liver—Fatty Degeneration of Heart and Liver.*

R. P., aged forty-three, of bilious temperament, well proportioned, about 5 ft. 10 in. in height, a carpenter, formerly of dissolute and intemperate habits, but latterly steady and sober, enjoyed good health until July last, when he fell off a ladder a height of about five feet. He attributed the fall to a feeling

Digitized by Google

of sudden faintness, and refers the commencement of his illness to this accident. He continued at his work until the middle of October, when he was compelled to give up; as it took him the best part of an hour to walk a very short distance. Up to this time he had been suffering from *occasional* palpitation, faintness, and shortness of breathing, increased upon the slightest exertion; great oppression at the pit of the stomach, aggravated so much upon lying down, that he had not attempted to do this for many nights.

He was first seen by his medical attendant, October 28th, 1852, when his appearance bore ample testimony to the obstructed circulation under which he then laboured. His face was almost purple, as well as his hands and feet; his breathing was very hurried; he had slight cough, but was free from actual pain in the chest or abdomen. His only complaint was, of the shortness of breath, and the incapability of lying down. The surface of the body was below the usual temperature. The action of the heart was tumultuous and rapid, but was not accompanied, so far as could be detected, with any abnormal bruit; the pulse could scarcely be felt at the wrist; there was a wavy pulsation in the course of the right jugular vein. A very distinct enlargement was apparent in the right hypochondrium, extending to the pit of the stomach; and it was of oppression in this region that he made most complaint. His urine was scanty, but *not* high coloured; albuminous; bowels regular. He was ordered a blister to the chest, a saline mixture, with hydrocyanic acid and liq. opii sedativ. in the day, and soap, opium, and squill pill at night. The relief he derived from these measures was but temporary; but on the substitution of morphia at night, the acetate of potash, taraxacum, and bitter infusion, he was enabled on two or three occasions, to lie down for about two hours. It is needless to note the daily and most distressing progress of the case, which was marked by the gradual development of symptoms referable to obstructed circulation. His days and nights were passed either sitting at a table with his head supported, or standing resting against the bed. The legs gradually became œdematous, the œdema increasing day by day. The oppression of the breathing became

Digitized by Google

more urgent, and the pulse more feeble, the palpitation and faintness more urgent.

About a week before his death, which took place on the 6th of December, his hands and feet became perfectly livid. Upon the feet, legs, and penis, gangrenous patches appeared, and to these succeeded inflammation of the character of erysipelas phlyctenodes. Two days before death, reaction took place in these parts, accompanied with excruciating pain. About this time also, he became jaundiced, and was able to lie down in his bed. For some days before his death, his respirations were remarkably slow, not quite *nine* in the minute.

Dissection, twenty-four hours after death.—Much fat tinged with bile under the abdominal integuments; cartilages of the ribs not ossified. About a pint of serous fluid in each side of the chest. Lungs slightly adherent to the costal pleura, and white patches deposited here and there interstitially in the pleura pulmonalis; lungs congested, especially posteriorly, otherwise healthy. Pericardium very much thickened, and preternaturally adherent to the diaphragm; so much so, that some of the fibres of that muscle were very much stretched, and drawn up over it.

Before the pericardium was opened, the appendix of the left auricle could be distinctly seen and felt, through a large hole in the membrane, the greater part of the circumference of which had a *round, smooth* edge, as if from congenital defect. There was a small quantity of fluid in the pericardium; heart exceedingly large and flabby, and adherent to the pericardium by a few long and strong adhesions, the result of former pericarditis, but by some also of more recent origin, which were easily separable; there was a large patch of ossific matter under the serous covering of the right ventricle, in the course of the right coronary artery. The structure of the muscular coat of the heart, examined by Dr. Quain under the microscope, exhibited a granular appearance: there were very few striæ, owing to the presence of incipient fatty degeneration. Both ventricles of the heart (especially the left, in which was a long and firm fibrinous clot, strongly adherent), were enlarged, and the walls somewhat thickened; the

Digitized by Google

valves of the aorta thickened, but not bony; ossific deposits under the lining of the ascending aorta, with augmentation of its calibre.

Slight serous effusion into the abdomen; liver exceedingly large, hard, and heavy. When cut into, it was found charged with bile, and exhibited the usual nutmeg appearance of a gin-drinker's liver; under the microscope it also exhibited marks of incipient fatty degeneration; gall bladder somewhat distended with dark-green bile, free from calculi; cystic duct small and contracted; stomach small and contracted; small intestines healthy; large intestines distended with flatus. The transverse colon took a particular course, proceeding from the angle that it forms with the ascending colon down to the symphysis pubis, and from thence in the same way back to the descending colon, somewhat resembling a large V, and it was particularly distended with flatus: the kidneys were very large and fragile, of a deep chocolate colour, like some of those figured in Dr. Bright's reports.

Remarks.—This case, I think, presents many points of interest, and some for speculation.

I would first remark upon the man's having been very intemperate formerly, his then becoming steady, and his having no apparent illness till six months ago. I say apparent, as I think it probable, from the appearance of the adhesions disclosed after death, that the pericarditis, under which he had evidently laboured, must have existed for a longer period.

To the evidences of pleurisy it is scarcely necessary to allude, as they are almost universally met with in persons who have appeared all their life healthy.

Upon careful enquiry it appears certain, that this man never had rheumatism; this, therefore, is another case to be added to those collected by Dr. Ormerod of recovery after non-rheumatic pericarditis.

Much of the distress which this man suffered was no doubt owing to the adherent pericardium, but much also, I think, to the coexistence of enlargement and hardness of the liver; the chest was not large enough for the heart so extensively diseased

Digitized by Google

to act freely, and the condition of the liver effectually prevented the free descent of the diaphragm, and consequently the possibility of sufficient augmentation of the thoracic space. It is interesting to observe the gradual development of the signs of impeded circulation, amounting at last to actual mortification of the extremities. It is also remarkable, that although the circulation was so feeble that it could not support the due nutrition of the body after mortification had ensued, inflammation was set up, which must be regarded as an imperfect and abortive effort at repair.

Although this state of the circulation was sufficient to account for the sphacelus which occurred; it is not improbable that the peculiarity of the season, productive of diseases of low type, had something to do with it.

Among other circumstances worthy of note, may be mentioned the slowness of the respirations (not nine in a minute); the jaundiced appearance, which did not come on till shortly before death, and which I do not think is quite accounted for satisfactorily by the post-mortem examination; and the absence of a bony state of the cartilages of the ribs, with such a tendency to deposit of bone among the coats of the aorta and upon the outer membrane of the heart. The fact, however, of greatest interest is undoubtedly the opening in the pericardium, through which the appendix of the left auricle was seen; and here the points for inquiry are: Was this opening congenital, or was it produced at the time of the accident? and again: Were the symptoms manifested due to this opening, or to the altered condition of the heart itself, and its adhesion to the pericardium? On a careful examination of the opening, from the roundness and smoothness of its edge, there can, I think, be little doubt that it was a congenital defect; and although the entire absence of any uneasiness about the chest until the fall, and his feeling faint immediately upon the receipt of the injury might lead to a contrary opinion, yet all things considered, especially the state of the appendix of the left auricle, its not appearing either constricted or congested, I think it most probable, that the symptoms had reference to

Digitized by Google

the general state of the heart rather than to the opening, with which, in my opinion, they had little or nothing to do.

Mr. R. R. Robinson, *7th of December*, 1852.

3.—*Enumeration of instances, taken accidentally, of "Fatty condition" of the Heart in various Diseases.*

The number of hearts examined was 143, and out of this number 100 were in a more or less so-called "fatty condition," the muscular fibres presenting, when examined under the microscope, more or less confusion or absence of their natural striated condition; a black, dotted appearance having been assumed, or having distinctly-refracting rounded and yellow particles in their substance, arranged for the most part longitudinally down the centre. The presence of fatty matter between the muscular fibres, the "fatty growth," in opposition to the "fatty change," has not entered into consideration here. Out of the 143 cases examined as to the hearts, there were 97 with "fatty livers;" and out of the 100 fatty hearts there were 68 that were associated with a more or less fatty state of the liver; the other fatty livers occurring unassociated with fatty hearts. Moreover, it by no means invariably happened, that the most decidedly fatty hearts were allied with the most decidedly fatty livers, but this was generally the case.

The following is the list of diseases with which a fatty heart was found; but of course several cases in this list are enumerated more than once, as when, for instance, a patient had at the same time diseased heart and diseased liver. The majority of the patients had been suffering from disease for some months, but several had been ill only for a few weeks, and some had not been the subject of illness of any standing.

	CASES.
Tuberculosis	21
Diseased Heart	31
„ Kidney	38
„ Liver	3
Fever (Typhoid)	3

Digitized by Google

	CASES.
Pneumonia	8
Peritonitis	7
Carcinomatous Glands	2
Brain and Spinal Cord, including extravasation of blood into their textures	7
Ditto with a fibrinous diathesis	13
Erysipelas	1
Perforation of Stomach	1
Poisoning by Oil of Almonds	1
Burns	2
Gangrene and Atheromatous Arteries	1
Delirium Tremens	1
Aneurismal Varix of large vessels of Heart	1
Operations or accidents followed by Bronchitis or Delirium Tremens, and with or without the so-called secondary inflammations	15

With regard to the fatty conditions of the hearts, I have in my own Tables considered them as either "slightly fatty," "decidedly fatty," or "very fatty," but in the present enumeration I have included them all under one denomination, only referring, as I shall presently do, to the "very fatty" and to the "slightly fatty" ones, in relation to the people in whom they were found. In speaking as above of the diseased livers and kidneys I have not included those instances in which these viscera were diseased by such specific deposits as the carcinomatous or scrofulous; or again, those which were simply enlarged by extreme congestion: among the diseased hearts I have included indiscriminately hypertrophoid and dilated ones, but not such as were affected simply as to their valves, except when further mischief to the heart had resulted. Again, in speaking of tuberculosis, I have not included the old cretaceous or obsolete deposits, but only those cases in which the specific tendency was obviously in an active state. Lastly, when speaking of a "fibrinous diathesis," as I have termed it, I had reference to those cases in which there manifestly existed a proneness to the precipitation of the fibrinous element of the

Digitized by Google

blood into various organs and cavities, and on to various free surfaces within the body; forming what is ordinarily called a "low inflammation" of the affected part. Under the supposition, which I believe to be tenable, that the atheromatous condition of the arterial system depends on this same tendency to fibrinous precipitation, this substance becoming subsequently converted into either a fatty or a calcareous one, I might well have been expected to have observed more intimately the condition of the cardiac, pulmonary, and cerebral arteries. This has, however, not been so frequently and so closely done as to warrant any decided statements on this point, but still I have several cases in which, on the one hand, so much atheromatous deposit existed in the coronary arteries of the heart as to make them firm, large, and brittle; but yet the heart has been in some instances only moderately, and in others only very slightly affected. One case in particular was worthy of notice, in which, although the coronary arteries were intensely atheromatous, calcareous, and fatty, yet the muscular fibres of the heart were only very slightly altered, but the entire organ was greatly atrophied generally, weighing but seven ounces, and that in a person fifty-seven years of age. Many of the hearts that were found to be fatty, and some that were exceedingly fatty, were firm and resisting; some were hypertrophied, others were dilated only, and others were both hypertrophied and dilated. Some that were very lacerable, and flaccid, and unfirm, were not very decidedly fatty; hence the observation not unfrequently made, on inspecting a weak and flaccid heart, that "it is certainly fatty," without any further examination, may be incorrect. This flaccid state has appeared to be rather dependent on imbibition, and a fluid state of the blood, as in fever, puerperal peritonitis, pyæmia, &c. Out of the 100 fatty hearts examined I find that 23 of them are marked as being only very slightly fatty, and the average ages of the patients in whom they existed was forty years, whereas out of nine which are marked as having most decidedly fatty hearts the average age was only thirty-six. Of the 23 with slightly fatty hearts one patient was the age of sixty-one; two were of the age of sixty-one; two were of the age of sixty-five, and three of the age of

Digitized by Google

fifty years; whereas of those with most extensively fatty hearts the highest age attained was sixty years, and one of the latter class was only of the age of ten years.

Dr. J. W. Ogle, *2nd of November*, 1852.

4.—*Granular and Incipient Fatty Degeneration of the Heart, causing Sudden Death.*

J. B. S. was brought to the Westminster Hospital on the 23rd of November, 1852. On being examined by Mr. Barlow, he was found to be quite dead. He was a muscular, but plainly a very old man, and had the arcus senilis well marked in both eyes, but it was not symmetrical, as it generally is, being better marked in the left eye than in the right. The man was a cabman, and, with the exception of the day on which the great public funeral took place, had done duty regularly. On inquiry, it was found that he was a temperate, active man, and had given no warning of a serious nature. How he was seized, and how quickly he expired, was not known. A policeman saw his cab moving slowly along the street without guide of the driver, who lay back upon his seat as though insensible, with the reins fallen from his hand. When the vehicle was stopped, he seemed dead already.

The body was examined about twenty-four hours after the supposed time of death. The limbs were in a state of most marked rigidity, especially the left arm, which was semi-flexed. Head:—The skull was uncommonly thick. The arachnoid membrane was generally opaque. The brain was shrunken; its convolutions were abnormally diminutive, and their cineritious covering pale and thin. The tissue of the organ was extremely tough, presenting (though not in an extreme degree) that form of fibrous degeneration which Dr. Sims and Cruveilhier have so well described. The septum lucidum and the olfactory nerves were not to be torn without some resistance. The large arteries were full of atheromatous degeneration, for the most part symmetrical. The left vertebral artery contained a mass of fibrine, about the third of an inch in length. It entirely surrounded the artery, but there was a channel

Digitized by Google

through it, so that the blood-current was diminished, not obstructed. It is important to note that the artery was highly degenerated at the spot surrounding this deposition, which undoubtedly had happened during life. Chest:—The right lung was emphysematous, but to no very great extent. The heart looked flabby, not preserving its rounded form, but lying flattened and depressed on the surface. Though neither fawn-coloured generally, nor mottled, it had a dingy aspect, and was generally deficient in firmness, but the left ventricle was so especially. Its cavities were dilated; so was the aorta, which was thickly studded with atheroma; the valves of this vessel were expanded and attenuated, as they frequently are when its calibre is increased. The coronary arteries were much degenerated, and contained in their coats very numerous minute earthy particles, brought to view by the microscope, and made readily to disappear by hydrochloric acid; there was not, however, the least narrowing of their channels, so far as could be seen. The perilous, and at last fatal, mischief seemed to be in the fibres. Fragile for the most part, and in some spots destroyed entirely, their striæ, viewed under the microscope, seemed disappearing in numerous places, though whole fibres were seen remaining perfect. The degeneration prevailed most in the left ventricle, but was largely diffused. It was for the most part granular,* but the granules were seen, in this spot and the other, to be undergoing conversion into oil-globules, so that there was, on the whole, a considerable amount of incipient fatty degeneration. There were but few

* Is not this granular degeneration of the heart similar to that noticed by Mr. Quekett in the voluntary muscles, and described by him as the "first trace" of fatty degeneration?—"Before fatty degeneration commences in voluntary muscles, the transverse striæ disappear; and I have long known that the first trace of this disease is marked by a disturbance of the particles of myoline, which appear as so many very minute granules scattered irregularly within the sarcolemma, leading one to suppose that the delicate cells around each particle had given way, thereby allowing the myoline to escape, and destroying all regularity both of the transverse and longitudinal markings. As the disease progresses, the myoline is replaced by minute, highly refracting globules of oil, until, at last, the whole sheath is full of them."—"Lectures on Histology," p. 196.

Digitized by Google

fat-globules observed between the fibres. Death was in this case principally referable to that granular and commencing fatty degeneration, which had involved and disabled so large a portion of the structure of the heart. A fibre, with its striæ lost, and its sheath filled with dispersed granules (whatever their kind may be), must be considered as not less without power and use, than were its sarcolemma filled with oil-globules, such as those figured and described by Dr. R. Quain, as the extreme form of fatty degeneration. The peril, in cases of degeneration of the heart, is proportioned to its extent, of course; but those cases must be excepted in which the heart ruptures from extreme though circumscribed degeneration, as the result of narrowing of an arterial branch. No ground is offered, in the above case, for imputing the granular appearance present to post-mortem changes. The body was examined whilst in full rigidity, and before a tinge of putrefaction was visible. There was a difference between the consistence and structure of the left and right ventricular walls, which was in favour of the latter; the most perfect striæ lay either by the side of, or mingling with, fibres which were spoilt and granular; and lastly, the pectoral muscle, on being scrutinized, was, with the exception of two or three fibres out of those examined, (and these were most trivially changed,) found, with its structure, in complete perfection. It should be added to this report, that the kidneys were rather atrophied, and contained cysts, but did not seem granular. The liver appeared healthy, and no fatty degeneration could be detected in it.

Mr. W. F. Barlow, *7th of December*, 1852.

5.—*Diseased Heart and Kidneys.*

The patient from whom these specimens were taken was a man aged fifty-three, admitted into St. George's Hospital on the 10th of November, 1852. He reported that he strained himself in July 1852, and soon afterwards experienced pain in the left hypochondrium, with palpitation and dyspnœa; cough, and hæmoptysis after a time supervened.

On admission he was exceedingly pale, somewhat anasarcous,

Digitized by Google

and his breathing was much oppressed: a loud systolic murmur was audible over the whole præcordial region, but was most intense at about the second right sterno-costal articulation. It was propagated along the carotid arteries, which were pulsating violently. An intense diastolic murmur also existed, heard loudest in the same situation. The pulse was the characteristic pulse of aortic regurgitation. The urine, which was never passed by the urethra, but escaped by a fistulous opening in the perinæum, was albuminous, and contained pus. His symptoms presented little variety. The extreme pallor of his face increased, the anasarca became more general, the breathing more oppressed; his appetite failed; frequent nausea and occasional vomiting occurred, and cough and extreme dyspnœa prevented his obtaining rest. Thus he became daily weaker and weaker; ultimately severe epistaxis commenced, and he then passed into a state of semi-consciousness, in which he remained for the few last days of his life. He died on the 21st of February, 1853. The right pleural cavity was completely distended by straw-coloured serum. On the left side of the chest there existed numerous old and firm adhesions. Both lungs were crepitant throughout. The apex of the right was somewhat puckered, and in its substance was a small cretaceous mass about the size of a pea.

A small quantity of clear serum was found in the pericardium. The heart weighed 21½ ounces; its walls, more especially those of the left ventricle, were enormously thickened; its cavities were not dilated. The valves on the right side were healthy. The mitral valve was slightly opaque, and somewhat thickened by the deposit of a small quantity of atheroma in its substance, but it appeared to be efficient. The aortic valves were also slightly, but very slightly, thickened by atheromatous deposit in their substance, but the common attachment of two of them was torn away from the aorta. It appeared doubtful, however, whether this tearing-away of their attachment was not done by the knife, inasmuch as what appeared like a cut through the inner coat of the aorta, was observed to run right across their attachment, and extended about a quarter of an inch on either side. The aorta immediately above the

Digitized by Google

valves was somewhat sacculated, and it was much thickened and rendered very irregular on its surface by an extensive deposit of atheroma. The kidneys were small and atrophied; granular on their surface; and presented numerous cysts, varying in size from a pin's head to a hazel nut. Under the microscope, numberless cysts were seen, which were quite invisible to the naked eye. In some places the uriniferous tubes were tolerably healthy; in others, choked up with fat-globules; in others again, but little trace of uriniferous tubes could be seen, the ordinary secreting structure of the kidney being completely broken up and replaced by cysts. The kidneys, in short, presented admirable examples of that form of disease described by Mr. Simon in vol. XXX. of the "Medico-Chirurgical Transactions," under the title of "Cysted Kidney." Neither the pelvis of the kidneys nor the ureters were dilated, affording presumptive proof that, in spite of the complete occlusion of the urethra, no material obstacle to the exit of the urine had existed for a considerable length of time. Mr. Gray has made a careful dissection of the urethra and the fistulous opening in the perinæum, and will give an accurate description of it.

The liver was not examined microscopically. It presented a strikingly nutmeg appearance; its edges were not rounded.

The spleen and the other abdominal viscera were healthy.

The physiological interest of the case consists in the enormous amount of disease of important organs which proved compatible with the continuance of life; whilst in a pathological point of view it is interesting as affording at the same time an admirable example of enormous hypertrophy of the heart; of that extreme degeneration of the kidneys which terminates in cyst-development; and of a perfectly impervious urethra, with the formation of a fistulous urinary opening through the perinæum.

Dr. FULLER, 1*st of March*, 1853.

Digitized by Google

6.—*Fatty Degeneration of the Heart. Death by Chloroform.*

C. B., a prostitute, between twenty-eight and thirty years of age, was admitted to the University College Hospital for sloughing phagedæna of the genitals, under the care of Mr. Erichsen. Little more was heard of her history than that she had sought employment a few days before from a female to whom she stated that she was destitute of food or dwelling-place. Her disease prevented her from performing the work assigned to her as a charwoman, and she obtained admission to the hospital. She appeared of a florid, rather bloated habit, and complained of nothing save the local disease. It was proposed to treat this by the application of nitric acid, and in doing so to use chloroform: the following is the history of that proceeding.

On a piece of folded lint, about 1½ inches square, and consisting of four doubles, a small quantity of chloroform was poured, and the lint then held at a distance of about three inches from the nose of the patient, so as to permit of the free admixture of air with the first few inhalations. After the lapse of about half a minute, the lint was brought nearer to the patient's nose (to within a distance of perhaps an inch), being never allowed to touch; at the same time a towel was lightly laid over the face of the patient and the hand of the operator, so as to prevent the escape of the chloroform vapour, but not to prevent the admission of air. During the whole time, the administrator kept his hand on the pulse, and occasionally examined the pupils of the patient. After inhaling for from two to three minutes the woman became a little excited, and began to talk and move her legs; the lint was then removed a little further from the face; in a short time she became more quiet, and in about eight or ten minutes from the commencement was fast asleep. Everything thus far had gone on satisfactorily; the pulse, which, previous to the administration, was regular, of average character as to firmness, and about 94 in frequency, had become accelerated under the first influence of the drug, but soon afterwards sunk to its previous state, and continued of fair power throughout; the pupils had been

Digitized by Google

closely contracted; her aspect had continued florid; and the respiration was only slightly stertorous. The chloroform and the towel were now laid aside, and the patient's bed was moved a short distance towards a window. Whilst this was being done, Mr. White (the house surgeon) who still kept his hand on the pulse, noticed that it suddenly began to get smaller and weaker, and that the countenance of the patient was becoming very pallid. Cold water was at once dashed on her face. In a few seconds, her pulse had become imperceptible; and on examining the pupils, they were found widely dilated. Artificial respiration by means of pressure on the abdomen was now commenced, the natural inspirations having become very slow, but not quite suspended. The stethoscope was applied over the heart, without any sounds being detected; the examination was, however, necessarily a hurried one. Under the direction of Mr. Clover, the resident medical officer, the artificial respiration was maintained, hot water was applied to the feet and thighs, and friction was made on the body of the patient. Galvanism was also had recourse to, one pole being applied over the region of the heart, and the other to the back of the neck. It is probable that not more than four minutes had elapsed between the cessation of the heart's action and the commencement of the use of this agent. The apparatus was in good order, and worked well. After the above means had been simultaneously continued for a few minutes, there were decided symptoms of improvement; the pupils again contracted, and, on the artificial respiration being temporarily suspended, the patient spontaneously made eight or nine interrupted attempts to breathe. These having ceased, Mr. Clover next performed laryngotomy, and artificial respiration was continued by means of a tube passed through the opening into the trachea. From this time forwards no hopeful indications occurred; the death-like pallor of the countenance increased; and the pupils again became widely dilated. After about three quarters of an hour, spent in unremitting exertions, it was judged useless to persevere further, as the patient was evidently quite dead.

Digitized by Google

Post-mortem examination, twenty-four hours after death.—Cadaveric rigidity well marked. Numerous discolorations in spots and patches scattered over the surface of the corpse.

Lungs congested, but not to a marked degree; crepitant in all parts.

Heart.—Right side moderately contracted; left, distended with fluid blood; the whole organ large, pale, flabby, and having on its surface a greater deposit of fat than natural. Weight, 10½ ounces. Its muscular structure, when cut across, was very noticeably soft and pale; it was very easily torn. Placed under the microscope, its fibres, more especially those of the right ventricle, were seen to be loaded with fat granules,—a condition which prevailed more or less in all parts, but to the greatest extent in those taken from the right ventricle. The valves and large vessels were healthy.

Blood dark in colour, and, with one exception, fluid in all parts; this exception relates to that which escaped when the root of the right lung was cut across, and which contained a few small and very soft coagula.

Spleen enlarged, and loaded with blood. Weight 12 ounces.

The rest of the abdominal organs, as also the brain, were carefully examined, but did not present any appearances worthy of note. With the exception of the kidneys, none of them showed any degree of congestion.

Remarks.—Dr. Quain observed that the mode of dying in this case clearly showed death to be the result of failure of the heart's action. It was equally clear that the failure occurred as the immediate result of the administration of chloroform. It was stated during the inquiry, that this agent had been administered in nearly 1500 cases in the hospital after precisely the same fashion, without a result like the present. We are, therefore, bound to seek for some peculiarity in the present case, which rendered it an exception. That peculiarity seems to exist in the morbid state of the heart's fibres. Experiments have shown that chloroform exerts a directly sedative action on the muscular fibres of the heart, an effect which must be greatly exaggerated where those fibres have lost much

Digitized by Google

of their organization and contractile power, as in fatty degeneration. But independently of any specific action of the drug, the presence of its vapour implies the absence, to a greater or less extent, of oxygen from the inspired air. The blood thereby, imperfectly arterialized, ceases to be an efficient stimulus to the heart; and the organ, already weak, becomes still more so; then its action finally stopping altogether, death by cardiac syncope is the result. Dr. Quain expressed his belief that much of the prejudice which had been excited against chloroform was due to the too-great boldness with which the freedom from danger of its administration was asserted, and to the readiness with which deaths under its influence were attributed to any but the right cause. No one could deny that an atmosphere of chloroform must kill as effectually as an atmosphere of carbonic acid; and it is not improbable that in certain of the fatal cases, a want of proper precaution has absolutely allowed death to occur from the respiration of such an atmosphere. Such, however, could not be the case in this instance, for neither was the quantity of chloroform inhaled, nor the method of using it, other than that made use of in hundreds of other cases. In fact, the explanation of the cause of death in this, as no doubt in like cases, must be sought for in the subject and not in the remedy. We are impressed then by the consideration of the present and similar cases, with the necessity of being fully alive to all the circumstances which may predispose the individual to receive an injurious impression from the inhalation of this valuable agent. Dr. Quain expressed his conviction that amongst these circumstances (and they are not few) there was none which demanded more careful consideration than that of Fatty Degeneration of the Heart. An agency, powerless over a healthy and vigorous organ, will be quite sufficient to overwhelm the feeble and tottering action of a heart thus diseased.

Dr. R. QUAIN, *5th of April*, 1853.

Digitized by Google

7.—*Fatty Degeneration of the Heart. Death by Rupture of the Left Ventricle.*

The heart was that of an aged female who had died suddenly whilst making some unusual exertion. Mr. Bennett, of the St. Giles's Infirmary, to whom Dr. Quain was indebted for the specimen, had made the post-mortem examination, but was unable to obtain any more information about her previous history, than that she had suffered from difficulty of breathing and cough. The cause of death was found to be copious hæmorrhage into the pericardium, from a rent in the left ventricle. This rent was nearly an inch in length, situated in the front wall of the left ventricle, and was extended from above, downwards. Its edges were jagged and irregular. The walls of the heart, which were much covered by fat, were soft, lacerable, and of a paler colour than natural. A microscopic examination showed the presence of fatty degeneration in the fibres of both ventricles. This change was most evident near the rupture, and the branch of the coronary artery leading to this point was ossified, and almost completely closed.

Dr. QUAIN, *5th of April*, 1853.

8.—*Fatty Degeneration of the Heart of a Child.*

The patient, a female aged ten years, suffered from fever when four years old, and never regained her spirits; moaning and crying at night, and "see-sawing" in her chair during the day, as though affected with chorea. At eight years of age she had scarlatina, not attended or followed by dropsy. Five months ago she had rheumatism, but no affection of the heart was suspected till five weeks before her death, when she had cough and dyspnœa, with great debility. When I first saw her three weeks before her death, she was pale and livid, mucous rattles were heard at base of both lungs, extensive dulness over heart; loud bellows murmur, with first sound; feeble, rapid, and irregular pulse; urgent dyspnœa; no anasarca, a symptom that did not come on till a week afterwards, or a fortnight before death. Urine never albuminous.

Digitized by Google

Post-mortem examination, after 96 hours.—Decomposition had begun. Considerable effusion into chest and abdomen: lungs congested but healthy, as was also the liver. About an ounce of serum in pericardium. Heart dilated and hypertrophied; no marks of inflammation of either ventricle; but the lining membrane of the left auricle was opaque and much thickened, and the edges of the mitral valves on the auricular surface were fringed with bead-like projections. The whole exterior surface of the heart, but particularly on each side the septum, had a granular appearance from minute whitish lines perpendicular to it, which, under the microscope, exhibited a fatty condition of the muscular fibres, and a similar appearance was remarked in the substance of the large columns of the left ventricle. Kidneys healthy.

The marks of endocarditis in this case were so slight, that we can scarcely attribute the fatty condition to the effect of inflammation of the mitral valve and auricular endocardium. It seems more rational to conclude that the fatty condition began with the fever, and was the cause of the continued ill-health up to the time of the rheumatic attack, which, acting on the heart already weakened, caused its rapid dilatation and the consequent fatal results. The state of decomposition of the body prevented an examination of the condition of the blood. If the affection that followed the fever was St. Vitus's dance, this case affords another instance of the proneness of patients affected with chorea to suffer from disease of the heart.

Dr. Ogier Ward, *3rd of May*, 1853.

9.—*Malformation of the Heart. Complete Closure of the Orifice of the Pulmonary Artery. Very small Foramen Ovale. Cyanosis.*

J. W. G., a male child, then aged about eight weeks, was first seen by Dr. Hare on the 3rd of August, 1852, in consequence of a slight amount of bronchitis. The child was born at the full period of gestation; at the time of birth nothing peculiar in his appearance was noticed, but afterwards the nurse frequently remarked that his feet and hands were colder

Digitized by Google

than they ought to be, and the child was altogether of a more dusky colour than natural: when he coughed, or when moved much in the nurse's arms, he became distinctly blue. On the 10th of August the child was thin, without being much emaciated; his complexion was dusky, without being absolutely blue: he appeared sleepy, as was stated to be generally the case.

There was nothing unusual in the form of the chest; no abnormal bulging of the præcordial region. At a quarter of an inch to the left of the left nipple, a slight purring tremor was detected; impulse was about natural; at the apex of the heart a distinct, moderately loud, hush-blowing (not rasping or filing) murmur was heard with the first sound; less distinct on approaching the base; none with the second sound; the murmur was heard in left interscapular region, but not very distinctly. There were then no rhonchi in either lung (there had been slight sonorous rhonchi on the 3rd of August); puerile respiration was very distinct.

The child was again seen in October, but not from that time till after his death, which took place on the 9th of March, when he was nine months old. He was stated to have got gradually thinner, but the colour of the skin had remained about the same as before; that is, he was always rather livid, but sometimes more so than at others, especially if he coughed or cried much: the livid colour was never, however, very intense; most so about feet. He always took the breast well: never had any convulsions. The day before his death, the child appeared rather weaker, but nothing else unusual in his appearance was observed. About six A.M. of the 9th, the mother raised up the child to put him to the breast; his head fell back; there was a little rattling in the throat; no struggling; and the child died.

Autopsy, 27½ hours after death.—Scarcely any cadaveric rigidity; the body and limbs considerably emaciated. General colour of skin rather dusky, but not absolutely cyanotic: no œdema.

Liver projected about one inch below the costal cartilages, and its surface was firmly adherent to the parietal peritoneum by old adhesions, one of which, about the size of a shilling, was situated about the middle of the upper surface of the right

Digitized by Google

lobe, and two others—smaller ones—were on the surface of the left lobe. No adhesions between any of the coils of intestine. The liver itself was rather large, and of a more purple tint than natural: on making an incision into it, in situ, a very large quantity of very fluid blood escaped.

Chest rather narrow for a child of nine months old, but chiefly so at its lower part. Pleura quite healthy. Each lung floated readily in water: the right one was quite healthy; the left one rather congested posteriorly at the base. On first removing the sternum, very little of left lung was visible, in consequence of the large portion of the anterior part of the chest occupied by the heart.

No adhesion of pericardium either externally or internally: in it there were from 1 to 2 drachms of fluid. When the pericardium was opened, the large size of the right auricle at once attracted attention: it was distended with blood, and appeared to form, as it were, a loose cap over the base of the heart: it measured 2 inches in length, from the orifice of the vena cava inferior to the extremity of the auricula. The foramen ovale was open, but only to the $\frac{1}{16}$th of an inch in breadth, by about the $\frac{1}{10}$th or $\frac{1}{12}$th of an inch in length; the opening was direct, not oblique; there was no other opening between the auricles. The right auriculo-ventricular orifice, as seen from above, formed a short oval ($\frac{3}{16}$ths of an inch by rather more than $\frac{1}{8}$th of an inch). On cutting into the right ventricle, it was found that the columnæ carneæ were fused almost into one, so that this part of the right side of the heart presented nearly a solid mass. Towards the base of the ventricle, however, there were the free ends of two or three small columnæ carneæ, and some rudimentary tricuspid valves, in a cavity or space of a somewhat triangular form, but so small that it would only hold a moderate sized pea: one corner of this small triangular right ventricle extended in the direction of the pulmonary artery. The orifice of this vessel, however, was entirely closed, though it measured rather more than an inch in circumference at its middle: at its ventricular extremity, it ended in a cul-de-sac, where there were some minute folds, probably representing the pulmonary valves; at its opposite extremity it terminated in

Digitized by Google

the ductus arteriosus, which opened into the aorta by an orifice which would admit a crow-quill. The pulmonary artery divided normally into right and left pulmonary arteries.

The left auricle was only $\frac{3}{4}$ths of an inch in its longest diameter: its musculi pectinati were very much less marked than those of the right auricle. The left ventricle presented nothing peculiar, except that its walls were very thick, measuring at the thickest part nearly half an inch. The septum ventriculorum was perfect. The aortic opening natural; its circumference (at level of upper border of valves) exactly one inch: circumference of aorta just before giving off the large vessels was $1\frac{1}{8}$th of an inch; aortic valves normal.

Dr. Hare remarked, that although, amongst cases of malformation of the heart, it is not very rare to meet with instances of more or less complete closure of the pulmonary artery, yet this specimen was almost unique in presenting, together with complete closure of the pulmonary artery, so very small an aperture of communication between the right and left sides of the heart, as that described. The septum ventriculorum being perfect, and there being no other mode of communication, all the blood from the right side of the heart must have passed through the small foramen ovale into the left auricle, and from thence into the left ventricle, and into the commencement of the aorta. At this part of its course, the current must have been divided into two parts; the one would pass along the rest of the aorta, &c., to supply the body generally; the other would enter the ductus arteriosus (going in the opposite direction to the course taken by the blood during fœtal life), and thus reach the pervious portion of the pulmonary artery, from whence it would reach the lungs for aëration, and so become mixed, in the left auricle, with that portion of the blood which had passed through the general system, and returned by the right auricle and foramen ovale into the left auricle.

Another remarkable circumstance in this case was, that the murmur was synchronous with the first sound of the heart, and that it was heard more distinctly at the apex than at the base of the heart. These facts were noted on two several

Digitized by Google

occasions; and on one occasion the negative observation that there was "no murmur with second sound," was likewise recorded. Supposing the murmur to have originated at the foramen ovale, it seems most probable that it would have occurred synchronously with the second sound, and that it would have been heard most distinctly at the base; and supposing that it originated at the ductus arteriosus, even then, though it would have been synchronous with the first sound, analogy would lead to the supposition that its point of greatest intensity would have been at the base, and not at the apex of the heart. Dr. HARE, *15th of March*, 1853.

10.—*On the Mode of Closure of the Foramen Ovale after Birth.*

Dr. Peacock exhibited a series of preparations intended to illustrate the mode of closure of the foramen ovale after birth. He ascribed the closure to the operation of the following causes:—

1st. To the drawing up of the fold of the valve above the isthmus foraminis ovalis, by the action of muscular fibres derived from the fasciculi, forming the walls of the left auricle, and which follow the course of the cornua of the valve to be expanded on the left side of the fold.

2nd. To the approximation of the cornua at the point of their insertion into the fold, by the action of muscular or elastic fibres extending between the two cornua, and having a course parallel to the upper edge of the valve.

3rd. To the general diminution in the size of the opening in the septum, by the contraction of the muscular columns forming its boundaries. These changes he supposed to be brought about by the establishment of the pulmonary circulation, by which aërated blood entered the left auricle and the left vessels of the heart. The traction exerted by the expansion of the auricle, which follows birth, might also probably conduce to their contraction, so as to tend both to draw up the valve and diminish the size of the opening.

1st. The muscular fibres by which the fold of the valve is drawn up and readily detectable in children, a few weeks old,

Digitized by Google

or in young persons, and even, sometimes, in persons in advanced life. They cannot be made out in the fœtus. The fibres pass obliquely down from the walls of the left auricle, fall in the direction of the cornua of the valve to be expanded upon its left side, immediately beneath the endocardium, and those from the opposite sides interlace. The drawings exhibit the fibres as seen after the removal of the endocardium in a boy eleven years of age, (Plate II, Fig. C,), and a man of twenty-four, (Plate II, Fig. D.). The dotted line in the last indicates the size and position of the fossa foraminis ovalis.

2nd. The approximation of the cornua may be due to the muscular fibres which follow the course of the crescentic edge of the valve, or it may be accomplished by muscular or elastic fibres passing between the cornua, as figured by Senac.

3rd. The dimunition of the size of the aperture must necessarily result from the contraction of the interlacing muscular fasciculi which form its boundaries.

In ascribing the closure of the aperture to the operation of these causes, Dr. Peacock said he was only recurring to the views of Senac, though the latter writer attached probably too important a part to the fibres which he observed in the valve itself, and regarded as muscular; while he overlooked the fasciculi, which were derived from the walls of the auricle and were undoubtedly muscular. Yet these fibres must be the most important means by which the fold of the valve is drawn up. The effect of contraction of the muscular boundaries of the foramen in diminishing the size of the opening, seemed to have been fully understood by Senac. The explanation which thus refers the closure of the orifice to muscular action, is not only more in accordance with the anatomy of the part, but affords a more satisfactory explanation of the various deviations from the natural state, than that which ascribes the elevation of the valve, to the establishment of an equilibrium of pressure in the two auricles, by which it is floated up and retained in apposition with the isthmus.

It is well known that when the foramen ovale remains unclosed, there is generally a contracted state of the pulmonary

Digitized by Google

Digitized by Google

DESCRIPTION OF PLATE II.

FIGS. A and B illustrate Dr. C. Black's case of hydatids from the left lung, subsequently to the occurrence of typhoid fever, complicated with double pneumonia. Page 44.

FIG. A.

1. Epithelial patches.
2. Mucus corpuscles.
3. Exudation cells.
4. Plastic cells.
5. Pus cells.
6. Exudation mass, showing traces of cell-development.
7. Portion of lymphatic vessel.
8. Portion of a nerve-tube.
9. Bronchial cast.

FIG. B.

1. Exudation mass in the process of cell-development.
2. Pus cells.
3. Exudation cells.
4. Mucus corpuscles.
5. Basement patch.
6. Plastic cells.

FIGS. C, D, E, F illustrate Dr. Peacock's observations on the mode of closure of the foramen ovale after birth. Page 85.

C. Drawing from a preparation removed from a boy 11 years of age. The valve is seen deprived of the endocardium, so as to show the muscular fibres situated on its left side.

D. Drawing of a preparation removed from a man 24 years of age. In this specimen, also, the endocardium has been removed, and the valve is seen from the left side; the dotted oval indicates the extent of the fossa foraminis ovalis, as seen in the right auricle.

E. Drawing of a preparation from an infant 8 weeks old, in which, as in the former examples, the endocardium has been removed, so as to show the muscular fibres. The dotted space indicates the extent of the fossa; and the line marks the point from which the demonstration F was obtained.

F. A portion of the muscular fibre, taken from the points marked in E, magnified 400 diameters. The muscular fibre, though altered from having been some time in spirit, is still sufficiently characteristic.

Digitized by Google

Fig. A.

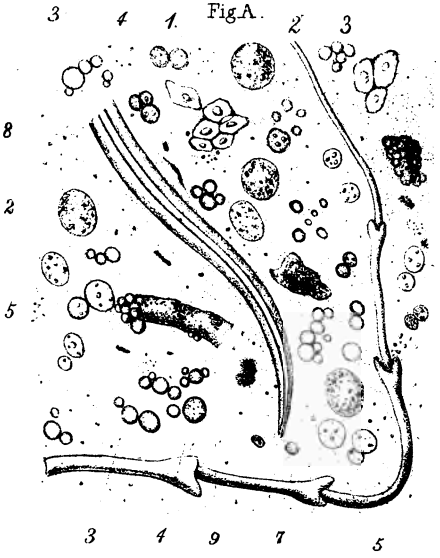

Fig. B.



Dr Black del.

Fig. C.

Fig. E.

Fig. D.

Fig. F.

Digitized by Google

UNIV OF MICH

Tuffen West, del. et lith

Ford & West Imp. 54 Hatton Garden

Digitized by Google

orifice, or some other source of obstruction to the free flow of blood through the lungs; and the unequal pressure of the blood in the two auricles is regarded as the cause of the patency of the aperture. This explanation, however, will not apply in all cases, for the foramen ovale is sometimes found entirely closed, in cases in which, from the co-existent malformation and the symptoms present from birth, it is evident that the right cavities of the heart must have been at all times more engorged than the left. Cases of this kind admit, however, of a satisfactory explanation, in the view which ascribes the closure of the foramen to muscular action, called into operation by the entrance of arterialized blood into the left auricle and vessels of the heart.

These remarks do not, however, apply to the process by which the valve, after having been drawn up above the level of the isthmus, becomes adherent to it, so as entirely to cut off all communication between the two auricles. For adhesion to take place, it is necessary that the valve should be retained in apposition with the isthmus, and this will require that the pressure in the auricles should be equalized. It is probable that the slow establishment of the pulmonary circulation after birth, is the cause of adhesion between the valve and isthmus not being effected in many cases, and hence the oblique aperture, which, in adults, so frequently exists between the auricles.

Dr. Peacock, 19*th of October*, 1852.

11.—*Case of a Heart with a single Ventricle, with Observations on the Production of Cyanosis.*

Charles Burrell, ten weeks old, was brought to me on the 30th of November, 1852, with the following history.

He was a healthy child at birth, fat and well-formed, but had fallen away considerably since. He was subject to attacks of vomiting, for which he was taken away from the breast. At the present time he sleeps badly, but is disturbed by paroxysms of difficult breathing. When quiet, the surface is warm, but during dyspnœa the extremities become cold. The surface of

Digitized by Google

the body, lips, and hands, are pale, and of the usual natural tint.

When seen, one of the paroxysms of dyspnœa happened to be passing off. The pulse was full and rapid. The abdomen was tympanitic below the umbilicus. The heart's pulsations were strong and tumultuous. The percussion-sound over the præcordial region was dull. There was a superficial bellows and whizzing sound at the sternum, near the third costal cartilage. Over the apex of the heart loud bruits were heard, of a rapid and indistinct character. The stroke-sound throughout the chest was resonant, and the respiration-sound was scarcely audible.

He lived nine weeks after the first visit, but I did not see him again. It appeared that he had been placed in bed at night as well as usual, and was found dead in the morning.

The body was examined fifty hours after death.

The Lungs were congested, not collapsing on opening the chest. They were emphysematous in large patches over the front surface. In the right middle lobe there was a nodule of pulmonary tissue, forming, as it were, a small lobe, which was also greatly emphysematous. On section, blood flowed out freely.

The Pericardium contained about half an ounce of light-coloured yellow fluid. The sac was strictly normal in appearance.

The Heart was obviously much over the usual size for so young a subject, and in cutting into what was supposed to be the left ventricle, only one cavity was found to exist. It was quite empty. The columnæ carneæ of the left side of the cavity were larger than those on its right. The interior of the heart did not present the slightest rudiments of a septum. The pulmonary artery and the aorta arose in their normal positions, the former almost double its usual size, the latter was, by comparison, much smaller than natural. The semilunar valves of the pulmonary artery were large, thickened, and irregular, the centre one being much the largest, but apparently competent. The aortic valves were normal in appear-

Digitized by Google

ance. The mitral valve was large and patulous, allowing the finger to pass readily into the auricle. The tricuspid was normal.

The Auricles were very large, and their appendices much increased in size. The lining membrane was much thickened. The foramen ovale was large and open, and the valve-like fold was much thicker than natural.

After the heart and vessels had been removed, I found a considerable artery given off from the left pulmonary branch. It arose higher than the usual place of origin of the ductus arteriosus; was more in front of the vessel; and descended. Its termination was not determined, owing to the parts having been removed hastily; but the ductus arteriosus was wanting in its natural situation.

The Liver was enlarged; extending to the umbilicus: occupying, in short, the upper half of the abdomen. The ductus venosus was obliterated. The portal system was generally congested, and the mesenteric glands were tumid.

The Kidneys were congested and dark, and presented the usual lobulated appearance observed at this period of life. The supra-renal capsules were also well seen; and on section, presented a striated appearance.

Remarks.—Of this rare kind of malformation, Lawrence refers to two cases only; one of which is given in Kreysig ("Die Krankheiten des Herzens"); another is mentioned in Tiedemann ("Zoologie," part i. page 177), and a third is found in Hufeland's "Journal," quoted by Dr. Norman Cheevers. The two first suffered from cyanosis, but no mention is made of this appearance in the last.

A patulous state of the foramen ovale was generally considered to give rise to cyanosis; and in those cases where such a communication was discovered to exist after death, without the usual blue discoloration, the seeming discrepancy was reconciled by assuming that, although the foramen was open, yet its valve-like aperture and the forces of the two sides of the heart being so exactly balanced, had tended to prevent the admixture of

Digitized by Google

venous and arterial blood. I think we are justified in assuming that this state sometimes exists.

In the present case of a single ventricle, this contingency was removed, and yet no cyanosis resulted. This may be explained by the supposition of the disease requiring for its manifestation an additional disturbance of the circulation at the lungs, as in bronchitis, pertussis, &c., or at the heart, as contracted pulmonary artery, &c.

In exemplification of this, I may mention the following case: At Paris, a boy twelve years of age enjoyed, with the exception of shortness of breathing, tolerable health, the dyspnœa being increased on exertion according to degree, so as even to produce fainting. He, I believe, fell into the river; on his being removed home, bronchitis ensued, and he died with all the characteristics of a well-marked case of cyanosis, although, before this accident, and the consequent bronchitis, he was of natural appearance. On examination, the foramen ovale was found patulous, the lungs greatly congested, and too much charged with blood to perform the duty of aëration effectually.

This also appears to have been so, in a case described by Dr. Peacock*:—"This child was livid at birth, but acquired a more natural colour afterwards. When chilled, or suffering from catarrhal affection, she became livid in the face, and had hurried and difficult breathing." In this case the right ventricle was divided by a septum which permitted of a communication with the aorta and pulmonary arteries.

Dr. Stillé, in an able memoir in the "American Journal of Medical Science," lays down the following propositions:—

I. That cyanosis may exist without admixture of blood.

II. That there is not always a proportion between cyanosis and the degree in which the blood is mixed.

III. That complete admixture of the blood may take place without cyanosis.

IV. That cyanosis depends on congestion of the general venous system from obstruction in the right side of the heart,

* "London and Edinburgh Journal," p. 644. 1847.

Digitized by Google

or in the pulmonary artery, impeding the return of its blood to the lungs.

I consider that the first proposition has been already borne out by numerous cases mentioned by different authors.*

Mr. Ebenezer Smith (in the Society's "Transactions," vol. i.) describes a case of cyanosis, in which the foramen ovale was perfectly closed, and had evidently been so for some time before birth. There was no inter-ventricular communication, the pulmonary artery large, the left auriculo-ventricular opening small, and left ventricle almost obliterated; aortic orifice very small, about two lines wide; mitral valve defective in structure, consisting only of two small bands without any curtain.

Cases which establish the second proposition, will be found in the works mentioned below,† and the third, which bears especially on our present case, is supported by numerous illustrations from MM. Fouquier, Breschet, and Farr.‡

Dr. Quain§ brought before the Society the case of a girl, aged eight years, in which two openings were found in the ventricular septum, and no cyanosis resulted.

A child is also mentioned, in Foundling Hospital of Paris, where the heart consisted of a single auricle and ventricle. He suffered from cough and dyspnœa, but there was no cyanosis. I think we are also justified in assuming that the cases given in "Hufeland's Journal," had no cyanosis. M. Bizot found the foramen ovale more or less open in 44 out of 155 subjects, in none of whom was there a trace of the blue discoloration of the skin.

Dr. G. O. Rees presented to the Pathological Society, in 1847, the heart of a child, in which the aortic was much smaller

* "Archives Gén. de Médicine," vol. viii. p. 594. Bouillaud, "Malad. du Cœur," Obs. lxxvii. p. 155. "Edin. Med. and Surg. Journal," vol. iii. p. 552. "Lond. Med. and Phys. Journal," vol. xiv. Mr. Le Gros Clark, Case in "Med. Clin. Trans.," vol. xxx. p. 113. 1847. Dr. Peacock, "Patholog. Reports," 1847.

† "Lond. Med. and Phys. Journal," New Series, vol. vi. p. 548. Guttrac, "Récherches sur la Cyanose," p. 44. Farr, "Patholog. Essay on Malfor. of Heart," p. 2.

‡ "Amer. Journal of Med. Science," p. 447. Oct. 1843.

§ "Transactions" of the Society, 1847.

Digitized by Google

than the pulmonic orifice, and there was no cyanosis. The ductus arteriosus continuing open, allowed the blood to pass from the pulmonary artery directly to the aorta, so that the blood distributed to the lower part of the body, must have been almost entirely venous.

We cannot, I think, fully accede to Dr. Stilles's fourth proposition, that obstruction to the pulmonary artery is never found without the concurrence of cyanosis. We may, I think, say, that this holds good only in those cases of congenital narrowing of this vessel, but not in those the result of endocarditis, &c.

Dr. Cheevers well observes, that "for the establishment of that generally dilated condition of the entire venous system which attends cyanosis, the obstruction to the circulation must have been present either at or before birth, when the capillary vessels are naturally more capacious than they are in the adult, or it must become confirmed previously to the full development of the body, while the entire vascular system is pliant and dilatable, and is still capable of readily adapting itself to permanent changes in the circulation."

Cases which bear upon the point will be found recorded by Dr. Peacock and others.*

M. Le Gros Clark† relates a case where, instead of the pulmonary artery arising from the right ventricle, its place presented two small circular apertures. The upper one communicated with the aorta, the lower opened into a small but thick muscular sac, which measured an inch in its largest diameter, and gave origin to the pulmonary artery.

M. Guitrac, who is the most strenuous supporter of the doctrine of the mixture of the blood as the cause of cyanosis, analyzed fifty-three cases, and among them found obstruction of the pulmonary orifice in twenty-two, and five pulmonary arteries obliterated. Other authors have even found a much larger proportion.

* "Med. Chir. Trans.," vol. xxx. p. 131, 1847. "Lond. and Edin. Monthly Journal," vol. vii. p. 644. Mr. Ebenezer Smith, "Transactions" of the Society, vol. i.

† "Med. Chir. Trans.," vol. xxx.

Digitized by Google

Of fifteen cases collected by Bouillaud, twelve presented valvular disease, in ten of which there was contraction of the orifice. M. Louis' comparison in nineteen cases of congenital malformation are as follows:—"Contraction of orifice of pulmonary artery in ten, of the aorta in only one—dilatation of the right auricle in eighteen, five of which were with hypertrophy, and two with attenuated parietes—right ventricle simply dilated in five, simply hypertrophied in six—dilated and hypertrophied in four. Left auricle dilated in eight, hypertrophied in three. Left ventricle dilated in four—hypertrophied in two. Triscuspid valve more frequently diseased than the mitral, but neither often."—"Cyclopædia of Medicine," vol. iii.

In sixty-two cases of cyanosis analyzed by Dr. Stillé, in fifty-three the pulmonary artery was either contracted, obstructed, or impervious: the remaining nine are satisfactorily explained; showing abnormal states of the heart or arteries, and so tending, although more slowly, yet no less surely, to cause obstruction to the capillaries. Our present case, and the extracts I have given of others, bear out the views of Morgagni, and those more recently of MM. Louis, Bertin, and Bouillaud, who consider that the mixture of arterial and venous blood has comparatively little to do with the purple hue of the complexion, but that more depends on coexistent lesions, capable of obstructing the course of the circulation, and so causing accumulation of venous blood in the capillaries.

We may remark in the present case, that the absence of the blue condition of the surface may be accounted for by the large size of the pulmonary artery; thus affording a ready transit of the blood to the lungs for aëration, and thus tending to render the circulating fluid much less venous in the systemic vessels than otherwise would have been the case, had the usual contraction of the pulmonary artery prevailed. But assuming the existence of a ductus arteriosus, in the branch given off by the pulmonary artery on the left side, (see *ante*) we may account for the systemic circulation being properly carried on by so small an aorta.

M. Louis considers that suffocative paroxysms, at periodical, or at least at very short intervals, often followed by faintness, are the most usual symptoms of the patulous state of

Digitized by Google

the foramen ovale; and the two cases I have seen fully bear out this view.

As I do not find the particulars of the case of Mr. D—— given in Kreysig, in any of our standard works, I give it at length, as a contrast to our present case. In Mr. D. there was a circulation of mixed blood, with obstructive disease in the pulmonary artery, and cyanosis. In our case there was a similar state of the circulating fluid, but no obstructive disease, and no cyanosis.

In the Museum of the Medical Faculty at Warsaw, the heart of Mr. D., who died in his 22nd year, of cyanosis, is preserved; and exhibits the following peculiar structure. The heart consists of two well-formed auricles, which intercommunicate by an orifice of two lines in diameter, in the valve of the foramen ovale. It also has one ventricle, into which the lower margin of the septum of the auricles projects freely. In this single ventricle, there are posteriorly two venous, and anteriorly two arterial openings. The semilunar valves of the pulmonary artery are imperfect, small, and without the nodules of Morgagni. The formation and course of the pulmonary artery is normal, but the ductus arteriosus is completely open. The aorta arises by a great orifice, and its semilunar valves are more perfectly formed than those of the pulmonary artery. The tricuspid and mitral valves are properly developed. The father of this gentleman relates that he frequently dived and remained under water for half-an-hour and more at a time; the first time causing great alarm to his family.

Dr. Hale, 18*th of January*, 1853.

Report on the preceeding Case.—In reference to the specimen upon which I was requested to report at the last meeting of the society, I have little to add to the careful notes of Dr. Hale. The ventricle is single, and presents no appearance of any rudimentary septum. It gives origin to two distinct vessels, the pulmonary artery and aorta, and is in communication with two auricles. The pulmonary artery is considerably larger than the aorta, having, at its origin, a circumference of sixteen French lines, while the latter is only twelve lines in circumference. The pulmonary valves are of very unequal size, one

Digitized by Google

having a width of four lines, a second of five, and the third of seven lines. The aortic valves are three in number, and are of equal size. The septum of the auricles is complete, but the foramen ovale is large, and is very imperfectly closed by the valve. The right and left auricles communicate with the corresponding sides of the single ventricle, by valves, which have the usual tricuspid and mitral form. There is a small Eustachian valve. The condition of the ductus arteriosus cannot be ascertained.

Of cases of malformation similar to this, in which the heart consists of two auricles and one ventricle, there exist various examples recorded by Fleischman, Chemineau, Tiedemann, Otto, and Kreysig. Dr. Cheevers has also quoted from the "Lancet," a case published in "Hufeland's Journal." Dr. Crisp has described a specimen in our own "Transactions;" and I find a preparation of a similar kind in the Museum of St. Thomas's Hospital. In most of these cases there exist two vessels arising from the ventricle, an aorta and pulmonary artery; but generally the latter vessel is, unlike its condition in Dr. Hale's case, more or less contracted; and occasionally it is entirely obliterated. In the specimen in St. Thomas's Museum, the pulmonary artery is much contracted, and arises from the posterior side of the ventricle, while the aorta arises in front; the orifices of the two vessels are separated by a muscular mass, and a band of muscle passes down the back of the ventricle, indicating a rudimentary septum. There is also no communication with the right auricle and ventricle, but the former cavity opens freely into the left auricle, and must have transmitted its blood to the single ventricle.

The pathological effects of malformations of this description vary considerably, according to the condition of the pulmonary orifice. When that opening is much contracted or wholly impervious, cyanosis is a constant result; but, when the aperture is free, the blue discoloration may be partially or wholly absent. Dr. Hales's case thus corresponds with others which are on record; and the most interesting circumstance connected with it, is, the confirmation which it affords to the correctness of the view advanced by Morgagni, and ably advocated by Louis, of the dependence of cyanosis, not on the simple intermixture

Digitized by Google

of the two currents of blood, but upon congestion of the venous system. Did the intermixture give rise to the cyanosis, that symptom must, in this case, have been well marked; but, if cyanosis depends on venous congestion, the large size of the pulmonary artery, and the free outlet thus afforded to the blood from the right ventricle, sufficiently explains its not having been observed.

The viability of children presenting similar malformations to this, also depends much on the state of the pulmonary artery. When that vessel is greatly contracted or entirely obliterated, the conformation approaches to that more aggravated form, in which there is only one auricle, one ventricle, and one vessel given off with the systemic and pulmonary arteries; and few children so born survive for any lengthened period: when, however, there are two distinct vessels, and more or less completely divided auricles, life may be much prolonged. The boy, whose case is mentioned by Tiedemann, lived to the age of eleven, and the subject of the case quoted from "Hufeland's Journal," to the age of twenty-four. The specimen in St. Thomas's Museum was obtained in the dissecting-room, and has no history attached to it; but the subject could scarcely have been less than ten or twelve years of age.

Dr. Peacock, 1*st of February*, 1853.

12.—*Malformations of the Aortic Valves in an Infant. Sudden Death. Fatty Degeneration* (?)

W. W., aged six months, was prematurely born about the eighth month of gestation, and was then very small, scarcely larger than a middle-sized doll. After the first week, he suffered constantly from diarrhœa, the stools being frequently green and curdled, at other times white and watery, or like semi-digested milk. Occasionally he vomited, but not often. He was never quiet except when at the breast: he was thus constantly occupied; and took no artificial food. When four months old, he became so much emaciated, and was so frequently purged, notwithstanding every effort to bring about a more healthy action, that he was daily expected to die. During the following (fifth) month he rallied, and became better than he had been previously.

Digitized by Google

The child continued much in this state, when being about six months old, the mother one morning found him dead by her side, she having fed and spoken to him about two hours previously.

Post-mortem.—The body was very small and emaciated, weighing about six pounds: certainly not more. General appearance, unusually pale. Scarcely any purple discoloration from post-mortem gravitation, upon the depending parts; no signs of violence could be found. The bones of the legs were curved, and appeared to have but little earthy matter in their composition. The bones of the scalp, the clavicles, and ribs, were in a like condition; they were but little more than cartilage. Upon removing the scalp, the dura mater was found to be firmly adherent along the course of the longitudinal sinus and the two fontanelles, which latter were perfectly open. The external surface of the brain was more than usually vascular The brain and cerebellum were healthy. Not any more fluid in the ventricles, nor at the base, than is usually found in healthy brains.

Upon removing the sternum, the viscera appeared generally more pallid than is usual.

The pericardium did not contain any fluid; and the heart, which was free from adhesion, was small, scarcely larger than a good-sized walnut. The right side flaccid and small; the left side firmer, harder, and larger than usual, especially the ventricle. Upon opening the right auricle it was found perfectly free from coagula; the same may be said of the right ventricle. The left auricle was also empty. The left ventricle did not contain a portion of either coagula or blood.

The thymus gland was large and healthy. The lungs were healthy, but paler than usual. The upper lobe of the left lung contained more post-mortem congestion than any other part.

Abdomen.—The same general pallor prevailed throughout the entire viscera of this cavity. The stomach and intestines were milk-white. The liver healthy, and about the natural size. The gall-bladder very small and healthy, without a vestige of bile, nor could the least tinge of bile be discovered in either

Digitized by Google

the duodenum or jejunum. Spleen and kidneys, with exception of the unusual pallor, appeared healthy. The stomach contained about three ounces of semi-curdled milk. The mucous surface was entire, and perfectly colourless. The duodenum, jejunum, ileum, and colon contained a large quantity of semi-digested chyme without colour. A very small portion only of fæcal matter, of a pale yellow colour, was found near the cæcum, and at the extremity of the descending colon. The mucous surface was entire throughout, and perfectly white and colourless. The mesenteric glands were enlarged, and many were in a state of softening. Scarcely a vestige of fat could be found in any part. The muscular structures were very pale and flabby.

There were found, on further examination, but two aortic valves; and their arrangement is thus described by Dr. Peacock, who kindly examined the heart. He writes: "The valves have evidently been originally three in number, and the division of one into two is still marked, though much less distinctly than usual. The larger valve measures $5\frac{1}{2}$ French lines in width; and, from both the coronary arteries arising behind it, must represent the coalesced right and left valves. The smaller or posterior segment measures $3\frac{1}{2}$ French lines. There is some, but not much, thickening of the united valves, and the mitral valve also presents nodular growths on the auricular aspect."

Dr. Peacock further observes: "I regard the case as presenting conclusive evidence of a defect in the number of the aortic semilunar valves, caused by the fusion of two of the segments; the atrophy of the septum so produced occurring during fœtal existence, and, I think, most probably, at an early period of fœtal life."

Dr. Quain observed that this case presented two points of considerable interest; one, the cause of the child's death; the other, the nature and origin of the malformation of the valves. He had seen more than one case in which, with a like malformation of the valves, sudden death had occurred. It is not difficult to conceive that, with such a malformation of the valves, an embarrassment and disturbance of the action of

Digitized by Google

the heart, from which it was unable to recover itself, might occur; and death thus take place. Moreover, in this case, coincident with the ill-nourished body, co-existed a granular if not an absolutely fatty state of the heart's fibres,—a condition in itself almost sufficient to account for the suddenness of the death.

In reference to the nature of the malformation, Dr. Quain expressed a hope of being able, on a future occasion, to bring forward some facts illustrative of the mode of its occurrence, in connexion with the plan on which these valves are developed.

DR. R. QUAIN, *5th of April*, 1853.

13.—*Diseased Aortic Valves with Fibrinous Deposits.*

The specimen was removed from a young man, aged eighteen, who had never been subject to any illness of sufficient importance to require medical advice, and had been quite free from any rheumatic or gouty ailment. During the three months preceding his death, he had occasionally suffered from a slight pain in the region of the heart, and once felt a slight difficulty in breathing after walking up a hill. When in bed on the morning of the 4th instant, after a sharp attack of præcordial pain, he suddenly died without any convulsive movement. The heart was found large, weighing 14½ ounces, all its walls being nearly proportionately hypertrophied; the left ventricle measuring at its base an inch in thickness, and its cavity enlarged. The aorta, on being opened at its origin, showed its valves much diseased, and thickened from extensive rough, fibrous, and calcareous deposits. The union of attachment between the right and posterior valves, with the aorta, was in a great measure broken down, the attached part being nearly half an inch below the normal point; the aortic surface was so perfectly smooth as to render it questionable if the attachment had ever been perfect—(if so, the separation must have been at a very distant period); the right valve was contracted, and the posterior proportionately enlarged; this valve from the weight of deposit on its free border, had become retroverted and attached

Digitized by Google

to the endocardial lining of the ventricles, by fibrous adhesion, a band, a quarter of an inch in length, rendering the valve almost immovable; the anterior valve, although free, had a slight deposit on its free border. The liver, kidneys, and spleen were much enlarged—the latter to double its usual size; its cut surface presented no deposits.

Mr. Obre, *7th of December*, 1852.

14.—*Atheromatous Deposit, and Rupture of one valve of the Aorta. Congenital Union of two of the valves.*

This specimen was taken from a man aged twenty-six, who, for eight months previously to his death, had suffered from œdema, ascites, hydrothorax, and hydropericardium. The urine during life contained some blood-corpuscles and a corresponding amount of albumen with fibrinous casts. The kidneys were found enlarged, soft, and œdematous; the left weighing 9 ounces and 2 drachms, the right 8 ounces and 2½ drachms. They contained no morbid deposit; and the microscope exhibited no marked deviation from the normal standard, beyond the tubes being choked up with epithelium.

About thirty hours before his death extreme dyspnœa and distress suddenly supervened; the beat of the heart and arteries was almost imperceptible, and extreme pallor spread over the lips. Some relief ensued temporarily at short intervals until death closed the scene. The left ventricle of the heart was found hypertrophied and dilated, but no valvular affection was discovered except in the aorta.

Here two of the valves were found entirely adherent to one another, so as to form a single pouch, slightly divided by an elevated ridge, corresponding to the former separation. The attachment of the common union of the valves to the aorta was somewhat lower than the other points of attachment of the two valves. The single valve presented a larger pouch than normal, and its capacity appeared even larger than that of the conjoined valves.

Atheromatous deposit was interposed between the membra-

Digitized by Google

nous folds forming the valves, which under the microscope presented a fibrous structure, disposed in irregular laminæ, over which much oil was scattered, as if the former were undergoing a gradual conversion into fatty matter. There was no cholesterin; but some gritty particles contained in the atheroma, from their behaviour with muriatic acid, appeared to be composed of carbonate of lime. The acid caused an evolution of gas, leaving a fibrous substratum. One of the adherent valves presented evidence of extensive laceration from the free edge inwards, to which probably the symptoms immediately preceding death might be attributed. In the portion of the aorta attached to the preparation no atheroma was visible, and the origin of the coronary artery was healthy.

The specimen was transmitted to Dr. Sieveking, by Dr. Weber, the resident physician of the German Hospital. It is instructive, as illustrating the congenital union of two valves of the aorta, and the tendency that this malformation induces of secondary lesions, such as that described.

Dr. Sieveking, 18*th of January*, 1853.

15.—*Malformed Aortic Valves.*

This specimen was removed from an infant six weeks old. The child had not shown any indication of disease previously to death, which took place suddenly in the street; the nurse who carried the infant, with its face partly covered, observed it to turn pale, as if fainting, and the death followed immediately, without any convulsive movement. No morbid appearance was observed in any of the organs. The heart was comparatively empty of blood, the right side particularly so. The aortic semilunar valves were but two in number, and of great size. From the position of the origins of the coronary arteries they indicated the valves to be the right and left. From their equality of size, and the absence of any indication of original division, it must be assumed that their fusion took place at a very early period of fœtal life.

One of the valves having been accidentally cut in opening the heart, prevented its precise condition as to competency in

Digitized by Google

preventing the return of blood to the heart, being ascertained, which it is conjectured was not the case in this instance; thus producing the sudden death.

All the other valves of the heart were natural.

The valve of the foramen ovale afforded a good example of its muscular structure.

Mr. Obre, *3rd of May*, 1853.

16.—*Diseased Aortic Valves.*

The man in whom the diseased aortic valves were found, died suddenly, at fifty-six, after rising at night to get upon the close-stool. He had never suffered from difficulty of breathing or from dropsy, and complained of little beyond some slight pain in the precordial region after eating or exertion; he was, however, a nervous man, and his face continually bore an expression of anxiety: a double aortic murmur was always observed whenever he was examined, as also increased precordial dulness. The aortic valves were found thickened, and the orifice narrowed; the thoracic aorta presented signs of old inflammation, its internal membrane being elevated, and corrugated by deposits of an albuminous character; the orifices of the coronary arteries were surrounded, raised, and much contracted, by this deposit; the arteries themselves were perfectly healthy; the heart was much enlarged, weighing nineteen ounces; its muscular tissue was perfectly healthy. The vessels of the brain appeared unchanged in structure.

Dr. Markham, *18th of January*, 1853.

17.—*Three Specimens of Malformation by excess of the Pulmonary Sigmoid Valves.*

1. This was the heart of the subject from which the lungs described in the note* below, were removed. At the orifice

* *Recent Case of Tubercle and Cancer in the same Lungs.*—The man from whom the lungs were removed was nineteen years of age. Several

Digitized by Google

of the pulmonary artery were two sigmoid valves of equal and normal size and appearance, and one large valve, the attached border of which was imperfectly doubly-crescentic. A little to one side of the centre of the free border of this valve was a single, but very large corpus Aranti; from this body a septum proceeded, by which the space between the valve and the lining membrane of the aorta was divided into two compartments.

2. A heart anatomically identical with the above.

3. At the orifice of the pulmonary artery were three valves of nearly equal size. Between two of these valves there was interposed a fourth smaller valve. This fourth valve had its own corpus Aranti, towards which the fibrous tissue of the valve could be seen bending.

Dr. JENNER, *2nd of November*, 1852.

18.—*Diseased Mitral Valve.*

The specimen of mitral valve disease was found in the body of a woman about forty years old, who died, after a few days residence in St. Mary's Hospital, from the ordinary consequences resulting from a high degree of mechanical impediment to the passage of the blood through the heart, viz., interference with the respiratory function, general œdema, and effusion into the serous cavities. The valves were thickened, had coalesced, and formed a kind of truncated cone, which projected into the left ventricle: its orifice would barely admit the end of the little finger. The case proves the high degree of alteration of structure of the valves, with which life is, for a time at least, compatible.

Dr. MARKHAM, *18th of January*, 1853.

encephaloid growths were connected with the bones of the cranium. Masses of encephaloid cancer were seated in both lungs, and about the base of the heart. Some recently-deposited tubercles, grey and semi-transparent—were found in the apex of the left lung. The only cells existing in the tubercle were identical with those described by Lebert as tubercle corpuscles.

Digitized by Google

19.—*Contraction of the Mitral Orifice, with Diastolic Murmur.*

Ann C——, aged sixteen, a female servant, admitted into St. Mary's Hospital on the 30th of July, 1852, under Dr. Chambers's care, at Dr. Markham's request, under whose care she had been as an out-patient.

When eleven years old she had chorea, and at a later period an attack of rheumatic fever.

On admission she was suffering from an attack of bronchitis, together with frequent attacks of palpitation and shortness of breath on exertion; she had been prevented doing any work for three weeks. She was unable to lie in the prone position, had frequent cough, and expectorated a little frothy and tenacious mucus. The heart's action was unsteady, and there was heard a distinct diastolic murmur, which had been previously noticed by Dr. Markham, most distinctly over the apex, and so prolonged, that it occupied more than half the period of both sounds, the systole being very short, and occasionally accompanied by a murmur. With quiet and appropriate means the more urgent symptoms soon passed off. On the 7th of August the pulse was only forty-four, probably owing to six minims of tincture of digitalis, which was in the mixture she was taking at that time. The diastolic murmur was now very prolonged, and occupied very nearly the period of both sounds; on applying the hand over the apex, a rough, rubbing, trembling sensation was communicated to the fingers. She was seen by several, who all agreed as to its being a diastolic murmur, but not as to its origin.

She left the hospital on the 17th of September, and died suddenly on the 19th.

Post-mortem examination.—I was only allowed to examine the heart, in which putrefaction had commenced. Both its visceral and parietal pericardium appeared smooth and healthy. Heart itself large; right ventricle much dilated and walls thickened; valves healthy; left ventricle dilated, but not much thickening of walls. The mitral valve had the free borders of its two segments thickened and adherent, except a small slit-

Digitized by Google

like opening at its ventricular extremity; it was of a funnel shape. Aortic valves healthy.

Mr. J. W. Trotter, 1*st of March*, 1853.

20.—*Aneurism of the Ascending Aorta.*

This man was admitted into Guy's Hospital, under the care of Dr. Hughes, on the 15th of September, 1852. He was quite well and at his work, that of a sailor, three weeks before admission, when he received a blow upon the chest which knocked him down. Two days after this accident he discovered for the first time a small swelling on the right side of his breast-bone. He continued his ordinary work until within three days of admission into Guy's. During this three weeks the swelling slowly increased, but it did not cause any particular inconvenience.

His condition was as follows: On the right side of the sternum a large swelling existed, extending from the first rib above to the fifth or sixth below, and from the costal ends of the cartilages of the ribs to their anterior angles. The fibres of the pectoralis major and minor muscles were stretched over the swelling, but the movements of the shoulder-joint were in no degree limited. Throughout the entire swelling, pulsations, synchronous with the action of the heart, were very distinct, but no bruit of any kind was audible. The action and sounds of the heart were normal. There was slight appearance of anxiety and distress in the countenance, and at times some difficulty in respiration. The man's general health was good, and the physical development of his muscular system somewhat above a medium standard. The pulsations in the right and left radial arteries were equal. After repeated inquiries, he yet maintained his first account, that before the accident he believed himself to be a perfectly healthy man, and to this he attributed the swelling. He stated also, that he had been able to undergo any amount of bodily exertion quite as well as usual. He certainly, however, admitted that for eighteen months before the injury he had complained of pains in the right arm.

Digitized by Google

During the time he was in Guy's, from the 15th of September to the 27th of November, 1852, he was bled; hyoscyamus was administered; the recumbent posture was to a great extent enforced; and ice was kept constantly applied to the swelling.

He was again admitted by Dr. Barlow on the 23rd of February, 1853. The tumor on the thorax was not much increased, but his general health did not appear so good.

Autopsy, eight hours after death.—Body still warm; not emaciated; muscles well developed. A large tumor was situated in the right anterior thoracic region, extending from the clavicle above to the outline of the fifth and sixth ribs below; and from the right border of the sternum within, to the lower edge of the pectoralis major muscle, on the outside.

The pectoralis major and minor muscles were spread out and stretched over the tumor. At the lower edge of the pectoralis was a soft point, half an inch in diameter, through which sanious discharge oozed after the integument was detached.

The integuments over the tumor were normal, except that here and there the sub-cutaneous areolar tissue was infiltrated with adhesive lymph, especially towards the sternal border, where the muscular fibres were likewise agglutinated. The contents of the chest, the sternum, and the anterior half of the eight superior right ribs, were removed *en masse*. The right lung, or rather that portion of it which, in a normal state, is in relation with the ascending aorta, was adherent to the posterior surface of a large tumor. The pericardium was distended with a very large quantity of bloody serum. The serous membranes, both parietal and cardial, were covered with a thick layer of adherent, plastic, effused lymph, with difficulty removed. There were no coagula within the pericardium.

Opening the left ventricle and tracing the aorta, a large oval aperture was seen in its anterior and right lateral wall, which led into an aneurismal sac. This was situated above the semilunar valves, and below the origin of the arteria innominata. The valves were large, but otherwise normal. The ventricle was normal. The internal surface of the aorta exhibited numerous patches of earthy laminæ.

Digitized by Google

The right lung, with the exception of a mass two inches square, was normal. The tubes, however, were full of mucus, and their membrane injected. The mass spoken of was adherent to the aneurismal sac; was consolidated; and part of it was breaking up into small abscesses, whilst in another blood was effused into the softened lung-tissue. Blood was in the small bronchial tubes leading into this piece of lung. This infiltrated portion of lung was in immediate communication with the aneurismal sac.

The left was merely the subject of bronchitis.

The aneurismal sac contained fibrous clots, layers, and laminæ, and much grumous blood in contact with the lung behind and the pectoral muscles in front; as if softening, inflammation, and suppuration of the sac, had taken place.

The inferior half of the second rib, and the superior half of the fifth, were destroyed. The anterior half of the bodies of the third and fourth ribs were entirely removed; the blunt, rounded extremities projecting into the sac of the aneurism.

When the fibrin was removed from the aneurism, two very distinct portions of this sac came under observation: first, the one portion, which might be designated intra-thoracic; second, the other, extra-thoracic. The first exhibited the characters of longer standing, a firm rigid wall and sharp, circumscribed outline; the second thin, ill-defined walls, formed by the surrounding tissue. The limit between them was very distinct, and resembled almost the borders of the aortic aperture. I am particular in describing these two portions of the cyst, because the man stated that the swelling on his chest came on quite suddenly, and was the result of a severe contusion. In all probability, therefore, the intra-thoracic aneurism had been slowly forming, and destroying, by absorption, the third and fourth ribs. The blow lacerated the anterior wall of the aneurism, and thus formed a diffused aneurism external to the thorax.

The thoracic viscera were alone examined.

Mr. Birkett, *15th of March*, 1853.

Digitized by Google

21.—*Aneurism, involving Malformed Aortic Valves and the Commencement of the Aorta.*

The preparation was removed from a painter, twenty-six years of age: a man of moderate stature; not emaciated; his lower extremities were œdematous. No account whatever of his history could be obtained.

The heart was considerably increased in size, weighing 17¾ ounces avoirdupois. Both ventricles seemed proportionably hypertrophied. Their walls were about natural in thickness, but their cavities much enlarged. The posterior aortic valve was quite healthy; the sinus above it somewhat dilated. The curtains of the right and left valves were continuous, and seemed to have been the subject of that form of malformation in which, two contiguous valves having partially coalesced, a more or less perfect frænum is left on their upper aspect, indicating the line of union. This appearance, however, was much obscured by a small aneurism of the commencement of the aorta, to a certain extent involving the frænum. The aneurism was about as large as a filbert, and projected forwards so as to produce a slight bulging opposite the centre of the attachment of the neighbouring pulmonic valve; the bulging occupied the walls of the sinus of Valsalva for three or four lines above the attachment, and the muscular tissue of the ventricle for the same distance below. The tissues over its convexity were much thinned, and transparent when held up against the light. On dissecting away the fat and cellular tissue from the interspace between the ventricles and commencement of the large arteries, it was found to project as a small roundish tumor between them. Its orifice of communication with the aorta was triangular and almost equilateral, each side measuring about half an inch. The base of the triangle corresponded to the central part of the attached margin of the compound valve; the apex pointed upwards, and was situated in the mesial line of the frænum before mentioned, a portion of which, one-third of an inch long, standing in relief from the aorta, extended from this point vertically upwards: below this the frænum was absent, its continuity having

Digitized by Google

been destroyed by the aneurismal pouch, or perhaps I should rather say, it formed an imperfect bifurcation, one division passing down along and bounding the right side of the orifice, the other not forming the left margin however, but appearing to come to an abrupt termination at the very apex of the triangle. A good idea of the relative position of the parts may be gathered from supposing the aneurism to have originated in the frænum itself; and it does not seem improbable that such actually was the case: for in the least advanced condition of this malformation (if in such cases the term is correctly applied) it sometimes happens, as is shown by a preparation in St. Thomas's Museum, that when the union between the valves is very incomplete, the frænum presents on its upper aspect a vertical slit communicating with a shallow pouch; the pouch thus formed is certainly a possible locality for the origin of aneurism. If this be supposed to have occurred in the case under consideration, the anomalous position of the aneurism is at once explained.

The compound sinus above the malformed valves was dilated; all the other valves of the heart were healthy; the aorta presented but little appearance of atheroma; the pericardium was natural; the pleuræ presented old adhesions; the lungs were small, and presented appearances neither of emphysema nor of pulmonary collapse; they were crepitant; slightly congested, but not œdematous; there was no tubercle or other abnormal deposit. The mucous membrane of the bronchial tubes was congested, and they contained a good deal of viscid mucus; in some parts colourless and transparent, in others whitish and opaque.

The liver was somewhat indurated, and had a nutmeg appearance. No other organ presented any change worthy of remark.

Dr. Bristowe, *19th of April*, 1853.

Digitized by Google

22.—*Aneurism of the Abdominal Aorta.*

R. A., aged forty-nine, a warehouseman, and accustomed for many years to active and severe manual labour.

During the last two or three years he has observed a considerable fulness in the left lumbar region, and at times was conscious of pulsation there. Suffered severely from pain in the left thigh and loins.

Ten years ago he was suddenly seized with giddiness, followed by insensibility, and accompanied by ptosis of the right lid, and a divergent squint of the right eyeball, which latter he still retains. He recovered sufficiently to return to business in about five or six weeks time.

About eight years ago he experienced exceedingly severe pains in the left hip and thigh, the course of which corresponded with the left side of the lumbar vertebræ, and the line of the anterior crural nerve, as far as to the knee. He received a great deal of treatment, but without making any improvement.

In July, 1852, he was seen by the writer, and the existence of a pulsating tumor in the left lumbar region was first recognised. There was then an obvious bulging in this situation, measuring about five inches across, over which the muscles of the back moved freely; this became more evident in the stooping than in the standing position. Lying on his back, the fingers encountered a large resisting mass beneath the cartilages of the left false ribs, extending across the middle line, and distinguishable, but less clearly, two inches to the right of it. On grasping the mass between the two hands, expansion was distinctly perceived with each pulsation of the tumor. No bruit could be heard in any position of the patient.

During the subsequent winter (1852–3), gradual progress in the size of the tumor could be noted. The lower ribs projected more; the overlying muscular and other tissues of the back were notably thinner. Impulse and expansion much stronger. Bruit never was distinguished at any time. The general health deteriorated, and the pains in the loins and thighs were at times very distressing. Measurements from

Digitized by Google

the spine opposite the third lumbar vertebra to the median line in front, were as follows :—right side, 14¼ inches; left, 15¾ inches.

On the 17th of April, 1853, while straining at stool, he complained suddenly of severe shooting pains in the thighs and belly, rose hastily, but fell on floor, from which he was unable to rise, and was lifted upon the bed. He appeared to suffer great pain, but shortly became unconscious, and died in about an hour.

Post-mortem examination, thirty hours after death.—The abdominal cavity only was allowed to be examined. On opening it and turning aside the omentum, an unbroken aneurismal tumor, firm to the feel, and nearly as large as an adult head, was seen to occupy the left side, greatly displacing the stomach, liver, and intestines, which were found on the right of the median line. The mass, which was carefully removed, and presented to the Society, had the following relations :—In front, and by the left, or outer aspect, it was in close contact with the abdominal walls, and in part with the diaphragm, but no adhesion to any of these existed. Above, it was similarly related to the diaphragm. On its right, lay the stomach, spleen, and intestines, and in part the lumbar vertebræ, three of which were largely absorbed, apparently by pressure. Behind, the walls of the tumor were lost in the muscles of the back, so that it was necessary to remove part of them, and approach very nearly to the skin. The left kidney, of small size, was adherent on the posterior and outer aspect, and was necessarily removed with the tumor. The corresponding ureter crossed its outer side.

The aorta, immediately beneath the diaphragm, expanded into a thick-walled sac, about the size of a large orange, from which the mesenteric and other arteries, greatly dilated, arose; with the outer side of this, the tumor communicated by a circular, well-defined orifice, about the size of a half-crown piece. The greater portion of its contents was formed by solid fibrinous laminæ, occupying all but the part adjacent to the opening described, where dark grumous matter, of very thick consistence, existed: much of this latter was also found in the dilated

Digitized by Google

arterial sac. Two or three of the fibrinous laminæ appeared to be loose in the cavity.

Mr. Henry Thompson, 19*th of April*, 1853.

23.—*Aneurism of the Ascending Aorta bulging considerably into the cavity of the Right Ventricle, and commencement of the Pulmonary Artery, the channel of which it almost entirely blocked up.*

The specimen consisted of a heart having the following appearances:—Externally, was seen a hemispherical prominence of about 3½ inches in circumference, situated to the right of the origin of the pulmonary artery, and in front of the appendix of the right auricle, which was pushed backwards by it. This prominence evidently consisted, for the most part at least, of the thickened pericardium, which was protruded, and almost filled, by a rounded mass of fibrin; one portion of the pouch was flaccid and indented, owing, as it were, to a retirement of its contents; but when recent, it was fully distended by them. Connected with the external surface of this pericardial pouch were one or two firm shreds of fibrous tissue, the remains of effused fibrin. On opening the *right* side of the heart, the auricle, as well as the auriculo-ventricular opening, was seen to be dilated. The ventricle was also dilated, and thinner as to its walls; and in the portion of this cavity leading to the pulmonary artery, as well as in the right side of this artery itself, was found a large portion of the aneurismal pouch which, projecting very much, all but blocked up the passage for the blood. This pouch, formed in part by the muscular walls of the ventricle, and in part by the parietes of the pulmonary artery, involved one of the flaps of the semilunar valve, which, by intimate adhesion to the pouch, was almost obscured; the crescentic outline however of a portion of this flap was still to be recognised. Adherent to the extremity of the pouch was a large flake of soft, yellow fibrin. On the left side of the heart the cavities were natural, as were also the valves, excepting slight patches of opacity here and there. The inner surface of the root and arch of the aorta was exceedingly

Digitized by Google

scabrous and inelastic, owing to the deposit of yellow atheromatous matter within the arterial tunics. At the inner side of the lower portion of the ascending aorta were two foramina caused by ulcerative destruction of the parietes; one of these, situated higher than the other, was rounded and small, and only penetrated into the thickened walls of the artery; the other was of about the size of a large filbert, with a rounded, thickened margin, the lower part of which was situated immediately behind the inner part of the aortic valve; and through this latter opening the finger could be passed freely into the bilocular aneurismal pouch before described. The cavity of the aneurism was filled with fibrinous deposit, which in the centre was perfectly soft, and at its circumference formed firm concentric layers lying in contact with the coats of the aneurism, which they tended materially to strengthen. There was also found an atheromatous state of the coronary arteries, and about two ounces of yellowish serum along with some shreds of recent flaky fibrin, within the pericardium. The weight of the heart was nineteen ounces, and the structure slightly fatty. The lungs were considerably engorged, but nothing more.

Within the peritoneal sac much clear, yellow fluid was found, and the intestinal tract throughout was healthy. The kidneys together weighed ten ounces: they were somewhat lobulated, and slightly granular as to their surfaces. They were very firm in texture, and rather light coloured; but a sectional surface had not any particular appearances. The spleen was soft and friable, and one portion of its capsule was of almost cartilaginous consistency. The other abdominal contents were natural, and the abdominal aorta was free from any marked atheromatous deposit.

The specimen was taken from a man aged thirty-eight, who was admitted into St. George's Hospital, with a very livid face, and suffering from intense orthopnœa with cough. The only history that could be obtained was, that for some time he had had cough and dyspnœa, but had only for fourteen days been obliged to give up his work. Since then he had been getting worse. The patient was in such pain and uneasiness, and the action of the heart and lungs was so great, that it was impos-

Digitized by Google

sible to make any satisfactory stethoscopical examination, and he died a few hours after his admission.

Independently of the rarity of aneurisms of the aorta taking such a course as the present one, this case is interesting as showing to what an extent a diseased state, sufficient almost to prevent the passage of blood through the heart, may be compatible with life, and even, as in this case, with a comfortable existence. Such instances very forcibly call to mind those cases in which, as Dr. Latham says in his "Diseases of the Heart," we have the orifices of the heart so interfered with as "only just not to be closed," and yet no stethoscopic indication of such a state exists, simply from the fact that the current of blood is too insignificant and gentle to produce any sound whatever. Whether the patient had had rheumatic fever previously or not could not be determined; but the pathological condition before us was doubtless the result of a tendency to the deposit of the fibrinous elements from the blood, either upon or within the walls of the artery, which becoming altered in character, assume the condition of the so-called atheroma, and by softening, induce destruction of the arterial parietes,—a tendency very similar in many respects to that which obtains in rheumatism, or when we have certain forms of diseased kidneys.

Dr. J. W. Ogle, *3rd of May*, 1853.

24.—*Specimen of Aneurism of the Ascending Aorta communicating with the Pulmonary Artery.*

The specimen consisted of a heart having the following description:—Externally, was seen a pouch equal to a small hen's egg in size, but of a globular shape, situated to the right of the root of the pulmonary artery, and in front of the appendix of the right auricle, which it pushed backwards. This pouch was evidently composed of thinned walls, and was unoccupied by any great amount of contents. On opening the right side of the heart, the cavities were found to be dilated, with very thinned parietes, and a very large auriculo-ventricular orifice. The walls of the pulmonary artery seemed thinner

Digitized by Google

than usual, especially at the posterior portion of the circumference; and in this part, about $\frac{1}{4}$th of an inch above the crescentic outline of the middle of the semilunar flaps of the valve, was an oval, obliquely-placed opening, of about $\frac{3}{4}$ths of an inch in length: this communicated with the interior of the aneurismal pouch before mentioned. Moreover, to this thinned part of the walls of the pulmonary artery, portions of the semilunar flaps of the valve were intimately adherent, so that their outline was well nigh entirely lost. About $\frac{2}{3}$rds of the middle flap, and about $\frac{1}{2}$ of the left one, were in this way affected, all action being of course entirely destroyed. The pulmonary artery in every portion higher up was healthy. On the left side of the heart, the cavities were also dilated, having thinned walls: the mitral valve-flaps were healthy, but there was slight opacity of the aortic valve-flaps. The ascending part of the aorta was very rough, and thickened by deposit of atheromatous substance in its tunics, and at the inner and posterior part of the tube was an oval opening of about $1\frac{1}{2}$ inches in length, and an inch at its greatest breadth, communicating directly with the pouch noticed externally. The margins of this opening were thickened and rounded, but tolerably smooth, and the lowest part of it was on a level with the union of the contiguous parts of the valve-flaps. On passing the finger into the pouch from this opening in the ascending aorta, it was found to have no clots adherent to its walls, but to contain some loose, bloody coagula. The inner surface of the pouch was, however, roughened and indented, and hardened. The pericardial sac contained about three ounces of yellowish fluid, and a few flakes of recent fibrin. The coronary arteries were natural. There was found a large amount of turbid, reddish fluid in the pleural sacs, with old pleural adhesions, and great engorgement of the lungs, but nothing more. The peritoneal sac also contained a slight amount of reddish-yellow fluid, and the abdominal viscera generally were much congested. The kidneys were greatly enlarged and solid, weighing together 13 ounces. They were very smooth as to their surface, and their substance was of a pale fawn-colour.

The patient from whom the specimen was removed was a

Digitized by Google

woman aged twenty-seven, who had been the subject of palpitation and dyspnœa for three or four years, but for the few weeks previous to her admission into St. George's Hospital had been much worse, and about eight or nine days previously had had a severe attack of hæmoptysis, and experienced considerable increase of dyspnœa, with œdema of the lower extremities. She was quite regular as to the catamenia, &c. When admitted, her face was rather pale, and her lips rather blue, but no marked cyanosis existed. There was extreme palpitation and irregularity of the heart's movements, and the pulse was 120, and very jerking. There was much dyspnœa and cough, with rusty expectoration mixed with decided blood. A strong systolic murmur existed over the entire præcordial region. She was cupped between the shoulders, and diuretics with sedatives were given to her. After a short time, the heart's action was moderated, and the systolic murmur was found to be the loudest on the left side of the sternum, opposite to the cartilage of the third rib. To the right of this point, the diastolic sound was found to be clear and natural; but to the left, no second sound could be discovered.

Immediately above and below this cartilage, a distinct tremor was to be felt externally, corresponding with the systole. The hæmoptysis continued, and the cupping with sedatives was repeated. Subsequently, pain at the præcordial region came on, and digitalis with leeches to the part were resorted to. Vomiting and greater dyspnœa came on, and the patient died rather more than one month after her admittance into the hospital.

The above case is interesting, inasmuch as the occurrence of aneurism at this part of the aorta is not very common, but the relation between the symptoms and the post-mortem results of the disease give but little assistance towards diagnosis in like cases. The physical phenomena presented, coupled with the absence of any amount of cyanosis, would have led the observer to imagine that some serious disease of the large blood-vessels of the heart existed, but more than this could hardly be ascertained during life. The morbid condition set up was doubtless owing to the presence

Digitized by Google

of atheromatous disease of the parietes of the aorta, but at what time the assumed alteration in the arterial tunics arose we have no evidence. From ample experience, it may now be fully recognised that such changes are not necessarily connected with what is called rheumatism, though they are doubtless in close alliance with some state of the blood like that which obtains in acute rheumatism. No history of rheumatism in this case was obtained. This case also may be classed among those which, as has been shown by others, prove that the mere mixture of venous and arterial blood does not of necessity produce cyanosis, unless some other complication exists.

Dr. J. W. Ogle, 17*th of May*, 1853.

25.—*Ossification of the Small Arteries and Capillaries of the Brain.*

The brain was removed from a man, aged thirty-seven, who died of inflammation of the hand, with purulent absorption and deposit in the muscles of the chest, in the lungs, and kidneys. There was no symptom during life referable to the brain, beyond the low muttering delirium that preceded dissolution. The heart, great vessels, and vessels at the base of the brain, were all healthy. The brain seemed perfectly natural in all respects except one; that was, that on making sections of the cerebellum and corpora striata, sharp spicula or bristle-like processes, evidently completely ossified vessels, projected from the cut surface.

"The trunks of the smaller vessels affected with this disease are of their natural size, but the minutest ramifications and the capillaries are much enlarged and altered in their appearance, looking more like globules of oil joined together than like blood-vessels.

The membranous tunic of the capillaries cannot be distinguished, in consequence of these bodies being so thickly crowded together upon its outer surface. (See Fig. 1, from a drawing by Dr. Bristowe.)

Digitized by Google

FIG. 1.

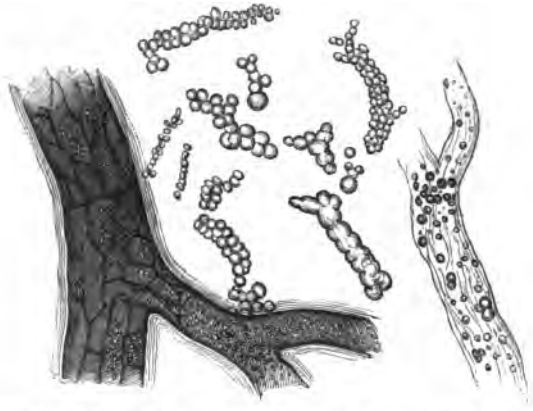

These bodies are of various sizes and forms, but all are more or less spherical; this depending most probably upon the degree of compression to which they were exposed during their enlargement, by the pressure of one body against another; hence those which are single are perfectly globular, whilst those which are very much crowded together are most flattened.

Their size varies very much; some are too small to admit of accurate measurement; the middle-sized ones are about $\frac{1}{5000}$th of an inch in diameter; these are by far the most numerous; and the largest are $\frac{1}{100}$th of an inch.

If the capillaries studded with these particles be freed from the surrounding cerebral substance by exposing them to a stream of water, or by other means, and examined under the microscope in contact with a little hydrochloric acid, they will be seen to lose their globular form and oily appearance, and to give off carbonic acid; and if the muriatic acid thus employed be afterwards mixed with oxalate of ammonia, oxalate of lime will be precipitated; or if muriatic acid, in which these bodies have been macerated, be neutralized by an alkali, phosphate of lime will be thrown down: hence it is evident that they contain carbonate and phosphate of lime.

Digitized by Google

These bodies, when acted upon by muriatic acid, do not entirely disappear, but a membranous residue is left, of a circular form; hence, in addition to the earthy compound, they contain an animal material.

Diluted acetic acid affects them very slowly, but the earthy component is soon dissolved by the concentrated acid.

A solution of citric acid acts upon them rapidly, with an extraction of carbonic acid.

Oil of turpentine and ether have no effect upon them; showing that they are not of an oily nature, as their appearance under the microscope, especially when they are illuminated by the central rays of a pencil of light, would seem to indicate.

The quantity of effervescence is of course dependent upon the quantity of deposit, and the rapidity with which it is dissolved; if only a very minute portion of it is dissolved, and that very slowly, as when acetic acid is employed as a test, no carbonic acid is given off, it being retained in the fluid in which the deposit is placed for examination, and therefore no effervescence ensues.

As respects the formation of those bodies, it may be observed, that the action of acid upon them, as seen under the microscope, shows the smallest particles, those most resembling oil, to be of the same nature as the largest, and that the latter are formed by the deposition of fresh portions of the earthy material upon the surface of the former; hence some of the largest globular masses appear, when highly magnified, to be made up of concentric laminæ.

In those vessels which are very small, though sufficiently large to have a cellular coat, the deposit is seen immediately beneath it, upon the outer surface of the inner tunic. In the capillaries it seems to be on the outer surface of the single tunic, which is so studded with globules of calcareous matter as to be entirely concealed, and these vessels made to appear tubercular or varicose on their external surface, and without any internal cavity; if, however, all the earthy matter be removed by an acid, there is in some of the vessels the appearance of an internal central groove.

These concretions are not confined to the capillaries and

Digitized by Google

small vessels of the brain, but they exist in great abundance in the white matter found under the lining membrane of the large arteries, in the disease called atheroma, mixed with plates of cholesterin and a little oil; hence it seems extremely probable that the concretions on the outer surface of the single tunic of the capillaries, and those on the outer side of the lining membrane of the large arteries—this membrane being of the same nature as that forming the capillaries—are primarily the same disease.

In atheroma of the larger arteries, besides the concretions above described, there are plates of cholesterin and some oil. May not the addition of these latter substances be accounted for in the larger vessels by the injury which can scarcely fail to have been done to the middle coat by the contact of the concretions on the inner one, by which its nutrition and vitality are so affected as to cause it to pass into a state of degeneration, whilst in case of the capillaries, these possessing only one of the tunics found also in the larger vessels, there is nothing in contact with the earthy concretions analogous to the middle coat of an artery which can undergo degeneration, and be converted into cholesterin and oil; and the tenuity of the single tunic is such that if it should suffer disintegration it would not be possible for it to yield the elements of any considerable quantity of these substances. Hence it is a question whether that which has been called fatty degeneration of the minute vessels of the brain is in reality such, and whether it is not, in all cases, as in the present one, a formation of earth-concretions on their outer surface.

My object in bringing this case before the Pathological Society is not to decide the question, but merely to suggest to its members the employment of other means, besides simple inspection by the microscope, in the investigation of all diseases of a similar kind affecting the capillaries of the brain and other parts.

If the above explanation be correct, the simple deposition of earthy matter, such as that which has just been described, on the capillaries and small vessels of the brain is a disease which may occur in every part of the arterial system; whilst

Digitized by Google

atheroma is confined to the larger vessels—to those having a middle coat sufficiently substantial when in a state of degeneration to furnish an appreciable quantity of oil or cholesterin; and is primarily a disease of the inner coat, and subsequently a disease also of the middle one."

Dr. BRISTOWE, for Mr. RAINEY, *2nd of November*, 1852.

IV.—DISEASES, &c., OF THE ORGANS OF DIGESTION.

1.—*Epithelial Cancer of the Tongue in a Gouty Subject.*

J. D., aged fifty-five, became subject to gout about twelve or thirteen years ago; and from that time up to a month or two before the appearance of the cancer, he has suffered from repeated attacks of the disease. In May last he called attention to a small tumor situated at the root of the tongue, extending upwards towards the right palatine arch. Externally at the angle of the jaw was a hard enlarged lymphatic gland. The tumor increased in size, became ulcerated, and he died exhausted at the close of last month. The tumor (a portion of which was placed under the microscope), presented all the characters of epithelial cancer. Some needle-like crystals of urate of soda from some of the small joints were also submitted for examination.

Dr. QUAIN, for Mr M'SHANE, R.N.,
21st of December, 1852.

2.—*Ulceration at the Pyloric Orifice of the Stomach.*

10th of September, 1852.—E. M., aged forty-two, subject to dyspepsia and to dyspnœa for some years, had a premature confinement in May 1851, from which she never perfectly recovered, in consequence of not being able to retain her food, which was generally rejected in an hour or two after meals. After some weeks the matter vomited consisted of food mixed with a dark fluid, apparently altered blood, and now she became much changed in appearance, losing her colour,

Digitized by Google

being affected with albuminous urine, with ascites and anasarca. At this time she complained of severe abdominal pains, which were attributable to the distension by the ascites, the cause of which was obscure, as there was previously no tumor of the abdomen, and the patient was a sober woman.

About four months ago she entered St. George's Hospital, where she was tapped, had her legs punctured, and remained till ten days before her death, when the ascites had returned, but not the anasarca, though the urine was still albuminous. The vomiting continued, and was now attended with diarrhœa of the same dark, offensive matter which lasted up to her death. Four days previous to this, she had a severe pain in the left side, for which a blister was applied, but she was too ill for examination by the stethoscope.

Post-mortem examination, twenty-six hours after death.—About 1½ gallons of clear serum in abdomen. Lungs healthy, except at base of left, where there was a congested portion surrounding a grey mass about the size of a walnut, which was infiltrated with serum. The congested portion was covered with recent lymph. The omentum adhered firmly to the parietes, as well as to the bowels. The liver was apparently healthy in structure, but atrophied and mis-shapen by the compression of strong adhesions to the diaphragm. The spleen was also strongly adherent to the diaphragm. The stomach was enlarged and generally thickened, especially at the pylorus, where there was an ulcer 3 inches long by 1½ wide, occupying most of the upper surface of the pyloric orifice, covered by the mucous membrane, which was thin and uneven, contrasting strongly with the mucous membrane beyond the edges of the ulcer, which was double the usual thickness. The stomach was full of dark-coloured fluid; but there was no other ulcer, nor any congested state of the surface from which it might have flowed. Kidneys only half the natural size, one encysted; neither exhibited any traces of healthy structure, being granulated throughout. The heart was healthy. Great vessels contained only a bloody serum; and there were only some very small clots of fibrin in the heart. There was no trace of cancerous deposit in any organ, if the thickened

Digitized by Google

pylorus be not of that character. The uterus and ovaries were healthy, though she never menstruated after her last confinement.

The chief points of interest in this case are the long period (above a year) that the vomiting of coffee-ground matter, evidently decomposed blood, continued, without the existence of any extensive or deep-seated disorganization of the stomach; the occurrence of ascites from subacute peritonitis, though attributed at the time to disease of the liver, connected with the affection of the stomach; the complete removal of the œdema by puncturing the legs, although the ascites remained; and the cicatrized state of the ulcer of the stomach, which in no part was entirely denuded of the mucous membrane.

Dr. Ogier Ward, *2nd of November*, 1852.

3.—*Perforation of the Stomach.*

Maria L——, aged eighteen years, was admitted to the St. George's and St. James's Dispensary, on the 21st of October. She had menstruated sixteen months previously, but the discharge was very slight, as she caught cold. It only lasted a few hours. She presented the usual appearance of chlorosis, and had been out of health for more than a year. On the 20th of October she vomited a quantity of blood, and complained of pain in the epigastric region. Under treatment she improved somewhat in health, and on the 4th of November expressed herself as feeling much better. On the 6th of November Dr. Clarke was sent for, and found her moribund, insensible, and unable to swallow. She died at six P.M., of the same day. It appeared on inquiry, that on the Thursday night, the 4th, she was attacked with violent pain in the stomach and vomiting, and that she became insensible on Friday, the 5th.

Post-mortem examination, thirty-nine hours after death.—The body was well-formed and fairly nourished. The lungs were healthy; a small quantity of fluid was found in the cavity of the thorax. The heart was healthy in structure; the parietes of the left side enormously thickened; those of the right side

Digitized by Google

as much attenuated. The liver was healthy; very firm adhesions attached the under side of the left lobe of the liver to the concave border of the stomach. The stomach was enormously distended with fœtid gas, and on slitting open the upper surface of it, a perforation was found close to the part adherent to the liver, and covered by a thin layer of lymph. The walls of the stomach surrounding the ulcer were very thin; in fact, the mucous and muscular coat hardly existed, and nothing but the peritoneum appeared to have retained the contents of the stomach. The coats were puckered up at the seat of the old adhesions, forming a kind of pouch. Nothing could be learnt of the girl's previous history, but that she had suffered at times from pain in the stomach. The uterus and appendages were shown. The uterus was very small but healthy. The ovaries were large, and several Graafian vesicles were seen close to the surface, apparently ready to burst through. It may be presumed that menstruation would have taken place had it not been for the disease in the stomach. Ample evidences of peritonitis were present.

Dr. JOHN CLARKE, *7th of December*, 1852.

4.—*Instances of Degeneration of the Mucous Membrane of the Stomach.*

No exact description has been given that we know of to the condition termed "mammellation" of the gastric mucous membrane. Andral calls it a partial hypertrophy; Rokitansky one of the results of inflammation. In the following case, the condition was very apparent to the naked eye.

S. Q., admitted into St. Mary's under Dr. Chambers, on the 3rd of December, a thin spare woman with anxious face, ailing two years; she has been laid up six weeks with cough and yellowish muco-puriform expectoration, sibilans and moist râle in both lungs; urine acid, scanty, not albuminous, loaded with lithates; pulse 140, very weak, regular. Died on the 8th, (no symptoms referable to the stomach were observed).

Lungs congested, bronchial tubes inflamed.

Digitized by Google

Heart.—Weak, flabby and dilated.

Liver. — Markedly nutmeg; extreme marginal fatty degeneration; considerable increase of fibroid tissue of the Glissonian sheath.

Kidneys.—Not wasted, surface not perfectly smooth; central tubes plugged up with oily and granular matter; inter-tubular effusion to some extent; much yellowish-red pigment scattered about in the form of granules and masses; some of the Malpighian tufts healthy, others not; medullary tubes choked up with opaque, oily matter.

Stomach.—Considerable hypertrophy of the muscular fibres around pylorus; mucous membrane in the third of stomach adjacent to pylorus, of a reddish-brown colour and mammellated aspect. This covered over with small, indistinct, sometimes whitish eminences; these are best seen on vertical section as whitish grains or masses in the sub-mucous tissue, resembling very much the glands of Brunner, in the duodenum, when enlarged. These masses consist of tortuous tubes crowded and packed together, and filled with an epithelium, consisting of smaller sized cell-particles and free nuclei, together with abundant amorphous granular matter and much oil. (See Plate II). The basement membrane of the tube is distinct. In the intervals of the masses there are no tubes; the ordinary parallel arrangement is entirely lost. The epithelium of the free mucous surface is columnar. The masses of aggregated tubes are closely girt by a layer of fibroid tissue, which seems to compress them.

It seems very doubtful whether the remarkable alteration of gastric mucous membrane just described, can be considered of inflammatory origin. The tissue presented no appearance of inflammation; there was no intertubular exudation; some of the larger vessels were injected, but the hyperæmia seemed no more than passive.

The masses of aggregated tubes bear some real resemblance, I think, to the granulations of a diseased kidney; and like them, result from the decay of the surrounding tissue, and the distension of their canals by epithelium. (See Plate

Digitized by Google

III). It is worth notice, that there was degenerative disease of the liver and the kidney. The change in the stomach was probably of the same nature.

In another case, which I had the opportunity of examining through the kindness of Mr. Ancell, in which there was marked degeneration of the kidneys, and in which symptoms referred to the stomach had been present for a long time, I found the tubes of the mucous membrane remarkably altered. In some parts they were broken up, in others more or less distinct traces of them still existed; they were filled with mere nuclear particles instead of their proper granular epithelium. Their function must have been unfulfilled.

In a female dying of bronchitis, with tuberculous cavities in her lungs and a very thick layer of fat on her abdomen, with other organs tolerably healthy, the mucous membrane of the stomach was found in the middle parts remarkably mottled over with dots of ramiform injection. These were produced by filling of the small veins and adjacent capillaries. The tubes in some parts had almost completely perished; they were like streaks of granulous matter, containing oil drops; in others, they were more distinct, like opaque cylinders filled with oily matter, especially at their deeper part. When the degeneration was most complete, there appeared a uniform mass, as if the tubular epithelium or its débris had blended with an intertubular exudation.

In the case of a female dying of pneumonia with an hydatid in the right lung, the stomach was of a reddish-brown tint throughout. The tubes were quite opaque, filled in every part with an oily looking mass, which consisted of solid fatty particles and granular matter; the solid particles were much about the size of the ordinary nuclei, and were probably the same, altered and degenerated. In this part there were no other nuclei or cells. In another part there was more appearance of the ordinary epithelial structure; but even here the nuclei and cells had not their natural aspect, they were more like mere oily masses.

Without wishing to speak too positively from so few obser-

Digitized by Google

Digitized by Google

DESCRIPTION OF PLATE III.

The figures from 1 to 7 illustrate Dr. Handfield Jones' instances of degeneration of the mucous membrane of the stomach. Page 124.

Fig. 1. Two stomach tubes, the epithelium of which is in a state of fatty degeneration.

Fig. 2. Escaped epithelium.

Fig. 3. Stomach tube degenerating.

Fig. 4. Vertical section of mucous membrane of stomach in mammellated condition.

Fig. 5. One of the masses made up of aggregated and contorted tubes.

Figs. 6, 7. Epithelium: 6. Columnar; 7. Glandular, from tubes.

FIGS. 8, 9, 10 illustrate Mr. Birkett's case of villous cancer of the large intestine. Page 154.

Fig. 8. A small portion of the villous growth, showing its foliated character. Magnified 35 diameters.

Fig. 9. One villus, with portions of two others, showing the epithelium covering their surface, and a vessel carrying blood into it. Magnified 200 diameters.

Fig. 10. A small portion, showing the nuclei and granular texture of the epithelium. Magnified 270 diameters.

Digitized by Google

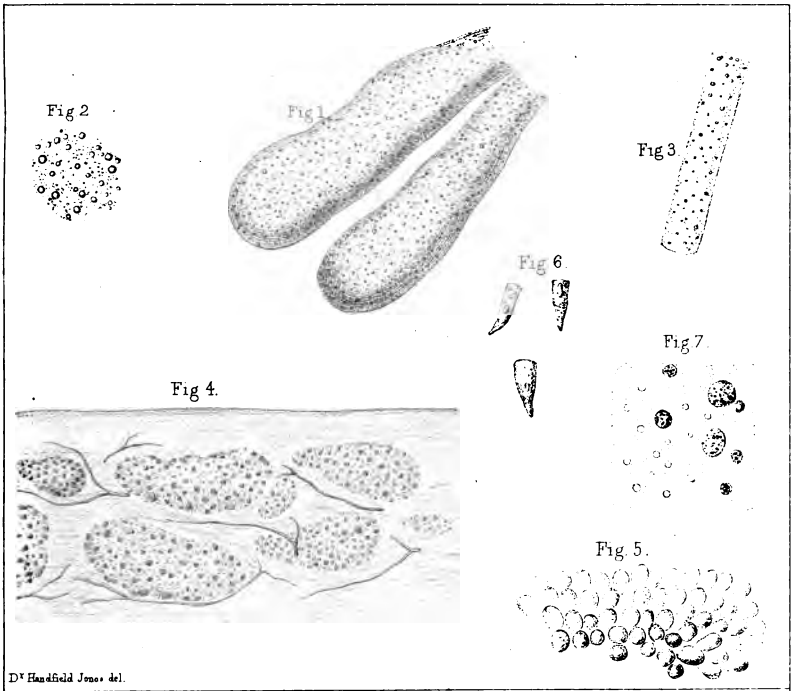

Dr Handfield Jones del.

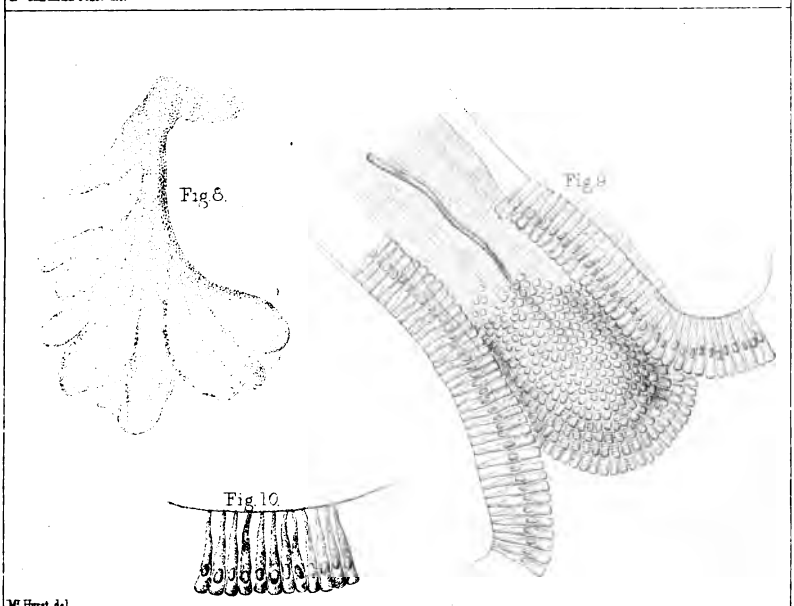

Mr Hurst del.

Tuffen West, sculp.

Ford & West, Imp. 54 Fauon Garden.

Digitized by Google

Digitized by Google

vations, I may state that I think there is some reason to believe, that the glandular secreting structure of the stomach is liable to degenerative disease, of the same kind as those which affect the kidney or liver. One of these is a fatty degeneration, the other a change more analogous to granular renal disease. The importance of recognizing such changes as these with respect to treatment cannot be over-estimated.

Dr. HANDFIELD JONES, 21*st of December*, 1852.

5.—*Chronic Thickening of the Stomach and Omentum, somewhat resembling Malignant Disease.*

Mrs. G., aged forty-nine, had observed for the last two years a gradual increase in her size of her abdomen as if she were pregnant. The last child was born five years ago. Three months ago she began to vomit her food, and continued to do so till her death, with only occasional intervals. The vomiting occurred immediately after food or medicine was taken, and frequently, when nothing was swallowed, a yellowish fluid was ejected from the stomach. She complained of constant pain in the epigastrium, aggravated by pressure, not by food. On examination, a rather firm irregular tumor appeared to occupy the epigastric and umbilical regions, while inferiorly there existed the fluctuation characteristic of ascites. The lower limbs were distended with fluid.

On examination after death, the stomach was found greatly thickened, the tissues being converted into a greenish-white, firm substance, like brawn, in some places more than a quarter of an inch thick. It cavity was much contracted; there was no ulceration or abrasion of the mucous surface. The pancreas was unusually large and dense in structure; the omentum loaded with fat. There was ascites to some extent. The first impression was, that the altered structure of the stomach was due to disease of a malignant character, which led to a careful microscopical examination of a recent specimen, the result of which is given by Dr. Quain as follows. The remaining viscera were healthy.

Dr. POLLOCK, 15*th of February*, 1853.

Digitized by Google

Report on the Microscopic Characters of the Diseased Tissue in the preceding case.—On scraping the cut surface of the wall of the stomach no juice or fluid was obtained.

A microscopic portion taken from beneath the peritoneal coat of this viscus, was found to consist of granular and fatty matter mixed with broken-up fibres; there were a few small cells, but no regular fibrous stroma. A second portion, taken from beneath the mucous membrane, differed from the preceding only in this, that there were a considerable number of cells smaller than pus cells, granular, without a very distinct nucleus, uniform in size, and composed of unhealthy glandular epithelium. A portion taken from one of the masses in the omentum was likewise found to consist of granular and fatty matter, and cells not very unlike pus cells, uniform in size, and not presenting when treated with acetic acid, any very distinct nuclei. There appeared to be no distinct stroma.

The structure of a portion of the pancreas examined was healthy. An examination of these facts, showing the absence of stroma, of well-marked nucleated cells varying in size and form, and of distinct cancer juice, leaves considerable doubt on the mind as to the morbid textures being of a truly malignant nature, however much their general character may present this appearance.

Dr. R. Quain, 15*th of February*, 1853.

6.—*Hypertrophy of the Stomach.*

The patient (Mrs. D.), thirty-three years of age, was of a healthy family, none of the members of whom had ever suffered from cancer; and she had herself enjoyed fair health until the commencement of her fatal disease. She was rather below the middle stature, of light complexion, and had light brown hair and grey eyes. From the age of twelve till six years ago, she was engaged as a straw bonnet-maker, and was in the habit of pressing the iron, used in ironing the bonnets, forcibly with the abdomen, so as to obtain more power; the part of the abdomen which came into contact with the handle of the iron being at the right

Digitized by Google

nipple line, a little below the costal cartilages: whether this had anything to do with her illness is doubtful. About four or five years ago she began to feel a sinking sensation, and sometimes sharpish pains at the epigastrium; these pains were accompanied with vomiting at times, and gradually the vomiting became more frequent, so that it sometimes occurred several times a day. The vomiting has continued up to the present time, but with intervals of freedom from it; she has also been quite free from pains for as much as three months together. During the last three years, however, she has frequently vomited several times a day, generally in the morning before taking food, and sometimes at other periods of the day; when she vomits after taking food, it is this which comes up; at other times there is nothing but clear fluid; many times, however, especially at the commencement of her illness, she has vomited up a brownish fluid, like coffee-grounds.

About twelve months before Dr. Hare saw her (13th of February, 1853), whilst out riding in a gig, she was obliged to vomit, and while leaning over the edge of the vehicle for this purpose, she felt a sudden pain a little to the left of the epigastrium, of a very sharp and severe character; she thought she "had strained herself;" there was no return of vomiting till next morning, but her bowels were not open at all after this occurrence for at least a week. At the time of the accident her heart palpitated strongly, her breath was shorter than before, and fearing that something had been injured about the part, she put her hand there, and felt a "fulness" or swelling, which she believes then pulsated strongly. This swelling, thus first discovered, has not since disappeared, but it has altered in its physical condition, having got flatter and gradually increased in size. At first it was globular and was quite moveable, so that when, for instance, she lay on the right side, the tumor, which was not apparently larger than an egg, would move from its usual position towards the right. The movement of the tumor, and its rounded shape, suggested the idea of a body within the stomach.

She subsequently came under the care of Mr. Greenhalgh, at

Digitized by Google

the St. Pancras Dispensary, who saw her also on one or two occasions in conjunction with a physician of much experience; at that time the tumor was much larger than at first, and occupied so exactly the position of the spleen, that it seemed, most probably, taking all the circumstances of her then condition into consideration, a carcinomatous affection of that viscus; and this view of the case was much strengthened by the fact of a small tumor having then recently appeared close to the umbilicus.

When first seen by Dr. Hare, she was suffering from severe pain on the left side of the chest in consequence of an extensive attack of acute pleurisy of that side; loud friction sounds, with some dulness on percussion, being found on examining the chest. She was rather thin, and her complexion was light-coloured, but not sallow nor waxy. Her breath was very short; she had some cough, and severe pain, not only in the chest, but at the epigastrium and in the left side of abdomen. She still vomited at times.

Owing to the severity of her pain and the great tenderness over the upper part of the abdomen on very slight pressure, the physical examination was less satisfactory than could have been desired; there was, however, clearly made out a resisting mass, extending downwards below the left costal cartilages nearly as far as the level of the anterior superior spinous process of ileum, and reaching anteriorly about as far forwards as a line drawn downwards from the nipple; the mass, however, was then smaller than Mr. Greenhalgh described it to have been on some former examinations, and Dr. Hare found its outline to be less well-defined than is usually the case in splenic tumours; *over the greater part, too, of the resisting mass, though not over the whole of it, there was some resonance on percussion.* No other tumor or swelling could be detected within the abdomen, but at the umbilicus there was a circular tumor about $3\frac{1}{2}$ inches in diameter, projecting nearly three quarters of an inch, situated immediately under the integuments, which were partially united to it, and of a reddish colour over a portion of it; the tumor was hard, but was moveable over the parts beneath it; the umbilicus occupied exactly the centre

Digitized by Google

of the mass, and from it a slight serous discharge occasionally exuded. During the interval of a fortnight which elapsed between Dr. Hare's first examining the patient and her death, this tumor very considerably diminished, both in circumference and in thickness.

She gradually sank under the combined effect of her long-standing disease and of the pleurisy, and died on the 27th of February.

Post-mortem examination.—On opening the thorax, there was found a considerable amount of fluid in its left cavity; and the costal and pulmonary portions of that pleura were thickly coated with recent lymph. The right lung was congested, but the left one still more so. The heart was small.

The intestines were thickly covered over with a layer of firm lymph, some portions of it appearing, however, to be of more recent date; their coils were thus strongly adherent to one another: the intestines were also firmly united in a similar manner to the liver, which was, likewise, adherent to the diaphragm, especially in the left hypochondrium; it projected $1\frac{1}{2}$ inches below the ensiform cartilage. From being so completely covered with lymph, the liver and the intestines presented one uniform surface, so that it was difficult at first sight to say where the one ended and the other commenced; partly also, for the same reason, it was difficult to see the resisting mass in the left hypochondrium. On further dissection, this diseased mass was found to consist solely of the stomach, exceedingly thickened, though somewhat diminished in size, so that it measured $6\frac{3}{4}$ inches in length by $4\frac{1}{4}$ in breadth and $2\frac{3}{8}$ in thickness; its longer axis was in a very nearly vertical direction, and the position it occupied was the left extremity of the left hypochondrium; the liver and spleen (the latter not at all, and the former but little, larger than natural) were united together so as to form a kind of cap to the upper [cardiac] extremity of the stomach, the spleen especially appearing to be compressed between the stomach and the diaphragm. The tumor was so closely surrounded by

Digitized by Google

the intestines (partly the colon and partly the small intestines) as fully to account for the absence of considerable dulness on percussion, during life, over the part where the resisting mass had been felt.

The spleen was of moderately firm consistence, and measured $4\frac{5}{8}$ inches in length by $2\frac{1}{2}$ in breadth, and $1\frac{1}{4}$ in thickness. The kidneys were of a purplish colour, but otherwise healthy-looking; neither they nor any other viscus, nor the mesentric nor lymphatic glands, presented the slightest appearance of cancerous deposit.

On removing the stomach, it was found, as already stated, that its walls were exceedingly thickened, and they varied from about three-eighths of an inch to $1\frac{1}{2}$ inch across. The cavity of the stomach was so much diminished in size that it would apparently contain only four or five ounces of fluid. The general colour of the stomach, both as seen externally and on section of its walls, was a light ash-grey, the consistence moderately firm, without being in any part schirrous; the mucous membrane was nowhere ulcerated, but was very uneven, the rugæ being very marked, and it being, likewise, apparently raised at some parts more than at others, in consequence of the unequal hypertrophy of the parts below. Sections of the walls exhibited four distinct layers; the first of these was the peritoneal coat; the second, which was somewhat transparent, consisted almost entirely of unstriped muscular fibre; the next [submucous] softer, more opaque, and considerably thicker layer, exhibited only fibres of cellular and elastic tissue, loosely interwoven and infiltrated with serum; the innermost [mucous] coat, soft and somewhat gelatinous, showed the tubular glands of the stomach, and abundance of simple granular mucous corpuscles. No cancer cells were discoverable. The tumor at the umbilicus was seated in the subcutaneous cellular tissue, was adherent to the integuments, but not to the linea alba or the muscles; under the microscope it exhibited fibres imperfectly formed, and tending to granular matter—some loose granules, and a few simple cells; no cancer cells. Mr. Clover also examined portions of

Digitized by Google

the stomach and of the tumor, and failed likewise to detect any proof of the cancerous nature of either of them.

Dr. C. J. HARE, *15th of March*, 1853.

Report on the Chemico-Microscopical Examination of the preceding specimen.—Strong nitric acid produced little alteration in the microscopical characters of the tumor. Perhaps the loop-like arrangement of the fibres was rendered somewhat more distinct. The tissue was quite opaque before the addition of this reagent.

Acetic acid caused the disappearance of the fibrous character of the tumor, and at the same time a number of small, spherical, highly refractive bodies (denominated oil globules), with a few cell-nuclei, were brought into view.

Potash also caused the obliteration of the fibrous character.

By boiling small portions for many hours in water no indication of the presence of a large quantity of gelatin was obtained.

The portion of tissue examined had been preserved in Burnett's solution, which will account for the absence of any decided reaction upon the addition of nitric acid. Thin sections of tumors, resembling the present one in general characters, which have been examined by me on previous occasions, have been rendered quite opaque upon the addition of this reagent, indicating the presence of much albumen.

This tumor, I believe, consisted chiefly of white fibrous tissue, the meshes of which contained an albuminous fluid.

Dr. LIONEL G. BEALE, *15th of March*, 1853.

7.—*Extensive Ulceration of the Stomach; Malignant (?). Repeated Hæmatemesis; Anæmia. Chronic Hepatic Peritonitis; Fatty Liver, &c.*

H. S., aged twenty-six, unmarried, of regular and abstemious habits, by occupation a laundress, had been suffering from pain in her right side and stomach for the last ten years of her life; which, during the three previous to her death, had been confined chiefly to her stomach, extending to her

Digitized by Google

shoulders; the pain, at intervals, was excruciating, so much so as to render her life wretched. During this condition her general appearance became anæmic, her menstruation irregular and scanty, and at times attended with severe pain; her appetite was bad, and she lost much flesh. Her principal meals, when taken, caused sickness, and much pain in the stomach; and the greater part of her food when swallowed was soon afterwards rejected. A short time before her death she had repeated attacks of hæmorrhage from the stomach, the quantity of blood vomited varying from a few ounces to at least a pound. She had been under some of the most eminent physicians in London with little or no permanent benefit, but she experienced relief from occasional leeching and blistering the epigastrium, and from the administration of opium, hydrocyanic acid, mild mercurials, bismuth, iron, and alkalis. The case was generally considered one of anæmia, attended with disordered uterine function. The pains and derangement of the stomach were considered sympathetic. Up to the period of her death her sufferings were very severe.

I did not see her during life, but was requested to make a post-mortem examination fifty-two hours after death.

Post-mortem examination.—Countenance very sallow, having the aspect of malignant disease, but little or no fat under the integuments; body much emaciated; abdomen smooth and somewhat tympanitic.

Thorax.—About six ounces of serum, tinged red, in the left side of thorax; about four ounces in the right; lungs congested posteriorly, from gravitation; copious frothy serous fluid issued from both, on incision. Heart small, firm; left ventricle slightly hypertrophied; aorta, traced throughout, contracted, but healthy; about an ounce of serum in pericardium; cardiac pericardium milky; no decided white patches.

Abdomen.—An ounce or two of serous fluid in abdomen; liver large, pale, rather fragile, fatty; left lobe adherent, anteriorly, to peritoneum, covering the diaphragm and abdominal parietes by long, thin, membranous adhesions; the left lobe of the liver was also very firmly adherent to the lesser curvature of the stomach, so incorporated indeed as to appear one struc-

Digitized by Google

ture; in consequence the stomach was girt round, and apparently divided into two cavities. Muscular structure of the œsophagus and stomach remarkably prominent; both sacs of the stomach (which communicated with each other by a very small, and apparently, ulcerated opening) were much distended with fluid tinged with blood, and many large coagula. Upon opening the stomach the mucous membrane was in parts blackish, from altered blood under the mucous membrane: in other parts it was white. Pyloric orifice thickened and contracted. Upon the under surface of the stomach there was an irregular ulcer, larger than a crown-piece, which had apparently extended through all the coats; and the peritoneal coat of the liver formed, it would seem, the outer boundary. The vessel from which the blood had proceeded, whether artery or vein, was not apparent. The gall bladder was quite empty, and flaccid; the spleen, though somewhat large, was healthy, but firmly adherent to the left lobe of the liver posteriorly. The pancreas was thickened, and very firm; the duodenum large, but healthy in structure, as were both the small and large intestines. The kidneys were of normal size; the left was pale, somewhat granular, and easily torn; the right was mottled. The bladder was distended with urine. The uterus and external genitals were decidedly small, and not fully developed for a person of her age.

Remarks.—Two points for inquiry are presented by this case: the character of the ulcer, and the primary disease.

The Character of the Ulcer is not exactly clear. Is it malignant or not? In favour of the first supposition are its size; its situation upon the under part of the stomach, where, I believe, malignant ulceration almost always occurs; the destruction of all the coats of the stomach, the firm adhesion of the liver alone preventing the escape of the contents of that viscus; and the sallow appearance of the countenance.

On the other hand, the age of the patient, the duration of the disease, the absence of any fungoid appearance, and the repeated attacks of decided hæmorrhage, are greatly in favour of the non-malignant character of the ulcer.

The Primary Disease.—The next point for inquiry is: Did

Digitized by Google

anæmia result from the gastric affection, or was the disease of the stomach the sequel of anæmia? Here again there are circumstances in favour of both propositions. It is evident, from the report of the case, that the eminent physicians under whose care she was placed regarded the case as one of pure anæmia, and had little or no idea that there was serious disease of the stomach at all. There is no doubt, either, that an anæmic condition often leads to disease of the stomach, and even to ulceration of it, especially simple ulceration; but I think the converse of this proposition is equally true, that disease of the stomach often produces anæmia; and the imperfect nutrition of which for years this young person was the subject, would quite account for that. If the report of the symptoms can be relied upon (and I have every reason to believe they were accurately noted) there can be but little doubt that the gastric affection preceded the anæmia, for it is stated that she had long suffered from pain in the stomach, and during this condition her general appearance became anæmic.

Mr. R. R. Robinson, *15th of March*, 1853.

Report on the preceding case.—The ulcer was about 2½ inches in diameter, of a circular form, with thick but not ragged or everted edges, which were raised at least half an inch above the surface of the ulcer, and projected over it, so as to produce a considerable undermining round the entire circumference. The surface was smooth, as were also the edges.

Upon examining small portions from the surface of the ulcer with the microscope, a little white fibrous tissue, fibres of organic muscle, much granular matter, and many free oil globules were observed; but no fragments of gastric tubes, no well-defined epithelial cells, or cells resembling those from a malignant growth, could be discovered.

Acetic acid caused the muscular fibres to become less distinct, but no nuclei could be distinguished in them.

Potash produced a similar change.

The absence of a more decided reaction upon the addition of these reagents may probably be explained by the changes produced in the course of preservation. From these characters

Digitized by Google

we are led to infer that the disease was not of a malignant nature, being merely a large simple ulcer of the stomach.

Dr. BRINTON and Dr. LIONEL J. BEALE, *5th of April*, 1853.

8.—*Enormously dilated Stomach.*

Mrs. M. aged forty-eight, a lady of nervous temperament, and the mother of several children, sent for me early in the morning of the 7th of March. She had been seized with vomiting, which had continued the whole of the previous night. The fluid ejected amounted to as much as five wash-hand basins full. She was faint and weak, the pulse not exceeding forty in a minute, and intermitting. Beyond this and a feeble heart's action there was no other symptom. The abdomen was lax and soft, without pain upon pressure. She had been recently under Dr. Moore's care, being troubled with piles and prolapsus of the rectum. She had been getting thin lately, and her daughter had observed a slight increase in the size of her abdomen. I relieved the bowels by an enema, and applied other remedies. On the following day Dr. Moore saw her with me. The abdomen on examination was found sunk and depressed, little gurgling was heard in the region of the stomach, and some unusual hardness which had been observed the day previous, was felt in the right hypochondriac region. Vomiting had somewhat subsided. The tongue was dry. The bowels were again relieved of some lumpy bilious fæces by means of an injection, and remedies of a palliative nature were continued. On the following day vomiting had subsided, but the patient appeared more distressed and ill.

On the 10th, four days from the seizure, the severe vomiting ceased; we discovered a considerable swelling of the whole abdomen, commencing about the left iliac region, except that part on the right side of a line drawn from the ensiform cartilage, to right superior spinous process of ileum. The swelling was tympanitic. The pulse increased in frequency, and became more regular.

Digitized by Google

On the 11th, the tumor, instead of being tympanitic, was dull on percussion, and fluctuated; the patient experienced an inclination to vomit, on pressure being made over it.

On the three following days she continued in the same state, the abdominal tumor being larger and fluctuating; the general symptoms were those of exhaustion, but with complete absence of pain, sickness, or natural action of the bowels. On the 14th Dr. Watson saw her, who expressing an opinion as to the difficulty in forming a correct diagnosis of the case, believed it

Fig. 2.

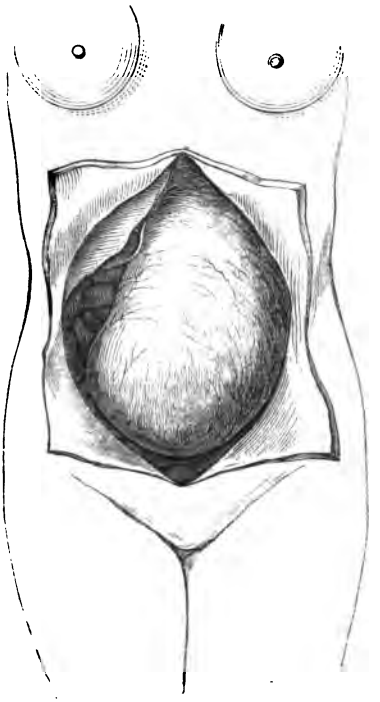

Digitized by Google

to be one of preternaturally distended stomach containing fluid, and that there probably existed some mechanical obstruction of the bowels. On the following day she became delirious at times without any relief to the symptoms generally. On the 16th she was seen by Dr. Bright, who did not come to the same conclusion as to the nature of the case as Dr. Watson. On the 17th she expired.

Mr. Humby examined the body on the following day. The viscera of the abdomen were found healthy, but the stomach. distended to an enormous size, was found occupying the whole site of the abdomina tumor. The annexed sketch (Fig. 2.) was made at the time: it shows the position it occupied in the abdominal cavity. In many places the muscular fibres of the organ had completely given way, approximating its mucous and peritoneal coats. The cavity of the stomach was capable of holding $10\frac{1}{2}$ pints of fluid. The small intestines were contracted to a very small size, and were completely pushed down into the cavity of the pelvis. No malignant disease in the abdomen whatever. In a portion of the fluid rejected from the stomach, Dr. Miller found abundant specimens of the sarcina ventriculi.

Observations.—The points of great interest in this case appeared to be the great difficulty in making a correct diagnosis of the nature of the abdominal tumor, and the complete absence of abdominal pain, as in cases generally of mechanical obstruction of the bowels. The cessation of vomiting probably only began on the occurrence of paralysis, or a powerless state of the organ, which was rendered evident by the post-mortem examination, when it appeared that many muscular fibres of the stomach had given way, partly from violent vomiting, and partly from over-distension of the organ.

Dr. Miller, for Mr. Humby, *5th of April*, 1853.

Digitized by Google

9.—*Perforation of the Stomach. Cicatrized Ulcers.*

The specimen was taken from a woman, aged forty-six, who died nineteen hours after perforation of the stomach had taken place. She had suffered for a long time from indigestion and pain in the stomach, and was engaged in her domestic duties, when she was suddenly seized with violent pain in the epigastric region, followed by sickness and great prostration. She rejected everything that was given to her, and died in nineteen hours. At the *post-mortem*, fifty-two hours after death, the peritoneum was found universally inflamed; and about half a gallon of a reddish, turbid fluid, holding flakes of lymph, was contained in its cavity. The intestinal coils were glued together, and, in the pelvic cavity, a quantity of thick, yellow, puriform fluid was observed. There was an aperture in the front wall of the stomach, nearer to the pyloric than the cardiac end, just below the lesser curvature, where the organ is overlapped by the left lobe of the liver. This opening was one-third of an inch in width by one inch in length externally, but when seen from within, it presented an oval outline, and sharp, defined edges. The mucous membrane, at the pyloric extremity, was thinned and wrinkled by the cicatrices of old superficial ulcers; and at this spot the pancreas was connected by firm adhesions with the outer surface of the stomach.

Dr. Ogier Ward, *5th of April*, 1853.

10.—*Poisoning by Bichloride of Mercury.*

The fauces, tongue, œsophagus, stomach, and larynx, exhibited to the Society, were taken from F. T., aged thirty-six, a French-polisher, who was admitted into St. Mary's Hospital, the 3rd of May, 1853, under Dr. Chambers' care, having half an hour previously placed in his mouth two drachms of bichloride of mercury, in a solid form, and with a suicidal intent. He had walked to the hospital, and when seen his lips were swollen, and the inside of his mouth covered with a white film; he was given eggs beaten up with water, which he eagerly swallowed, and soon vomited, when some was found coagulated, (he

Digitized by Google

had vomited previously to his admission). This was continued till the eggs were returned as swallowed, when he was placed in bed; neither at this time nor before had he complained of any pain over the epigastrium or abdomen. At one time there was slight difficulty in breathing, which soon passed off. On the following day the salivary glands were swollen and tender; and the day after, his breath very offensive, and teeth loose, though not much increase of natural flow of saliva. His pulse for the first twenty-four hours was irregular; there never was any collapse; he never had any abdominal pain; he had rather a frequent desire to stool, fæces passed being natural, free from blood or mucus; urine normal in quantity; had a sloughing sore on penis; denied any specific cause. He appeared to progress favourably until the evening of the 12th, when he suddenly became much depressed both in body and mind, and died early the following morning.

Post-mortem examination, thirty-two hours after death.—The fauces, larynx, tongue, œsophagus, and stomach, being removed, the uvula and pillars of the fauces were found covered with a superficial slough; epiglottis œdematous and red, anteriorly and superiorly, the rest sloughy; this latter extending into glottis, and just escaping the vocal cords; the under surface of tongue sloughy, the upper two inches of œsophagus being in the same state.

At the pyloric end of stomach two yellowish-looking sloughs, one size of sixpence, and the other of a millet seed; cardiac extremity very vascular.

Nearly the whole of the ileum, the cæcum, the colon, with the exception of lower two inches, and the whole rectum, red, inflamed, and covered with a thick layer of mucus tinged with blood.

There were some recent adhesions on the posterior part of left lung; a small quantity of fluid in the pleural cavity; the lower lobe semi-solid, and filled with blood and serum; right much the same, but no pleuritic adhesions; trachea red and inflamed. Remaining organs appeared healthy.

This case is interesting as regards the attempt to swallow this corrosive poison in a solid form, and the small quantity which,

Digitized by Google

if it reached, could have been retained in the stomach, for all the matters vomited, with the exception of those before admission, were submitted to a careful examination, in which I had the assistance of Mr. Blyth the dispenser, and we failed to detect the slightest trace of any salt of mercury: and still how characteristic were the post-mortem appearances of the poison taken, and how small the surface affected, supposing none to have been retained by the stomach, which most probably was the case, as there never was the slightest pain over that region, nor any mercury or salt of it detected in the matters vomited after he was brought to the hospital.

Mr. J. W. Trotter, 19*th of May*, 1853.

11.—*A specimen of Intestine in Typhoid Fever.*

Taken from a young man who died of intestinal hæmorrhage at about the twentieth day of the above disease. Diarrhœa had been profuse; and after losing about four pints of blood in small quantities, at frequent intervals, he sank and died. The solitary glands of the cæcum were much ulcerated; but some of the upper agminate glands were quite healthy. No large vessels were laid open by the ulceration.

Dr. Brinton, 19*th of October*, 1852.

12.—*Instance of Fibrinous Deposit on the Surface of the Intestine in connection with Disease of the Kidney, &c., bearing on the theory of a Fibro-albuminous Diathesis.*

The specimen consisted of a portion of the colon, which was exceedingly thickened as to its coats, and covered as to its inner surface by a thick layer of firm, granular fibrin, which was, in most places, very firmly adherent to the intestine. The whole of the large intestine and about half of the ileum were similarly affected. The patient from whom the specimen was taken, was a woman who for ten years had been occasionally subject to general ansarca, but for a few weeks previous to her death had had cough and dyspnœa. When admitted into St. George's Hospital, her lips and face were bluish and dusky,

Digitized by Google

her pulse was feeble, and her tongue coated: the heart's impulse was great, and the systole was attended by a loud murmur, chiefly audible at the apex. The urine was albuminous, and three days after she was admitted into the hospital, she complained of pain at the cardiac region, and a pericardial friction-sound was heard. Counter-irritation to the chest, and purgatives, were resorted to. Subsequently, epistaxis and vomiting came on. About a week before her death, diarrhœa and pain in the abdomen, with dark-coloured, offensive evacuations, came on; subsequently typhoid symptoms set in, and she died one month and a few days after she came into the hospital.

Post-mortem examination.—There was found a contracted, indurated, and lobulated state of the kidneys, with adherent capsules, and but slight discrimination betwixt the cortical and the medullary portions. There was also found recent fibrin in the pericardial sac; in the peritoneal cavity, and in the pleural cavities much old adhesion. The heart was enlarged, but quite natural as to its valves, orifices, &c.

The specimen was brought forward in connexion with the subject of a general tendency to the deposit of fibrinous and albuminous elements of the blood in various textures, and on various surfaces of the body; and in like manner as we have a tendency to the deposit of scrofulous or carcinomatous matter in the body, giving rise to a so-called scrofulous, carcinomatous diathesis, so might it be said that a fibro-albuminous diathesis exists. The proposition that such a tendency, acting simultaneously in various parts of the body, may exist, was alluded to at page 356 of the Transactions of this Society for 1851–52; and its apparent frequency seems to warrant for it a somewhat prominent position in pathological considerations. It is often noticed, that in the course chiefly of asthenic disease, there is a proneness to what is called "low inflammation" of various parts of the body at the same time; and after death it is found that the vessels of the affected part have given an outlet to a substance which gets the name of "recent lymph." For the most part no actual pain is experienced, but the chief immediate symptoms are owing to the presence and mechanical

Digitized by Google

interference of fluid, which is thrown out along with the more solid parts. Ofttimes, along with the diffusion of this fibro-albuminous substance into textures, or on to surfaces, chiefly the serous ones, it may be seen that solid and massive portions, with definitely-marked outlines, exist in the viscera, and have received the name of "fibrinous blocks." These are seen not unfrequently in the spleen and kidney, sometimes in the liver, and occasionally in the heart, as shown to the Society during the last session; but the presence of these masses, which are doubtless, in the first instance, deposited in the fluid state, does not appear to be the results of, or dependent upon, an atheromatous state of the arteries supplying the organ affected; but when an atheromatous state of the arteries supplying the organ does exist, both this state and the condition of the viscera are to be attributable to a common cause; neither again can they be referred, as some have referred them, to portions of fibrin, which, on being deposited in distant parts of the vascular system, have been carried along in the circulating stream, and lodged in the affected organ or part.

The atheromatous condition of vessels so often met with, seems to be owing to the general diathesis or tendency alluded to; and, perhaps, on the whole, affords the most destructive and most important instance of this tendency. It is very formidable on many accounts, for it is probable that, in addition to the formation of aneurisms by rupture of stiffened and resisting arterial tunics, &c., and also to more general dilatations, most seriously affecting the heart thereby, it is this which gives rise, in most instances, to so-called cerebral, or spinal, or pulmonary "apoplexies," for these latter seem to be owing proximately to the rupture of minute vessels which have become rigid and inelastic; and this inelasticity appears to be the result of albumino-fibrinous elements of the blood eliminated either with the vessels themselves, or without them, and which have subsequently undergone fatty or calcareous alterations. In some cases this fatty condition may be owing to direct conversion of the tissues of the vessels, without its having passed through the albumino-fibrinous stage, so to say: but this does not always exist, as we too often find atheromatous

Digitized by Google

deposit in the walls of arteries, which is so thick and so large in quantity as to preclude the idea that its presence depends on the simple conversion of natural tissue. Various diseases and disorganisations of viscera, independent of the presence of solid parts of fibrin-like substance within them, seem to have origin in this tendency or diathesis. No better example of this peculiar diathesis can be thought of than is afforded by many forms of diseased kidney. Such disease seems to be the result of a peculiar state of the blood, under which is established a liability to the deposition of fibrin-like material within the organ, either diffused throughout its texture or deposited in solid masses in particular places; not unfrequently it invades the epithelial cells, which are seen under the microscope to be large, crowded, and full of a yellow so-called "protein-compound," which is also sometimes met with during life in the urine under the form of "fibrinous casts."

The liver, again, affords a common instance of the same deposition; the frequent induration, the consolidation, and cirrhosis, or knotted condition, being, doubtless, owing oftentimes to the presence of fibrin. As an exhibition of the same tendency, we have also the opacity and thickening of the various capsules and membranes within the body; as the capsule of the liver; of the spleen; of the cornea, forming "arcus senilis;" patches of opacity on the pleural and pericardial surfaces; thickening and opacity of the membrane forming the endocardium and valves of the heart; also old adhesions of various membranes.

The same idea of a tendency to the deposit of fibrin in various parts of the body is contained and dwelt upon by Dr. Handfield Jones, in a paper on "Cholagogue Medicines," read before the Medico-Chirurgical Society not long ago, in which he speaks of the stiffening of various membranes, and certain liver-diseases as resulting from it.

Dr. J. W. Ogle, *7th of December*, 1852.

Digitized by Google

13.—*Internal Strangulation, caused by adhesion of the Vermiform Process to the Ovary.*

The subject of this case was a woman forty-six years of age, who was admitted into St. Thomas's Hospital under the care of Dr. Bennett, suffering from symptoms of indigestion, with constipated bowels. She had led an intemperate life, and had been the subject of stricture of the rectum for some time. Ordinary remedies having failed to afford relief, the rectum was examined, and a stricture, that would not admit the point of the finger, was discovered, about an inch from the anus. Small quanties of fæcal matter were brought away by injections, the greater portion, however, escaping by a fistulous communication with the vagina. The abdomen became considerably distended, somewhat tender, but not tympanitic, and there was stercoraceous vomiting. No local swelling, hardness, or tenderness of the belly could be detected; and as a sufficient cause for the obstruction of the bowels, which had now existed some days, was supposed to have been detected in the rectum, the question was mooted, whether it would not be right to seek for relief by making an opening into the colon from the loins. The general powers, however, suddenly failed, and she sank on the fourth day from her admission into the hospital.

Post-mortem examination.—The great omentum was firmly adherent in the iliac and hypogastric regions; and on tearing it away, a quantity of thin fæcal matter escaped into the abdominal cavity. The surface of the intestine, especially the ileum, was congested; the congestion was capilliform, and most marked along the line at which contiguous coils of intestine separated from one another. The whole of the small intestine, and especially the ileum, was loaded with fæces. The right ovary was converted into a cystic tumor about as large as a duck's egg, to the upper part of which the extremity of the vermiform appendage was adherent. The vermiform appendage formed a loop around the upper part of the ileum and commencement of the ascending colon, cutting these off to a certain extent from the remainder of the intestines. The

Digitized by Google

constriction around the ileum, however, did not seem to have obstructed the bowel materially, as all the intestine between that point and the commencement of the colon was loaded with liquid fæces. The colon seems to have been latterly impassable, as the intestine beyond it was empty, and the cæcum itself distended by its contents to a very large size. The interior of the cœcum was softened and congested, and in some places very much thinned; in fact it was from this part that the fæces had escaped; the actual perforations seemed, however, to have been caused by the tearing away of the great omentum. At about an inch from the anus, and extending for an inch upwards, there was a stricture of the rectum; at this part the circumference measured an inch and a quarter. In the whole of the strictured part, the mucous membrane appeared to be covered by a rough layer of false membrane, the upper margin of which was sinuous and well-defined, but the lower gradually lost itself on the mucous membrane. Just above this was a small perforation which communicated with the vagina; its direction was downwards and forwards, and it barely admitted a probe. The vagina appeared healthy, with the exception of two very minute orifices in the posterior surface, about an inch below the os uteri, which communicated with the rectum. The uterus and the left ovary were healthy.

Dr. Risdon Bennett, *7th of December*, 1852.

14.—*Intestinal Obstruction; Operation for Artificial Anus.*

Mr. Shaw exhibited the colon with an adhering portion of jejunum, from a patient who had died from obstruction of the bowels. He was a labourer, aged sixty-three, admitted into the Middlesex Hospital on the 24th of December last, under Dr. Seth Thompson. Three weeks before admission constipation began, and he had recourse to purgative medicine; at first, the motions were of the usual consistence and size; latterly, they were semi-liquid and scanty; since the 18th, he has had no evacuation, although he has taken repeated purges, including croton oil: on the 21st, stercoraceous vomiting commenced, and still continues. (On admission.) His countenance is

Digitized by Google

anxious, and of a yellow pallid hue; pulse 120, weak; tongue, brown and dry; abdomen, protuberant and resonant; the tenderness on pressure slight; notwithstanding the tympanitic condition, dulness could be detected in the region of the cœcum and ascending colon; the pain and tormina have been felt chiefly at this part. On closely questioning him as to whether he ever had any severe attack of his bowels, he answered distinctly in the negative; merely adding that many years ago he had passed blood at stool with heat and soreness, as if from piles. The quantity of urine has been the same as usual. A stomach-tube was passed its whole length by the rectum without obstruction, and the water injected returned uncoloured and without fæces. Four grains of calomel, every four hours, for four doses, were prescribed; but no evacuation followed, and the stercoraceous vomiting continued.

On the following day (25th), Mr. Shaw saw him in consultation. A warm bath for half an hour was ordered; afterwards, three grains of opium, to be followed by two grains, two hours subsequently, and to have at night three grains of calomel with one of opium. (26th.) The patient had now had total obstruction of the bowels for seven days, that having been preceded by obstinate constipation, relieved only by active purgatives, for a fortnight. His general condition denoted imminent danger; and medicines had proved of no avail: it was considered that the cause of the obstruction was situated in the great intestine, somewhere above the sigmoid flexure, and it was agreed upon that the patient's best chance of recovery lay in performing the operation for artificial anus, by opening the colon in the right lumbar region. Accordingly, after laying the patient on his left side over a pillow, Mr. Shaw first made an incision through the skin four inches long, commencing an inch from the spinous processes of the vertebræ, and carrying it an inch above the crest of the ileum; he then divided the abdominal muscles near the quadratus lumborum, until some fat protruded, which served as a guide for enlarging the incision forwards; the points of the fingers were now used to clear the loose and fatty cellular membrane from off the bowel, by which means an oval portion, an inch and a quarter in its long, and three

Digitized by Google

quarters of an inch in its short, diameter, was exposed to view. To facilitate the introduction of the sutures intended to secure the bowel to the sides of the wound, an attempt was made to pinch it, and draw it gently outwards by forceps; but as, owing to the tension of the bowel, that could not be done, it was transfixed directly with the curved needle carried in a *porte-aiguille*, and sutures placed above and below; as soon as the first needle pierced the bowel, a violent rush of flatus took place through the puncture. A crucial incision was made in the intestine, large enough to admit a finger, when more flatus, and half a porringer of liquid fæces escaped; in the course of the day and night, a small additional quantity of fæces, of firmer consistence, was discharged into the poultice. The patient did not rally, but died on the following forenoon.

Post-mortem examination:—The small intestines were distended, chiefly with flatus. There was increased vascularity in the peritoneum generally, but an absence of recent inflammatory effusion. Along the great intestine, from the caput coli, to the beginning of the descending portion, were numerous adhesions, uniting it to the abdominal parietes, the omentum, liver, and adjacent small intestines: it was obvious from their firmness that they were of old standing. On separating the transverse arch from a fold of small intestine, the walls of the colon were so attenuated at the point of adhesion, that they readily tore. The caput coli was unusually capacious, but empty and flaccid; the ascending colon also was empty. On tracing the latter to its highest point, it was seen to return abruptly upon itself, and then descend downwards as far as the caput coli, and the two portions lying parallel were firmly united by lymph to each other and to the adjoining parts. After forming this loop, the colon ascended, and followed its usual course. A considerable quantity of solid fæces was contained both in the doubled part and for some extent in the transverse arch. The bowel having been slit open, the internal surface, from the cœcum to the beginning of the descending colon, was found, in numerous places, rugged and deeply pitted from former extensive ulceration of the mucous membrane. The irregular circular patches varied in depth and size in different

Digitized by Google

parts, but they were most abundant in the cœcum, where scarcely a square inch was sound; and they gradually diminished till they were rare in the transverse arch. The edges of the ulcers being rounded and smooth, the centres cicatrized, and there being an absence of pus, or of increased vascularity, it was obvious that the active stage of ulceration had existed a long time ago: and it is also probable that the adhesions between the colon and the adjacent parts were contracted at this time. On further examining the interior of the colon, a little beyond the caput, at a point where a fold of jejunum adhered, a ragged opening was seen, in the centre of one of the cicatrized ulcers, and through this hole the finger passed into the jejunum. That a communication had existed during life between the great and small intestines by this orifice, was proved by there being feculent matter in the jejunum, while none was found in the ileum: from the edges being torn and irregular, it was conjectured that it had been produced by the walls, weakened by the previous ulceration, having suddenly burst when the colon became over-distended. Notwithstanding the presence of so many cicatrized ulcers, no actual stricture was found in the colon. The cause of the fatal obstruction was evidently to be traced to the loop formed on the ascending colon, and to the aditional effect of over-distension of the bowel above, in contracting the calibre of the canal at that part. It may be understood that, so long as the caput coli and the part of the colon intermediate between it and the loop, were but moderately filled with fæces, the diameter of the intestine at the flexure would not suffer material diminution—it would be open and movable, to allow the contents to pass freely; but it will likewise be seen that when, from accidental accumulation either of fæces, or of flatus and fæces together, the ascending colon became dilated, this expansion would be attended with a dragging upon the angle of the loop, as a fixed point; and the consequence of that tension would be an increase in the acuteness of the flexure, and a contraction of the calibre of the bowel, sufficient to produce obstruction of the fæces at that point. Owing to the firmness of the adhesions of the caput coli to the abdominal parietes,

Digitized by Google

the relations of the peritoneum to the wound made in the operation, could not be correctly made out; but it was evident, from what was seen, that the opening in the intestine was at a safe distance from that membrane.

Accordingly, as to the mode of death of the patient, it may be inferred from the post-mortem appearances that, owing to the sudden coiling and close adhesion of the folds of the ascending colon, the fæces were propelled through the commencement of the great intestine with difficulty; that, at length, an accumulation took place in the caput coli, and for some distance beyond; that the over-distension of the bowel, consequent on this accumulation, gave rise to a narrowing of the canal at the loop, so great as to produce total obstruction; that when the colon was thus over-stretched, a previously ulcerated part of its coats adherent to the jejunum gave way, forming a communication between the great and small intestines, and that then stercoraceous vomiting commenced; finally, that it was owing to the great intestine above the obstructed part emptying itself directly into the jejunum, that so small a quantity of fæces was evacuated at the artificial anus.

Mr. SHAW, *4th of January*, 1853.

15.—*Rupture of the Jejunum and Laceration of the Mesentery.*

A debauched and drunken man of sixty having been knocked down by a cab which ran over his right leg, was admitted into St. Thomas's Hospital, with a fractured fibula.—January 12th, 6 P.M.

15th, 4 P.M.—The belly is somewhat tender, and swollen with flatus; tongue foul; pulse not disturbed. It appeared that he had complained slightly of belly-ache at times since his admission, but not in a manner, or with general symptoms, to cause any apprehension of serious injury. The house-surgeon had ordered him hot fomentation, and afterwards (at intervals) several doses of aperient medicine, none of which had operated. He was now ordered a large glyster, and a mustard poultice over the belly.

16th. Had had three full evacuations during the night,

Digitized by Google

including a large number of lumps of fæces, when (10 A.M.) stercoraceous vomiting set in. (2½ P.M.) Pulse 100–106, occasionally intermitting; abdomen generally tender and tight, especially in left lumbar region, when pressed from behind. Leeches were applied to this part, calomel and opium given internally, and stimulants used as often as the state of pulse seemed to require it.

17th, 8 A.M.—The stercoraceous vomiting, which had been stayed for eighteen hours by opium, began again. Pulse 120, failing. Died in the night, more than five entire days after the injury.

On *post-mortem* examination, it was found that the jejunum had been ruptured, and that considerable fæcal effusion had taken place in the left lumbar and hypochondriac regions, where it was circumscribed by recent peritoneal adhesions. The mesentery, near the termination of the ileum, had also been torn from its attachment to that intestine for an extent of four inches. No blood was effused in the cavity.

The remarkable point in this case was the entire absence, during some days, of any symptoms which could lead to the suspicion of so deadly an injury as was afterwards discovered. There was no collapse, vomiting, or severe pain at the time of his admission, and he continued for some time taking the ordinary diet of the ward.

Mr. SIMON, *18th of January*, 1853.

16.—*Ulceration.—Stricture.—Perforation of Small Intestines.*

The specimens exhibited were taken from the body of a widow, thirty-two years of age, and well-illustrated the extreme effects of ulceration in the small intestine. The ileum and lower part of the jejunum presented numerous ulcers, mostly cicatrizing. At the commencement of the ileum a cicatrix had formed, reducing the calibre of the intestine to such a degree, that the point of the little finger could barely be inserted. Below the seat of stricture, the ileum was contracted; above, considerably dilated; and in the pouch thus formed, lay three plum-stones, which had evidently rested there for some time.

Digitized by Google

The mucous membrane in their neighbourhood was ulcerated, and there was a sloughy opening, three or four lines in diameter, which communicated with the abdominal cavity, and had caused the extravasation of fæcal matter and consequent peritonitis, of which the patient died. It seems probable that the plum-stones had renewed, or rather kept up, the ulcerative process, and that to their presence is to be attributed the comparatively early fatal termination of the disease. The muscular coat at and above the stricture, was much hypertrophied, being about a line in thickness; but the chief increase was in the sub-serous tissue, which, opposite the stricture, was an inch thick, but gradually diminished upwards, and with the muscular tunic, resumed its natural dimensions about three or four inches from the seat of mischief. The intestinal parietes below the stricture were unaltered. At the lower part of the ileum two contiguous portions of the gut had become firmly adherent, and a small communication (one admitting readily of the passage of a director) had formed between the two. The remains of ulcers existed in the neighbourhood of either orifice; opposite these, and indeed most of the larger cicatrizations, the calibre of the intestine was somewhat reduced, and the walls slightly thickened. Throughout the large intestines were numerous cicatrizing ulcers. The mucous membrane was softened throughout, and in the sigmoid flexure and rectum, patches and longitudinal bands presented almost a sloughy condition. There were a few chalky concretions in the apices of the lungs, but no recent tubercle. The history of the patient did not throw any great light on the case. She was in the hospital a week under Dr. Bennett's care, labouring under peritonitis, the result of perforation. She stated that for some years she had been liable to sudden attacks of pain in the abdomen, with constipation, which, after continuing for a time, were often relieved by the occurrence of diarrhœa. No allusion was made to any decided attack of fever or dysentery in which the disease could have originated. Dr. Bristowe was inclined to believe that it was the result of an attack of typhoid fever.

Dr. Bristowe, 18*th of January*, 1853.

Digitized by Google

17.—*Villous Cancer of the Large Intestine.*

Mr. Birkett exhibited a portion of the colon, developed upon the mucous membrane of which was a vascular villous growth, which, with a contracted state of the bowel, had produced insuperable constipation.

A man, aged fifty-eight, a country labourer, was admitted on the 16th ultimo by Dr. Babington into the clinical ward of Guy's, where the clerk, Mr. Marriott, obtained a full report of the case, an abstract of which is as follows. He was a healthy man, of temperate habits and apparently well nourished, but the last few months he has not enjoyed his accustomed good health. He was the subject of oblique inguinal scrotal hernia on the right side, for which a truss was worn, and which had never been strangulated. Twelve months since he had severe diarrhœa, sickness, and great pain over the whole abdomen; the diarrhœa ceased, but the attacks of sickness and pain have recurred at intervals ever since. He has become emaciated, his bowels have been irregular in their action, sometimes costive and again relaxed. Defæcation was performed without difficulty. At Christmas last his sufferings became aggravated, and as he did not obtain relief he sought admission into Guy's. He complained of dull, aching pain over the whole abdominal region, which was most severe in the right hypochondrium and below the umbilicus, where there was tenderness on pressure. At the umbilical ring there was a slight fulness, but no hernia. He had constant nausea, frequent vomiting every two or three hours, and always after taking food. Insuperable constipation had existed a week, and his abdomen was tense, though not tympanitic. There was a swelling in the right inguinal canal, but no hernia could be detected. Calomel and opium (of each one grain) were given every four hours.

Two days after admission a consultation was held by Dr. Babington, Mr. Cock, and Mr. Birkett, when the propriety of exploring the swelling in the groin was decided upon, in the hope of finding a small portion of strangulated ileum at the internal ring. This operation was performed by Mr. Birkett,

Digitized by Google

Digitized by Google

DESCRIPTION OF PLATE IV.

FIGS. 1 and 2 illustrate Mr. Birkett's case of villous cancer of the large intestine. Page 154.

Fig. 1 shows the constriction of the colon, and the villous growth (*b*) projecting towards the anal end of the bowel (*a*).

Fig. 2 represents a vertical section of the colon and villous growth, and the relations of the new growth to the coats of the bowel; (*c*) being the peritoneum, (*d*) the contractile coat, and (*e*) the mucous membrane.

The mucous membrane above the growth was loose and convoluted (*f*), and assisted to form a valvular obstruction.

Digitized by Google

Fig 1

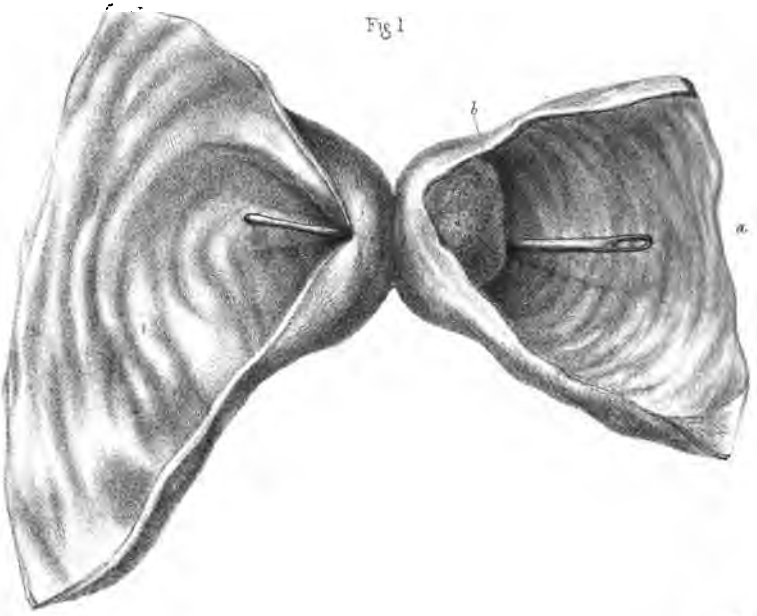

Fig 2

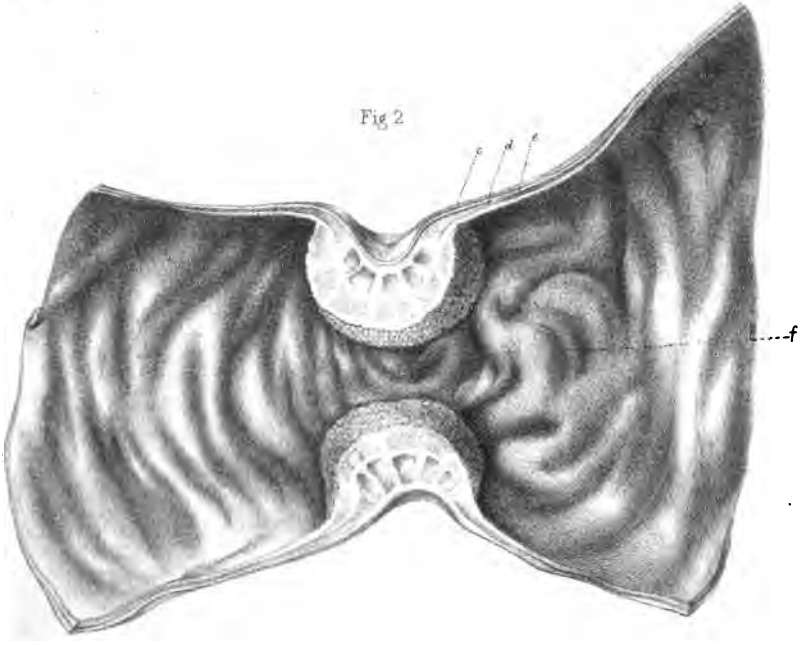

Digitized by Google

Mc Hurst del Tuffen West lith

Ford & West Imp 54 Hatton G

Digitized by Google

but an old hernial sac very much thickened, containing serum, was alone discovered. By the introduction of the finger at the internal abdominal ring, the small intestines could be felt to be greatly distended.

In the evening of that day he seemed to be relieved, but the next morning he was worse; and in the afternoon, as there had been no remission of symptoms, and the constipation continued in spite of a copious enema injected with a long tube, the propriety of opening the ascending colon in the loins was discussed by Dr. Babington, Mr. Cooper, Mr. Cock, and Mr. Birkett. When the patient was lying on his back there was distinct fulness in the region of the cæcum and ascending colon; flatus could be detected in the arch of the colon, but the site of the descending colon was not indicated. The man had vomited an immense quantity of fæcal matter since the operation. The seat of obstruction seemed to be limited to some spot between the ascending and descending colon. The patient was placed in a position for opening the ascending colon, but in the right lumbar region there was no fulness, nor did any sufficient indications exist to admit of the performance of the operation. Four grains of powdered opium were immediately given, and that evening another grain was ordered, and continued every two hours. He became, however, weaker and weaker, and died on the fourth day, or about ninety-four hours after admission.

Sectio cadaveris, sixteen hours after death. — Body emaciated; tissue of lungs generally healthy; recent peritonitis existed; several small tubercles, one quarter of an inch in diameter, were noticed in the great omentum, probably carcinomatous; the entire length of the small intestines was greatly distended with fluid fæces, as well as the cæcum and ascending colon; the arch, descending colon, and rectum, contained a little flatus and a few scybala. The right flexure of the colon was constricted, as if a piece of string had been tied around it. Within this constricted part a growth was seen attached to the anterior wall of the bowel. (See Plate IV., figs. 1, 2.) This was of the nature described by Rokitansky, Gerlach, and Schutz, under the name of "Zottenkrebs,"—villous cancer. The mass

Digitized by Google

consisted of vascular villi, formed of a fibre element, and invested with columnar epithelium. (Plate III., figs. 8, 9, and 10.) The other viscera were tolerably healthy. No cancer was discovered elsewhere. The drawings were made by Mr. Hurst. Mr. BIRKETT, *1st of March*, 1853.

18.—*Almost complete Obstruction of the Small Intestine from injury.*

The preparation was taken from the body of a man aged forty-five, who died at the Charing Cross Hospital, under Dr. Rowland. On the 18th of September, 1852, a waggon, heavily laden with sacks of wheat, passed over the lower parts of his chest and epigastrium. He was carried, in a very low condition, into the nearest public-house, where he remained the night. On the following day, though with considerable difficulty, he managed to walk home,—a distance of three miles. He subsequently suffered much pain and disturbance in the belly, sought advice on several occasions, without obtaining relief, and ultimately applied to Dr. Rowland at the hospital, where he was admitted on the 31st of December, 1852. He complained of much pain; the abdomen was distended; and he was troubled with frequent violent spasmodic contractions of the intestines, which were seen through the parietes in knots, which in a few seconds subsided, whilst similar elevations presented in different regions of the abdomen. The pains were not constant; indeed, all the symptoms were occasionally much relieved: sometimes he was able to get up, feeling pretty well. The bowels were at times very loose, at others confined; and then, on several occasions, he was attacked with stercoraceous vomiting, and other signs of almost complete obstruction. Three or four days before his death, acute peritonitis came on, and quickly proved fatal. He died eight weeks after his arrival at the hospital, and more than five months after the injury. The cavity of the peritoneum contained a considerable quantity of a muddy, flaky fluid, and the convolutions of the intestines were everywhere agglutinated to one another by soft lymph, which was readily broken down by the finger. The omentum

Digitized by Google

formed a very short apron, and terminated, on the left side, in a round cord, as large as the little finger. This cord passed over a large mass of small intestines, then dipped underneath them, and in its passage embraced the two extremities of a convolution so firmly, as to all appearance to prevent the passage of any thing through them. The cord was then found to be firmly attached to the free edge of another of the small intestines; and just opposite to this attachment, there was an irregular opening, as if torn, in the mesentery, as large as a shilling, and the edges of which seemed to have only recently healed. Between the attachment of the cord and the opening in the mesentery, the calibre of the small intestine—three or four feet from the termination of the ileum—was so reduced as scarcely to admit a crow-quill. Above the contracted opening, the entire mucous membrane was removed by ulceration for the space of an inch; the other coats were considerably thickened and amalgamated by inflammatory deposit for some distance upwards, and all appearance of valvulæ conniventes had disappeared. Around the obstruction, the coats of the bowel did not feel indurated, but seemed as if they had been torn or separated, and as if lymph or blood had been effused and had become organized. A very careful examination failed to find any ulcerated opening communicating with the cavity of the peritoneum. Had an operation for the relief of obstruction of the bowels been deemed necessary, this case would have added another to the many complications already found in connexion with obstructing bands, and the operator would certainly have contented himself with dividing the cord that pressed on this convolution, and only found the real obstruction at the post-mortem examination.

Mr. Avery, *15th of March*, 1853.

19.—*Deposit of Tubercle in the Peritoneum and Fallopian Tubes.*

The specimens were removed from the body of a young unmarried woman, a servant, twenty-five years of age. The small intestines and transverse colon adhered to one another

Digitized by Google

so as to form one mass, which was closely attached, partly through the intervention of the great omentum, to the abdominal parietes in the umbilical and left lumbar regions. At the bottom of this mass was a circular perforation about half an inch in diameter, which communicated with the ileum near its middle. The remainder of the abdominal cavity was filled with a puriform fluid mixed with liquid yellow fæces, and contained likewise a small quantity of fœtid gas; its parieties, including the surfaces of the viscera projecting into it, were lined by a layer of recently deposited lymph. The parietal peritoneum beneath this, was found in many places to present tubercular deposits, either as separate nodules, or as layers of various extent, formed apparently by the confluence of pre-existing nodules. On separating the small intestines from one another, their surface, that of the mesentery, and the adhesions themselves, were found to be studded with tubercles, varying from mere points to the size of a pea: the smaller ones were more or less globular; the larger were irregular, and formed probably by the union of several smaller ones. They were somewhat firm, of an opaque yellowish-white colour, marked and spotted with black. The black colour preponderated in the smaller ones, which but for this circumstance might have escaped observation. The tubercles were most numerous in the line of junction between the mesentery and intestine. There was no deposit in the mesenteric glands, and no ulcers or other affection of the mucous membrane of the bowels, except at the spot in which perforation had taken place. The history proved that the perforation occurred but a short time before death, yet the autopsy did not certainly reveal its cause, though, most probably, it was produced by ulceration beginning on the mucous surface.

The left Fallopian tube and ovary were accidentally lost sight of; the right tube, in its outer two-thirds, was distended to a considerable size by a copious deposit of soft yellow tubercle. The mucous membrane of the uterus was soft and pulpy, but not tubercular. The right ovary was healthy. The lungs were studded with miliary tubercles. The cavities of the pleura were obliterated by old membranous adhesions; and that

Digitized by Google

of the pericardium, by a recently-deposited layer of fibrin; but in neither case was tubercle connected with the adhesions.

The deposit in the Fallopian tubes consisted of what appeared to be broken-down cells, or rather nuclei, mixed with molecular matter, probably the débris of epithelium; that in the peritoneum presented a large number of irregular, interlacing fibres, obscured by abundant granular matter and oil, but nothing that could be positively said to be even the remains of cells or nuclei.

The above case is a counterpart of one which Dr. Bristowe brought under the notice of the Society during the previous session, and which was reported on by Drs. West and Brinton. The microscopic examination of this case agrees pretty closely withthat of the former one, as furnished by the latter gentleman, but Dr. Brinton inferred, both from the microscopic and the more obvious characters, that neither the deposit in the Fallopian tubes nor that in the peritoneum was entitled to be called tuberculous, an opinion which was combatted at the time, and from which Dr. Bristowe totally dissents; indeed both in that and in the present instance he believes the deposit to be strictly tuberculous. Dr. Bristowe, 21*st December*, 1852.

20.—*Primary Scirrhus of the Peritoneum.*

W. C., a porter, aged forty-one, of middle stature, and somewhat emaciated, was examined on the 15th of February, 1853.

The peritoneal cavity contained about three pints of clear straw-coloured serum, and its surface was almost everywhere infiltrated with cancerous deposit; this was particularly observable in the great omentum, which was thickened, contracted, and adherent to the parietes in front, in the appendices epiploicæ, lesser omentum, and mesentery, the latter of which was so thickened, indurated, contracted, and folded on itself, that the small intestines were collected into an almost immovable mass. Bands and flocculi of recent lymph were tolerably abundant, but chiefly so between the liver and diaphragm. All the viscera occupied their natural position.

The cancerous material which appeared to be seated in the

Digitized by Google

substance of the serous membrane, may be described as existing under three forms, which, for convenience, I will call the papular, the confluent, and the laminar: 1st, It was deposited in the form of small lenticular spots, varying from about two lines in diameter downwards; they were greyish-white, hard, sensibly elevated above the surface of the membrane; and on tearing away a strip of the latter, were clearly seen to occupy its whole thickness, yet not to project so distinctly towards the sub-serous tissue as in the other direction: 2ndly, There were patches of variable extent, formed evidently by the confluence of these:-the smaller ones were produced simply by the coalescence of two or three; the size of the larger ones it was impossible to estimate, since they branched out and merged into one another in all directions: 3rdly, In some situations the coalescence was so complete, that all traces of the papular origin was lost; the cancerous deposit here existing under the form of a uniform lamina, which measured a line or somewhat less in thickness, was smooth on the surface, firm, greyish-white, and slightly translucent. The gradations between the three varieties above described, were insensible; a perfect lamina towards its edge passed gradually into the second form, and this as gradually into the first. No appearance of creamy juice could be detected in any part.

In the lower half of the parietal peritoneum of the anterior walls of the abdomen, the deposit was least abundant, and existed in the papular form, intermixed with a few small confluent patches. In the upper half and in the whole of the diaphragmatic portion it was abundant, and the confluent condition, in some parts, almost passing into the laminar, prevailed. The suspensory ligament of the liver was thickened, in some places, to nearly half an inch; and infiltrated with scirrhus. The peritoneal covering of the liver was perfectly healthy, with the exception of a few minute papulæ in the neighbourhood of the attachment of the suspensory ligament and of the gastro-hepatic omentum. The latter was equally affected with the suspensory ligament, and the deposit extended from it into the smaller cavities of the stomach, where it was very abundant, and chiefly in the confluent condition; the anterior surface was

Digitized by Google

but slightly affected, and presented only a few scattered papulæ; they again, however, became abundant and confluent at the greater curvature. The great omentum was much indurated, thickened between half an inch and an inch, and contracted so as to measure nowhere more than 2½ inches long: its lower margin was very irregular and lobed; its entire surface was nodulated, very vascular, and thickly studded with projecting granules and tubercles of an opaque yellowish hue. On section, it was seen to consist of a firm, greyish, slightly translucent substance, evidently scirrhus, interspersed with the yellowish masses just mentioned, which were clearly the remains of the original tissues, and chiefly of the fat; the transverse colon was, as it were, firmly set in its posterior part. The peritoneal surface of the entire colon was studded with small, distinct papulæ, which became confluent or laminated at the bases of the appendices epiploicæ, and at the line in which the peritoneum became reflected from the intestine. The appendices were peculiarly transformed; they formed along the whole gut a string of adherent sigmoid bodies, from the size of an almond to that of a bean; they were plump, firm, granular on the surface, and consisted of a thick capsule of laminar scirrhus enveloping a mass of fat. The scirrhus sent septa for some distance into the substance of the fat: the fat extended in many places through the scirrhus to the surface, where it formed yellow, projecting nodules. The peritoneum passing back from the colon, in its entire length, close to the spine, was converted into a dense, uniform cancerous lamina, a line in thickness; this extended to the mesentery, which, in its whole extent, was similarly diseased; it consisted of two laminæ, separated by the proper vessels, glands, fat, &c.; at the intestinal attachment the laminæ coalesced; the malignant deposit was thence prolonged into the intestine, passing through the laminated and confluent into the discrete condition, which alone existed on the half opposite the mesenteric attachment. The anterior layer of the ascending and descending meso-colon was infiltrated with laminated cancer, which, at a distance of one or two inches from the gut, passed into the confluent form. The surface of the spleen was

Digitized by Google

nearly healthy, the gastro-splenic omentum was contracted and cancerous. The cavity of the great omentum was separated from the rest of the peritoneal cavity by adhesions; it was about as large as an orange, and filled with serum; its entire surface was affected like that of the peritoneum generally; that covering the posterior part of the stomach was least diseased. All those portions of the viscera that were uncovered by peritoneum, were healthy.

The *liver* was of ordinary size, of a uniform reddish-brown colour, from slight but uniform congestion; there was no evidence of its being fatty or in any other abnormal condition: the bile in the gall-bladder was of a dark greenish hue.

The *spleen* was of natural size, moderately dark, and somewhat firmer than usual.

Pancreas healthy.

The *mucous membrane* of the stomach and intestines was everywhere healthy; their contents were a dark green fæcal matter; in the stomach and upper part of the small intestines thin and watery, in the remainder semifluid, or nearly solid. The muscular coat of the right half of the stomach was much increased in thickness; it gradually thickened towards the pylorus, where it measured a quarter of an inch, yet the disease in the serous membrane was almost less marked there than in other parts of the viscus; neither was there any deposit in the hypertrophied muscular tissue; the mucous membrane throughout was healthy, though thrown into folds and somewhat thick. The œsophagus was much dilated, its circumference measuring three inches.

The *kidneys* were healthy.

The muscular tissue of the *diaphragm* was more or less affected with cancer, and the diaphragmatic pleura of each side was thickly covered with cancerous papulæ and confluent and laminated patches; discrete spots of small size were scattered on the costal portion for about two inches from the base upwards; but none were found in any other part of the pleuræ, and there were no adhesions. The *lungs* were healthy, and without trace of tubercle. The *pericardium, heart, brain*, and other organs, were healthy. No appearance of cancer was

Digitized by Google

discovered in any organ or part of the body but the peritoneum, diaphragm, and pleura.

The cancerous deposit was examined microscopically, and from whatever part taken, presented the same characters. It consisted of a dense fibrous matrix, every now and then hollowed out into circular or oval spaces filled with nucleated cells. On the addition of acetic acid, the fibrous tissue became transparent, and exhibited numerous elongated oval nuclei and minute oily molecules more or less clustered. The cells were unacted upon, and consequently became more conspicuous. The cells varied in diameter from about the $\frac{1}{2500}$th to the $\frac{1}{500}$th of an inch, and contained one, two, three, or even more nuclei. The nuclei, whose outlines were exceedingly well defined, varied from $\frac{1}{3000}$th to $\frac{1}{1000}$th of an inch, and contained one or two minute nucleoli. There were likewise floating about in the field numerous fusiform cells and membraniform shreds containing elongated oval nuclei, which seemed to belong to the fibrous portion of the growth.

The patient was admitted into St. Thomas's Hospital, under Dr. Goolden's care, on the 5th of February, complaining of great pain in the abdomen, with constant vomiting; these symptoms continued in spite of treatment, and he died in about ten days; during this time his bowels were irregular, latterly much relaxed, and he passed large quantities of thick black, or dark greenish fluid. His illness commenced a month before, with pain in the abdomen, but he continued at his work for three weeks. He suffered from a somewhat similar attack eighteen months ago. He had had syphilis; his mother died of phthisis.

The foregoing description is quite sufficient, I conceive, to prove that this disease is scirrhus. It has the microscopic as well as the naked eye characters of that affection and the mode of growth; the way in which it attacked the diaphragm and extended to the pleura is equally characteristic. The case is interesting as an example of a very rare form of disease —primary scirrhus of the peritoneum. Recognising the distinctions that exist between the two forms of malignant disease, scirrhus and encephaloid, it is interesting to observe

Digitized by Google

how pre-eminently apparent these distinctions become when the seat is the serous membranes, even if the usual points of difference be disregarded. Thus, when encephaloid attacks a serous membrane, its tendency is to form outgrowths—soft, pulpy, pedunculated excrescences, varying from a mere point to the size of a child's head. In scirrhus, on the other hand, the tendency is not to produce outgrowths, but to infiltrate the tissue, to cause thickening, contraction, and induration. In connection with the vomiting, it is worthy of notice, that the muscular tissue of the pyloric half of the stomach was hypertrophied and the œsophagus dilated. The former alteration, and indirectly the latter, would seem to show that though there was no actual impediment to the passage of food along the duodenum, a virtual obstruction existed, probably in the contraction caused by the scirrhous infiltration.

Dr. Bristowe, *1st of March*, 1853.

21.—*Calcareous Concretions of the Peritoneum.*

This specimen was purchased at the sale of the preparations of the late Mr. Langstaff, and was described in the catalogue, as "A portion of peritoneum dried, showing osseous concretions." Nothing appeared to be known of the history of the case.

The peritoneum is thickly studded with hard, dry, nodulated, irregular shaped bodies, varying in size from a pin's head to a pea; they are covered with a delicate layer of serous membrane. On striking them against glass, a ringing, metallic sound is produced. On immersion in dilute hydrochloric acid, a portion of the body is dissolved, leaving fibrous divisions in the interior.

Dr. Crisp said, he had made a thin section of the hardest part of some of the concretions; and under a power of 250 diameters, it appeared to consist chiefly of irregularly-shaped granules, presenting no appearance of organization. On comparing these with sections of bony deposit from other parts which were on the table, including an osseous tumor of the uterus, eggshell-like deposit on the theca of the spinal cord,

Digitized by Google

bony tumor on the tendon of a horse, a phlebolithe from one of the pelvic veins of the human subject, and bony deposit from the aorta of a woman eighty-eight years of age, a great resemblance was observed,—all consisting of irregularly-shaped granules, without any appearance of bone-cells, canals, or lacunæ.

The eggshell-like deposit, however, contained much fibrous tissue; and the smaller patches had a stellate form; the cretaceous projections, when magnified about forty diameters, having the appearance of the tentacula of some of the actiniæ.

Dr. Crisp believed that the specimen of calcareous concretions of the peritoneum was unique, although calcareous deposits in this membrane had been sometimes met with in the form of patches: the ossific matter being of a flattened shape.

Dr. Crisp, *5th of April*, 1853.

22.—*Numerous Abscesses in the Liver, associated with Ulceration of the Portal Vein.*

J. W., aged fifty-five, a labourer, was admitted on the 17th of September, 1852, into St. Mary's Hospital, under the care of Dr. Alderson. Some weeks previously he had been in the hospital, under Mr. Coulson, for an ulcer of the leg. About seventeen days previously he was seized with shivering; and shiverings recurred several times in the course of the following days, and continued occasionally up to the time of his admission. From this period till his death, which took place on the 24th of October, cold shiverings, followed by great heats and profuse perspiration, were the prominent symptoms; now and then the febrile action seemed to remit for a few days, but the attacks were always renewed, and with increased violence—under them he at length sank. About fourteen days after his admission, he became thoroughly jaundiced: the liver was felt to be much enlarged. He did not appear to have complained of any pain over the right side until a few days before his death; this pain was caused by an attack of pleurisy.

Post-mortem examination.—The lungs adherent posteriorly

Digitized by Google

by old attachment; a very slight deposit of lymph at the lower border of the right lung, (friction-sound had been heard there).

The *liver* was much enlarged, and dark coloured; in removing it from the body two or three ounces or more of purulent matter, tinged with bile, escaped from the portal vein, the liver shrinking sensibly under the hand at the same time. A section showed that abscesses were everywhere distributed through it, of every size, from a pea up to a large walnut. They, as well as the portal vein, and its branches, were filled with purulent matter: the hepatic ducts and veins appeared healthy.

The *portal vein*, near its entrance into the liver, was found ulcerated to the extent of an inch or more; the ulcerated edge being well-defined. The ulceration had destroyed the internal and part of the middle coats of the vein. The other organs were healthy. The substance of the liver, examined by Mr. Blyth, contained neither sugar nor cholic acid; and the bile, no cholic acid.

Dr. H. Jones found that the cells were natural, and that the central half of the lobules was loaded with yellow pigment.

The veins of the leg, on which the ulcer had been situated, were perfectly healthy.

Dr. MARKHAM, 22*nd of November*, 1852.

23.—*Hæmatoid Crystals in an Hydatid Cyst of the Liver.*

The left lobe of the liver contained an hydatid cyst as large as an orange; its parietes were in many parts firm, and lined by earthy deposit. The fluid in it was small in quantity, thick, yellowish, and semi-transparent. The hydatids were collapsed and yellow, and many of them were studded with opaque greenish spots. In every part of the cyst were numerous free vermilion spots the largest of which were about a line in diameter, and which clearly consisted, to the naked eye, of rhomboidal crystalline plates. Microscopic examination showed that all the vermilion points were really colourless plates of cholesterin, the surfaces of which were thickly studded with ruby-coloured, more or less

Digitized by Google

regularly rhomboidal crystals, having all the characters of those bodies usually described as hæmatoid crystals. The largest of them were about the thousandth of an inch in the long diameter. Numerous small plates of cholesterin were seen, without hæmatoid crystals adhering to them; but no hæmatoid crystals were discovered free of the cholesterin. The remains of echinococci were everywhere visible. It is worthy of remark, that though these hæmatoid crystals may have been due to byegone effusion of blood into the hydatid cyst, there was not the least evidence, beyond the fact of their presence, to indicate that such effusion had ever taken place. The patient from whom the liver was taken was a middle-aged man, who died of phthisis with ulceration of the intestine.

Dr. Bristowe, *2nd of November*, 1853.

24.—*Tumors of large size in the Liver (Medullary Cancer?) masked by and mistaken for simple Pregnancy.*

I was requested to assist at the examination of Mrs. B., aged thirty-nine, when I learnt that she was a very temperate person, never addicted to drinking, nor yet the subject of anxiety; that she had been several times pregnant, and had had some miscarriages. She had enjoyed excellent health until six months before, when she felt faint and sick of a morning, and found herself again pregnant. The abdomen enlarged considerably, and felt much more heavy than usual. The sickness was at first confined to the morning, but she could eat and retain a hearty supper; eventually it continued, she observed, much more heavily than usual, and for the last five days of her existence, nothing remained down. She experienced a sharp pain on the left side of her abdomen, for which leeches had been twice applied with advantage. She was tender when pressed upon the abdomen, but did not otherwise feel pain. The bowels were costive, the motions dark-coloured. Towards the close of her existence she had an irritation in her throat, and brought up some blood, but she had neither dyspnœa, cough, pain between the shoulder-blades, jaundice, hiccup, nor œdema; the urine was

Digitized by Google

generally scanty and high-coloured, and she died exhausted. It was supposed that she had twins.

Dissection.—Body generally excessively emaciated: abdomen very large, and occupied by two very large, irregular, lobulated tumors, very solid; and a third small lobulated tumor in the epigastrium. Thoracic viscera healthy, but encroached upon by the contents of the abdomen. The liver, of an enormous size, occupied completely both hypochondria, extended on the right side completely, and on the left nearly, to the crest of the ileum. It was converted in all parts, but one small portion posteriorly, into large medullary tumors, all of which were depressed in their centres, covered with puckered peritoneum, and exceedingly loaded with tortuous veins and some florid vessels. Many of the depressions of these tumors were filled with coagulated blood; and this separated easily from all but one, to which it remained attached. The left side of the liver was adherent to the peritoneum lining the abdominal parietes, which were in parts covered with lymph, in others with coagulated blood. There was also some fluid tinged with blood in the abdomen. The liver weighed 17½ pounds, the gall-bladder was flaccid, and contained a little green bile; the portal and hepatic veins were free from medullary deposit; spleen, pancreas, and stomach healthy; small intestines very much compressed; a few scybala in ascending and transverse colon; a softened tumor, similar to those in the liver, in the mucous membrane of the descending colon, about which the intestine was interstitially thickened. The greater part of the descending colon and sigmoid flexure much contracted from pressure, and in circumference not so large as the little finger; kidneys very much congested; mesenteric and lumbar glands free from disease. The uterus was the natural size for a six months' pregnancy, and contained a female fœtus, and much green liquor amnii. The placenta was attached to the fundus, and there was one small medullary tubercle on each side of the uterus, immediately under the peritoneal coat.

The liver was again examined, four days after it had been taken out, the arteries and veins injected, and it had been

Digitized by Google

immersed in spirits. It had lost much of its character and was undergoing putrefaction. A section was first made of the right lobe, when it was found to consist of several medullary tumors, of different sizes and consistence. The cut had a noisy, grating feel, like that on dividing a turnip. The tumors were of a pale flesh-colour; some were round, some oval: some small and some large. The smallest were all round, of brain-like consistence, and were softening; others were hard and gritty. The vessels, both arteries and veins, were most conspicuous in the left lobe, and in the spaces between the tumors, into some of which they appeared to pass. Lines, supposed to be absorbents, were clearly seen running upon the surface of the liver.

Remarks.—The points of chief interest in this case are, First, the size of the tumors. I have several specimens of the disease in my possession, but none of them have anything like the magnitude to which these attained; two of them nearly occupied the whole of the left lobe of the liver, which extended almost to the crest of the ileum.

Secondly, the coexistence of pregnancy. It is not common for pregnancy to be associated with disease like this. The ailments, therefore, which are complained of at this period, are too often ascribed to the inconveniences of this condition. This case, however, gives a caution in that respect, and shows the great importance of investigating symptoms very closely (particularly sickness) when they appear in the puerperal state. The rapid growth of the tumors is also worthy of note. It is difficult to say whether these tumors existed at the time she became pregnant, but if they did, they must have been of very small size; and no doubt, I think that their principal growth took place in the latter months of pregnancy.

The coexistence of similar, but small tumors, attached to the fundus of the uterus, is not without interest. From the great supply of blood to the uterus, it might have been supposed that these would have grown with equal rapidity with those of the liver, unless it be inferred that they were of much more recent origin, or that the rapid growth of the one arrested the growth of the other.

Digitized by Google

The suspicion of twins was very natural when there was no idea of the existence of disease; the great size she rapidly attained, the decided line of demarcation between the two sides of the abdomen, and the much greater weight she felt than usual,—all tended to strengthen that idea.

Mr. R. R. Robinson, *4th January*, 1853.

25.—*Instance of Unorganized Deposit in the Spleen, in connection with Typhus Fever.*

The deposit was of a yellowish-brown colour, soft, and consisted mainly, as seen by the aid of the microscope, of granular material, and irregularly-shaped nuclear bodies of small size, some with, and others without any contained nucleoli. The deposit was about equal in amount to a large walnut, and penetrated from the surface, where it was visible, to the distance of about 1½ inches into the substance of the spleen. The serous membrane covering it had a thin layer of recent yellow fibrin attached to it externally. The organ weighed 13 ounces, was generally congested and full of blood; its blood-vessels were natural.

The specimen was from the body of a person, aged twenty-two, who died with all the symptoms of typhus fever, for which he was treated by quinine in large doses. After death there was found ulceration of the intestinal glands of the ileum; and adherent to the mucous membrane of the trachæa was a considerable amount of unorganizable yellow deposit, like that found in the spleen. Moreover, the sub-peritoneal tissue around the abdominal vessels, low down in the abdomen, and in the pelvic region, was very dark, and as determined by the microscope, contained a quantity of granulated matter, with irregular nuclear bodies, mixed with what looked like altered blood globules. The kidneys were large and congested, weighing 14 ounces: and the blood generally throughout the body was very fluid. Such deposits occuring in typhus fever, Professor Vogel terms "typhus-deposits," and says that he is unable to distinguish them by the microscope from those bearing the name of "scrofulous," and from many others. But by this name he

Digitized by Google

does not, however, mean to imply a belief that there exists in the blood anything like a "specific typhus matter." The above specimen is not unlike one described by myself in the Transactions of this Society for the year 1851-52, (at page 384,) as having occurred in the kidney under similar circumstances.

Dr. J. W. Ogle, *2nd of November*, 1852.

26.—*Case of Lobular Hepatitis, terminating in extensive Suppuration.*

M. A. B., a married woman, twenty years of age, of regular habits, had resided in a close, but not damp, situation. Her occupation for the last six months had been sedentary, and carried on "in a very hot, close room." She seemed to have no hereditary predisposition to disease, but her health during the last few years had been delicate. Her present illness commenced six weeks before admission to the hospital. She felt faint, sick, and had lost her appetite; she occasionally in the morning had a discharge of watery fluid from the stomach; she subsequently felt some giddiness, shortness of breathing, and a general heat of surface. She was seen by a physician, who considered her ailments to be nervous or hysterical. In a day or two after, there were recognized evidences of pleurisy; this was relieved by treatment. The symptoms however, again returned, and she applied for admission into the hospital. She was then weak, and presented an anxious, worn expression. She could not lie in any other position than on her back; the surface of the body generally was pale but warm. There was a circumscribed flush on the left cheek. Pulse 126, soft; bowels regular; tongue dry, slightly coated. She complained of thirst, but had no nausea or pain in the stomach. She felt pain in the right hypochondriac region, which extended to the right iliac fossa; she had dull pain in the right shoulder. The surface of the abdomen generally felt tender; she had a short, hacking cough. The right side of the chest was observed to be distinctly larger at its base than the left. There were also present the usual signs of slight pleuritic effusion; her breathing was quick and remarkably thoracic. She had a blister applied to the side, and calomel and opium with salines

Digitized by Google

administered to her. Under this treatment she felt relieved, and the signs of pleurisy diminished. On the third day after her admission, she had some bilious vomiting. From this period to the close of her illness, her symptoms varied; her debility, with loss of flesh, increased; her cough continued very troublesome; she slept badly, but could, however, towards the close of her illness, lie on the right side; she had scarcely any appetite; her tongue was generally covered with a white fur, with a yellowish streak in the centre. She had night perspirations, and felt pain in the right side, with general tenderness of the abdomen, more or less continued. Towards the termination of her illness she had slight delirium, and passed her stools involuntarily. She died in this state on the sixty-eighth day after her admission into the hospital, having been ill altogether about sixteen weeks.

Post-mortem examination.—The body generally was pale and emaciated. In the right pleural sac there were a few ounces of effused turbid fluid: the base of the right lung was adherent inferiorly to the diaphragm, by soft but organized adhesions. The heart was pushed more to the left side than natural. There was nothing in other respects remarkable in the chest. In the cavity of the abdomen there were a few ounces of pale, straw-coloured serum. The liver projected about an inch and a half beyond the margin of the ribs at the left side; it extended, however, very considerably upwards, encroaching on the cavity of the chest, particularly behind; its upper surface was, to a considerable extent, adherent to the diaphragm; inferiorly and towards the back part it was adherent to the right kidney, and those adhesions were organized. The whole liver was large; and weighed, with the contents of the abscesses which it contained, the gall-bladder, &c., 5 lbs. 12 ounces. In the other viscera of the abdomen there was nothing remarkable. The stomach, at its cardiac end, presented patches of punctiform and striated redness. The intestinal canal was healthy. The kidneys were slightly granular, and some urine found in the bladder became turbid by heat and nitric acid.

On further examination the external surface of the liver was observed to be smooth (with the exceptions presently to be mentioned) and of a deeper tint than natural. On the

Digitized by Google

upper and back part of the right lobe, there was a distinct but slight elevation, elastic to the feel, uneven on its surface, of a yellowish pink hue; traversed by vascular lines, marking out irregular polyhedral patches. On other portions of the surface similar elevations were observed, particularly on the lower one. They were all placed beneath the peritoneum; they felt firmer and less elastic than the larger elevation just described, and their size varied from that of a pea to that resulting from the aggregation of several; their colour was more of a yellowish-buff hue than that above-mentioned. Their surfaces were marked by similar lines; the substance of the liver was everywhere softer and more fragile than that of the healthy organ. Sections made in various directions, presented appearances which may thus be classified:—

1. The deep chocolate colour of the tissue was studded in many parts with darker, purplish, minute points, which on close examination were found to be limited to the individual lobules of the organ. The appearance was evidently due to hyperæmia of the lobules, and was not very dissimilar to what is called hepatic-venous congestion. See Plate V., fig. A.

2. In several situations throughout the substance of the organ (to the number of seven or eight), buffy, yellow granulations were observed. They retained exactly the form of the lobules, but were larger and felt firmer. The tissue of the liver around these spots seemed more vascular than in other situations. In some cases, three or four of those little spots united to form a single, irregular mass, which retained the characters of the individual lobules, and from the centre of some of these, a small portion of creamy looking pus could be obtained by pressure. These appearances also are tolerably well represented in Plate V, fig. A.

3. We find larger masses still, formed by the aggregation of several smaller ones in a more advanced stage. There were three such collections, of which, one was found to be composed of a number of irregular smaller masses, separated from each other by a vascular intervening membrane. The consistence of the masses varied according to the quantity of pus-formation which had taken place.

Digitized by Google

A section of another of these masses (constituting one of the elevations first mentioned), presented, when the cells which were turgid with pus had emptied themselves, a distinct cancellated appearance.

4. Distinct large abscesses, of which there were several, but confined almost exclusively to the right lobe of the liver (its posterior part). They varied in size from a kidney-bean to a large orange, and generally communicated with each other. They all contained a thick yellow or greyish yellow pus. The larger abscesses were lined by a distinct pyogenic membrane, which in some places towards the free surface was smooth, but in other parts traversed by bands, giving it the appearance of a fasciculated bladder. These bands contained the vessels usually found in the portal canals, and also some lobules of the liver diminished in size. Several of the larger abscesses communicated directly with polyhedral recesses in the substance of the liver, evidently resulting from suppuration of separate lobules, and their subsequent reunion with the general cavity of the abscess.

The microscopic appearances, for which, and for the drawings, I am indebted to Mr. John Marshall, in whose hands the specimen was placed for examination, are thus given.

"On examining with the microscope one of the single buff-coloured granules, it was found to consist of the nucleated cells of the hepatic substance, more or less altered in their character. They had become paler and brighter than natural, their central nucleus was indistinct, and in all cases the oil had disappeared from the cells as distinct globules. In the progress of the disease the central portion of the lobule had become softened, the vessels and hepatic substance being broken down, leaving a semifluid mass, consisting of pus and exudation-corpuscules, large and small globules of oil, and broken-down nucleated hepatic cells, with a small quantity of fluid. See Plate V, figs. C. D. These lobules or granules were invariably surrounded by a layer of organised lymph, easily recognised by the microscope.

The individual granules forming the larger masses, presented precisely the same characters; their parietes were how-

Digitized by Google

Digitized by Google

DESCRIPTION OF PLATE V.

The figures illustrate Dr. Quain's case of lobular hepatitis, terminating in extensive suppuration. See page 171.

Fig. 1. Section of a portion of the liver, showing congestion of the lobules, passing at some points into suppurative inflammation, in an isolated, and also in an aggregated, form. Natural size.

Fig. 2. Section of the liver, showing small cysts of abscesses, from which the pus has been removed by washing. Magnified 4 diameters.

Figs. 3, 4, 5, show the disintegration of the liver-cells: they become more transparent; lose their nuclei; break up; and the débris is found mixed with oil-globules, pus, and exudation-cells.

Digitized by Google

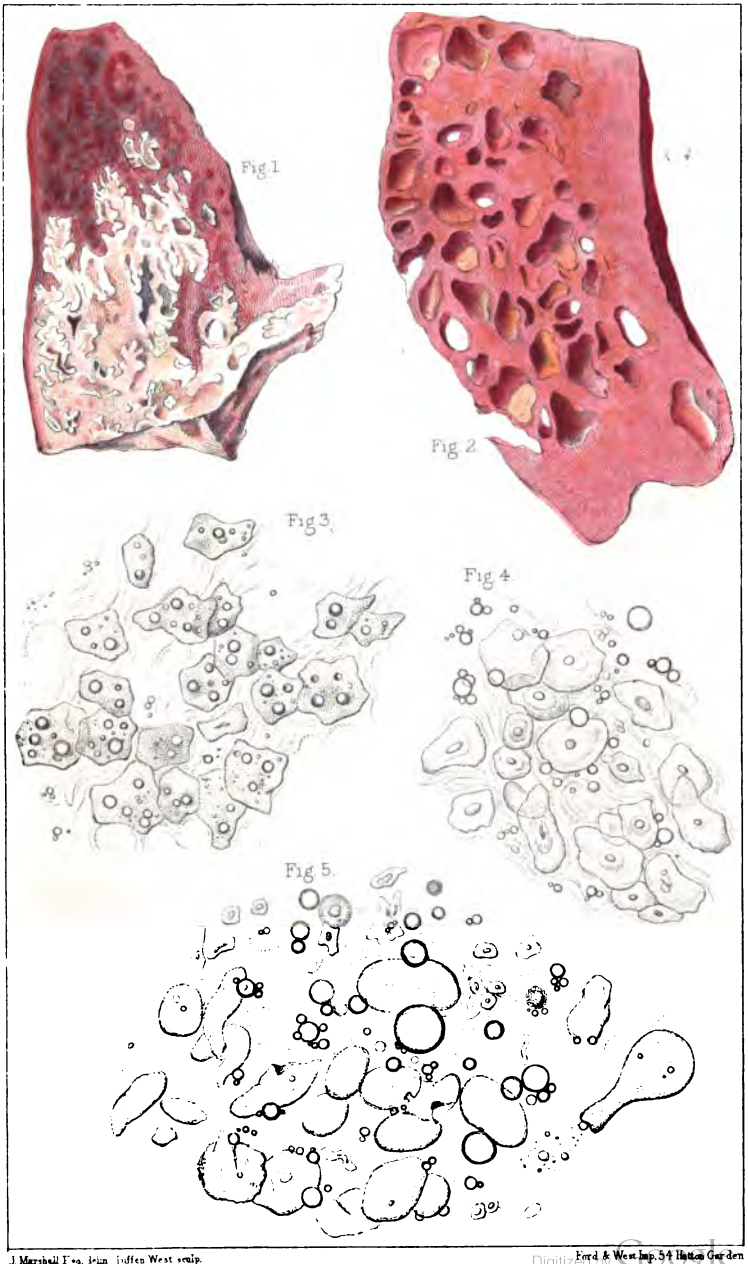

J. Marshall Esq. delin. Duffen West sculp.

Ford & West Imp. 54 Hatton Garden

Digitized by Google

Digitized by Google

ever, thicker and more dense. The cancellated appearance mentioned as the third morbid appearance, presented some peculiarities, which may be referred to a more acute form of inflammation. The walls of these small cavities were very thin and highly vascular. The cavities contained chiefly pus, with some globules of oil, and very few traces of the broken-down cells." This cancellated portion was placed over one of the larger abscesses, from which it was separated by a thin layer of hepatic tissue, which, with its vessels, seemed to have been much compressed, as if by the distension of the subjacent abscess.

Lastly, when a thin slice of the liver was cut off and washed so as to remove the pus from the cysts, the honeycomb appearance shown in Plate V, fig. B, was presented. This appearance is of interest in connexion with a case described by Mr. Annesley, ("On the Diseases of India,") in which, the thinner elements of the contained fluid having been absorbed, some of the abscess-cysts were left incompletely filled.

A like case is also figured (in one of the Fasciculi of Plates) from the museum at Chatham, in which, absorption having proceeded still further, the liver appears completely riddled with small cavities.

Remarks.—Dr. Quain observed that the first impression created by an examination of the morbid appearances just described was, that they were the result of purulent deposition, associated with ulceration in some other organ or tissue. Nothing, however, of this kind could be discovered on examination, nor was there any fact in the history of the case, which could support such an idea. The interpretation then given to these morbid appearances was that of which they seemed most capable, viz., that idiopathic inflammation, commencing in isolated points, had caused the formation of pus at these points; and that by the aggregation of these small isolated suppurating spots the larger abscesses were formed. Taking for granted the presence of this inflammation, an interesting question arises as to its seat. So far as it was possible to ascertain the fact, the intensity of the morbid action seemed to be greatest at the centre of those bodies which, to the naked eye, appear to con-

Digitized by Google

stitute the liver tissue—the lobules; and to a certain extent, the subsequent changes in the morbid appearance bore a relation to the size and shape of these little bodies. This fact is particularly well seen in some of the small points of suppuration shown in fig. A., Plate V. Thus, in fact, we have a form of lobular inflammation of the liver, analogous to a like well-known form of disease in the lung, concisely described by Dr. Williams, as follows:—"Inflammation not unfrequently attacks single or a few isolated lobules, being abruptly limited by the interlobular cellular tissue; so that lozenge-shaped or polygonal patches of red, engorged, or hepatized tissue, are found in the midst of healthy structure. The same distinction is sometimes exhibited in the degree to which the inflammation has advanced; some lobules of light purulent infiltration appearing in a livid engorgement."*

An apparent objection to the possibility of an inflammatory process going on in the individual lobules of the liver, may be found in the fact that these lobules, at least in the human liver, have no separate existence. The capillaries throughout the organ freely communicate. The like objection, however, applies in the case of the lungs. Moreover, there can be no question that, whilst in some animals, as the pig for example, each lobule has its delicate cellular investment from the capsule of Glisson, each lobule of the human liver has a definite distribution of its own blood-vessels, quite sufficient to account for a certain limitation to any inflammatory process which may have affected them.

Dr. Quain observed that he was not aware that this particular form of disease had been previously described. Morbid appearances very similar had been noticed by Annesley, Andral, Louis, Twining, Stokes, and others, but it is difficult to distinguish how far some of these appearances may have been the result of secondary purulent formations. The comparative rarity of hepatic suppuration in this country, was an obstacle to our obtaining that amount of information on these points, which our knowledge of the structure of the organ, and the care with which pathology was now cultivated,

* Article PNEUMONIA, in the "Cyclopædia of Practical Medicine."

Digitized by Google

justified us in expecting. Dr. Quain mentioned some further facts of interest in connection with suppuration in other parts of the liver, and the forms which abscesses of the organ assumed; referring to a case of abscess described by Cruveilhier, under the name of "External Phlebitis," in which, from a collection of pus in the transverse fissure of the organ, numerous canals (corresponding to the portal canals) containing pus *extended throughout the substance* of the liver. Dr. Quain referred also to a case described by Andral, in which an extensive formation of pus was *confined to the surface* of the liver beneath the investing capsule, and to a similar case, still more marked, described in the "Transactions of the Medical and Physical Society of Bombay" for 1844, page 54. He also referred briefly to the circumscribed and diffused forms of abscess in the substance of the organ, and to that connected with hydatids. Dr. R. QUAIN, 19*th of May*, 1853.

27.—*Fibrinous Deposits in the Spleen, Thoracic Glands, &c.*

These specimens were removed from the body of a man, aged thirty, who had been under Dr. Sibson, in St. Mary's Hospital.

He had enjoyed good health up to a period of about a month before his admission into the hospital; he then experienced pains in the head, sickness, and loss of appetite; he entered the hospital about the middle of December, and died about six weeks afterwards. When first observed, he presented a remarkably pale, anæmic aspect; his ankles were slightly œdematous, his abdomen somewhat swollen, and his strength failing; his urine low in density and albuminous: it soon became manifest that some other cause besides the renal disease was destroying his life; and from the circumstance of an enlarged and hardened gland existing in the lower triangular space on the right side of the neck, and of the external jugular vein being swollen on that side, Dr. Sibson conjectured that some tumor, probably of a malignant nature, was present in the thorax. Besides these general symptoms, and

Digitized by Google

some abnormally dull percussion-sounds at certain parts of the thorax and over the spleen, there were no local signs to indicate the nature or position of the disease. The man gradually became more anæmic and wasted, and sunk at last, comatose; a week before his death, the external surface of his body became completely jaundiced.

The *autopsy* showed the presence of a cluster of enlarged glands in the anterior mediastinum, encircling the aortic arch, and extending downwards along the posterior mediastinum; a hardened mass of these were also firmly attached to the posterior part of the upper bone of the sternum; they all presented the same characters, were whitish-yellow, hard, and unyielding, resembling medullary carcinoma.

The *spleen* contained masses of straw-coloured deposit, some as large as a filbert, others as mere specks, distributed through every part of it: the structure around them appeared healthy: the organ weighed 1 lb. 10½ ounces.

Similar deposits were found in some of the mesenteric glands.

The appearance of the tumors, and the history of the man's disease, left no doubt as to their malignant character; but when portions of them were tested by the microscope, they were found to contain none of the elements usually given as characteristic of cancerous disease; they seemed to be simply fibrinous effusions, containing granular matter with granular nuclei, but no trace of a composite cell, or of fibroid deposit: the specimen was carefully examined by Dr. Handfield Jones, and Dr. Sieveking, as well as by myself. Some of the proper elements of the spleen were found mingled with the deposits in that organ.

The kidneys were enlarged, and presented the appearances of Bright's disease.

All the internal organs were jaundiced: no bile was present in the gall-bladder. Dr. MARKHAM, *1st of February*, 1853.

Report on the preceding case.—The character assigned by Dr. Markham to the diseased condition of the spleen and lym-

Digitized by Google

phatic glands, is apparently correct. It seems to be the result of a fibrinous deposit, probably caused by slow inflammatory changes. Certainly there is little evidence, microscopic or otherwise, to induce a belief in its malignant character, and the evidence in favour of its scrofulous nature is scarcely stronger.

The lymphatic glands were increased in size and indurated; on section they appeared to consist of a greyish fibrous material, with opaque-yellow circumscribed deposits, from the size of a pea downwards, occasionally imbedded in it. The fibrous substance had something of the appearance of scirrhus, but was scarcely so firm, nor did it yield a creamy juice. The yellow deposit was not very unlike tubercle, but was tougher, less cheese-like, and had more resemblance to the fibrinous deposits often found in the spleen, liver, &c. Under the microscope it appeared to consist almost entirely of closely aggregated cells and granular matter disseminated through a delicate, filmy, fibrous reticulum, scarcely visible, except occasionally along the edges of a section. The cells, which might rather be called irregular polyhedral bodies, varied from about the $\frac{1}{4000}$th to the $\frac{1}{1000}$th of an inch in diameter, had a peculiarly glossy appearance, were homogeneous or studded with minute oil-globules, or an oily-looking material deposited in a less definite form, and sometimes imperfectly assuming the appearance of nuclei. In some parts the deposit of oil was in great excess, the individual globules being large, numerous, and apparently originating in the cells. Plates of cholesterine were tolerably numerous, and the whole tissue was thickly studded with delicate acicular crystals, possibly the result of decomposition.

Acetic acid exerted little influence, merely dissolving the delicate fibrous matrix.

The fibrous portion of the diseased glands consisted almost entirely of densely arranged fibrous tissue, in some parts disposed in thick parallel bundles, in other assuming a flexiform arrangement. The individual fibres were broad and pellucid, and were not unlike small bundles of white fibrous tissue slightly acted on by acetic acid; in some parts cells like those in the yellow deposit (but less abundant) were observed; in

Digitized by Google

the greater part of the tissue, however, there was almost a total absence of them. Acetic acid rendered the whole of this tissue transparent, and displayed a considerable amount of molecular, oily matter. There were no crystals.

The character and arrangement of the different structures in the diseased glands, was sufficiently like that observed in a cirrhoid liver, to suggest an analogy between them. It seems not improbable that the fibrous portion was chiefly the result of fibrinous exudation; the yellow substance, the remains of gland-structure in a more or less unhealthy condition.

The only difference I observed between the healthy structure of the spleen and the fibrinous deposit within it, was the existence in the latter of a considerable quantity of a delicate fibrous network, much resembling that of coagulated fibrin, studded with an abundance of molecular matter, distinct oil-globules, and oily-looking cells. All the natural constituents of the surrounding healthy gland-structures were present, but in diminished quantity.

Dr. Bristowe, *15th of February*, 1853.

V.—DISEASES, &c., OF THE URINARY AND GENERATIVE ORGANS.

1.—*Enchondroma of the Left Testicle.*

W. W., a gentleman-farmer, aged thirty, unmarried, in February, 1851, in leaping a fence, whilst out riding, was thrown forwards on to the pommel of the saddle, and received a smart blow upon the left testicle, causing much pain, and subsequently slight swelling. The pain lasted for a week or more, but was not sufficiently severe to induce him to call in his medical attendant: although it prevented him from again attempting to ride until the May following. At this time, when the testicle was struck or touched incautiously he experienced piercing lancinating pain; and upon careful examination found that it had become hard at its inferior portion, and was also slightly enlarged.

This continued until the 10th of October, when without appa-

Digitized by Google

rent cause, the pain increased, and extended to the bottom of the spine; this went on for a few days, then gradually subsided up to the 28th, when he had again considerable accession of pain whilst in bed; this lasted for upwards of two hours. On the 29th he was compelled to go a few miles from his own residence; he set off early, comparatively comfortable, but at noon was seized with severe pain in the lumbar region, which extended to the abdomen; the testicles became a little swollen, red, and painful, and the urine could not be voided; he applied to a druggist in the town, who considered it to be merely an attack of colic, and prescribed accordingly. The remedy gave sufficient relief to enable him to reach home; and during the night he voided a large quantity of urine.

The next day (30th of October) he was too unwell to leave his bed, the testicle continuing very painful, and swelled to twice its natural size; the pain extending up the spine. He then thought it necessary to consult his surgeon, Mr. Belcher of Burton, who prescribed leeches and lotions to the testicles, with internal medicines: at the end of a week the size of the testicle remained the same, although the pain and inflammatory action had considerably abated; the lotion with iodine ointment was continued; and at the end of another week he was able to leave his bed, the swelling of the testicle having considerably diminished. The ointment alone was continued, and the testicle remained in the same condition at the end of a month; from this time it very gradually increased in size up to July, 1852.

The great inconvenience he now experienced, with symptoms of declining health, induced him to come to London, and place himself under the care of Mr. Hancock. At this time the testicle was exceedingly large; its surface smooth, and the vessels of the scrotum enlarged and tortuous: when squeezed it did not give much pain, but presented an elastic sensation to the touch, with considerable weight. Mr. Hancock introduced an exploring trochar, and a few drops of blood only followed the withdrawal of the instrument. The cord appeared healthy; no enlargement of the pelvic glands could be detected; and when the testicle was well supported, the dragging pain in

Digitized by Google

the loins was relieved. He advised its early removal, to which the patient immediately assented, and the usual operation was performed, under the influence of chloroform, on the 11th of July: he recovered without a bad symptom, and was able to leave London at the end of the same month. Up to the present time (February, 1853) he has remained in perfect health; and in answer to my inquiry, he says: "I am as good a man as ever I was."

Upon examination after removal, the mass weighed four pounds six ounces, and on section, the disease affecting it was found to be of the enchondromatous and cystic kind, the former being made up of nodules of fibro-cartilage: whilst some of the cysts were filled with coagulated blood, in others flocculi, apparently fibrinous in character, were seen; whilst of the remaining ones the contents were, for the most part, of a light straw-coloured viscid fluid.

Sections taken from various parts of the cartilaginous mass, and examined under a power of 250 diameters, present a series of circular, ovoid, and elongated cells, varying in size from the $\frac{1}{400}$th to the $\frac{1}{1200}$th of an inch, enclosing within a delicate membranous cell-wall from two to eight or ten nuclei, with a few fat-globules: these nuclei vary in size from $\frac{1}{3500}$th to $\frac{1}{4500}$th of an inch, the cells being more closely aggregated and irregular than in healthy cartilage. (See plate VI. fig. 1). Ether rapidly removes the fat-globules, causing the nuclei to run closer together, and the hyaline structure of the cell-wall becomes more apparent, as in fig 2, gradually losing its spheroidal character as it elongated, in its transition, from the nucleus of a cartilage-cell to the lacunæ of bone, (figs. 3 and 4). Towards the outer portions of the tumor the cells and nodules were smaller, and arranged closer together, with interlacements of fibrous tissue; as from its position, this part would probably be the last attacked by the disease: this is shown in fig. 2. The edges of some of the cells being broken up, the contents escaped, and became distributed around, proving the existence of walls independent of the matrix-cell. A few crystals of the oxalate and phosphate of lime were also distributed about with the cell contents.

Digitized by Google

Digitized by Google

DESCRIPTION OF PLATE VI.

The figures illustrate Mr. Jabez Hogg's case of enchondroma of the testicle. They are fully described in the text. Page 181.

Digitized by Google

Casts of the tubuli.
15 diaf

Fig 8.

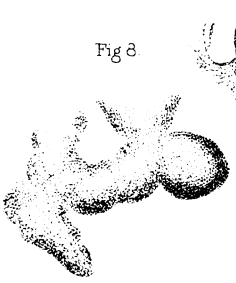

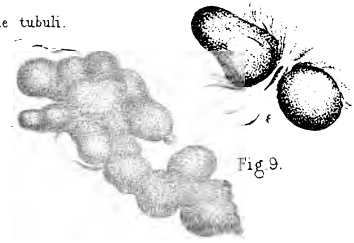

Fig 9.

Fig 1.

Fig 2.

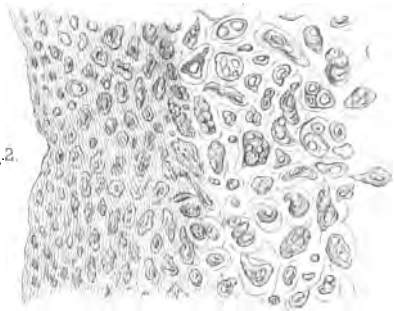

Fig 3.

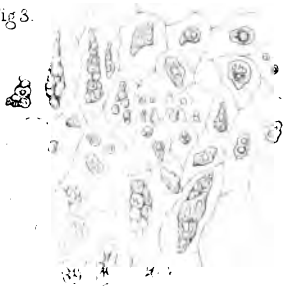

Fig. 5.

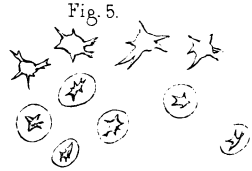

Fig. 7.

Fig 4

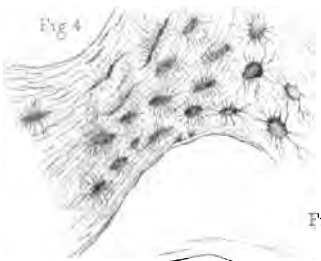

Fig 6

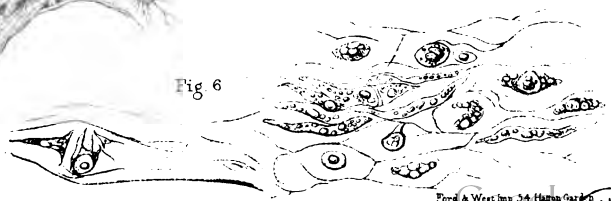

Tuffen West sculp

Ford & West imp 54 Hatton Garden

Digitized by Google

Digitized by Google

In the central portions of some of the enchondromatous masses, were to be seen irregular groups of shrivelled nuclei, with only slight traces of cell walls, undergoing a process of gradual separation from each other, as in fig. 5, with here and there a patch approaching to a crystallizable form, somewhat allied to normal ossification, represented by fig. 6, passing on in some places to a more radiated form, as at fig. 7. The tubuli seminiferi were almost wholly obliterated, and much of the tissue pushed to the upper and outer margin of the tumor: on making a careful examination of what remained, tubuli were seen in all stages of alteration, some being slightly, others greatly dilated, as seen at fig. 8. Masses of cartilage partaking of the shape of the dilated tubes, as at fig. 9, could be readily discovered and separated from other masses of tubuli; so that it would appear that all the nodules of cartilage found in the tumour were originally developed in the tubuli seminiferi; and that with the usual rapidity of cell-growth, we have cells dividing and multiplying, and converting the whole of the substance of the testis into an abnormal fibro-cartilaginous mass.

Fig. 4 is more especially intended to show little bony spiculæ, taken from a finger affected with enchondroma. Here we have the gradual and true transition from the cartilage cell to the bone lacuna, with its characteristic canaliculi, proving what has been pointed out by Professor Quekett, "that where we have had these tumors developed near a bony structure, the mass may become turned into bone; but that he has never observed this change take place in any other situation." Mr. Canton removed an enchondromatous mass from the mamma of a bitch, which showed this transition to the true bone, precisely as represented in this figure; the position of the growth is most remarkable, and the character of it proves that this change does truly take place in the lower animals, which the higher, or more refined organism of man is capable of resisting, or arresting at a certain stage of growth. This would likewise favour the view entertained by Professors Todd and Bowman, with regard to the formation of the lacunæ of bone: "*that the lacunæ are developed from the nuclei of the cartilage cell.*"

Digitized by Google

Many errors have crept into their descriptions of morbid and healthy structures by the older anatomists, indeed even to a recent date, simply because it was much the fashion at one time to throw doubt upon the valuable aid which the microscope could have afforded them in their examinations. Consequently most of the specimens in the College, and other museums, of this peculiar form of disease, have been imperfectly classed, and wrongly described. Take No. 2386 (The College Museum) said to be "*a scirrhous tumor:*" it is not so, but one of fibro-cartilage or enchondroma. No. 2429 A, said to be "*two large portions of bone-like substance*, imbedded in a tumor exactly like that of scirrhus of the breast:" this has been found not be be true bone, but ossific deposit taking place in the central part of enchondromatous masses. Many others might be instanced in like manner.

Sir Astley Cooper, in his book on "Diseases of the Testis," gives the drawing of a tumor described by him as "very hard; in some parts cartilaginous, in others ossific;" 100 parts of this, carefully divested of membrane and dried, were given to Mr. Barry for chemical analysis, and he stated them to be made up of—

Phosphate of Lime	45 parts.
Carbonate of Lime, with a trace of Magnesia .	17 „
Animal Matter	38 „
	100

This is, indeed a close approximation to the chemical composition of true bone, but that it is not bone, the microscope has subsequently shown. Again, Plate 10, fig. 2, is said to be a drawing from a "Scirrhous Tumour of the Testis," in the Museum of St. Thomas's Hospital: it is *not scirrhus*, but a well-marked and beautiful specimen of enchondroma, as recently shown by Mr. Wm. Adams.

In Guy's Museum a preparation, it is stated, "shows numerous cysts, studded with spiculæ and earthy matter, thrown out in patches of different sizes." This should be *cysts with patches of enchondroma.*

No. 2387, (The College Museum) is described by Hunter as

Digitized by Google

"*fibrous*," containing numerous masses of *fibro-cartilage*. "In this," he says, "may be seen the *tubular substance of the testicle, apparently healthy, spread out in a layer from one to two lines in thickness, over the upper part of the tumor.*"

This has been stated to be the case in other tumors of this class examined by Mr. Curling. He observes, in the article TESTIS, "Cyclopædia of Anatomy,"—that "the origin of these cysts cannot be satisfactorily made out. It has been supposed that they are formed of dilated and obstructed seminiferous tubes; but as in certain cases the tubular structure exists in the form of a *layer spread out over the morbid mass*, it is clear that the disease could not have originated in this way; and this morbid change is evidently quite distinct from the little cysts so commonly developed in the head of the epididymis."

Mr. Wm. Adams also maintains that all the specimens in the Museum of St. Thomas's "show this; as well as that cystic and enchondromatous disease nearly always exist together; and in some the tubular structure appears to coexist in a healthy condition." On the other hand, Professor Quekett proved and demonstrated in his lectures at the College, Session 1853, from a specimen removed and brought to him by Mr. Curling, that these cysts and masses were developed *in the tubuli*, as figured by me in the drawing, Plate VI.

Mr. Quekett shows another specimen of enchondroma removed by Mr. Fergusson, exhibiting a large amount of ossific deposit in the centre of the cells, although no trace of *bone-cells* could be discovered: a section of this specimen is figured in Plate VII of the "Histological Catalogue," fig. 12; with others of much interest, at p. 164 of his "Lectures on Histology."

Rokitansky, in his "Pathological Anatomy," p. 253, says: "the formation of cysts in the testicle is very unusual, a fact of special interest from the frequency of their occurrence in the ovaries. Enchondroma is equally rare; with an anomalous osseous substance sometimes developed in the indurated testicle, assuming the shape of round, tuberculated, or tendiniform concretions." In this country, tumors of this character have been removed from various situations, and of considerable size:

Digitized by Google

those already mentioned, as well as many others, by John Hunter, in the College Museum. Sir Astley Cooper removed several,—one preserved in St. Thomas's Museum: the testicle weighs now nearly five pounds: there are others in the College; No. 2384 measures five inches in length and three inches in breadth.

Mr. Warner, of Guy's, "found his knife resisted by a tumor of this kind." The patient recovered.

Mr. Tyrrell removed a testicle: the enchondromatous mass was of the size of a large orange: the patient recovered.

Mr. Curling, at p. 539 of his book "On Diseases of the Testicle," describes a large "fibrous tumor removed from a patient aged seventy-three; it was of twenty years' duration, and from twelve to fifteen times the ordinary size: it was filled with small tumors, of stony hardness, with fibrous tissue, the *secreting structure having wholly disappeared; causing a total obliteration of the seminiferous ducts.*" The man recovered, and lived several years afterwards.

Sir Benjamin Brodie removed a testicle "that had undergone this conversion." The patient recovered.

M. Marjolin excised a testicle that was more than twice the natural size and very heavy, it was found to be of a fibro-cartilaginous nature.

Mr. Fergusson's case, perviously mentioned: the patient did well.

Mr. John Adams, of the London Hospital, removed an enchondromatous testicle from a patient of his, who recovered.

Sir Astley Cooper remarks that "these deposits show the great propensity there is in serous and fibro-serous membranes to form cartilage and earthy matter; and how much the results of chronic inflammation may vary; under one action, a serous effusion; under a second, great thickening; under a third, cartilaginous substance; and under a fourth, earthy matter is the result."

Mr. Jabez Hogg, 1*st of March*, 1853.

Digitized by Google

2.—*Hernia of the Bladder into the Scrotum.*

N. M., aged eighty, a footman. At the age of sixteen suffered from a hernial protrusion in the left groin. Not finding himself inconvenienced, he neglected it, and never had a truss applied. He enjoyed excellent health up to ten years since, when the hernia suddenly increased, extending into the scrotum. At this time a swelling appeared in the right groin also; he then applied to a medical man, who told him that his bladder had come down in the rupture on the right side. Eight years ago the tumors having both increased to a great extent, causing him much inconvenience from their size, he applied at the Middlesex Hospital, but was told that he could not be benefited by treatment. His general health was not affected; the bowels acted freely, and he soon learned, by leaning with his head against a wall, straining and pressing the right scrotum with his hands, to evacuate his urine. Had no stricture, and never suffered from retention. The symptoms remained the same up to the present time, excepting that the swellings continued to increase; that on the right diminishing somewhat after passing water, which flowed from him in a thin stream, in small quantities, and frequently. He always had to rise early in the morning to void his urine. On the 4th of this month, (October, 1852,) on getting out of bed as usual, he found himself unable to evacuate the contents of the bladder; he took some gin-and-water, but still continued unable to pass his urine. Fearing the expense, he did not apply for medical assistance until the 7th instant: on the 8th, the usual medicines having failed to relieve the retention, a gum-elastic catheter was passed by Mr. Gange, and a small quantity of water removed, after which he expressed himself relieved.

On the following day (the 9th) he was seen by Mr. W. Bryant; the catheter was again introduced, and more than two quarts of urine were drawn off. There was considerable difficulty in introducing the instrument, especially from the fact that all the ordinary gum catheters were about four inches too short. He suffered no more inconvenience from the dis-

Digitized by Google

tension till the 11th, when the bladder again became much enlarged. Mr. Lane was now called in consultation. He with difficulty succeeded in drawing off, with a gum catheter, a considerable quantity of urine. The patient's health now appeared to be suffering from the shock on the system of one so advanced in years; his appetite failed and his spirits sank.

On the 14th, Mr. Pilcher accompanied Mr. Lane, who was again requested to see him. The scrotum presented a swelling of unusual magnitude (measuring nearly 12 inches from side to side), the skin being tense, and the penis completely retracted, the only indication of its existence being a depression like that of the umbilicus (fig. 3). The swelling on the left side

Fig. 3.

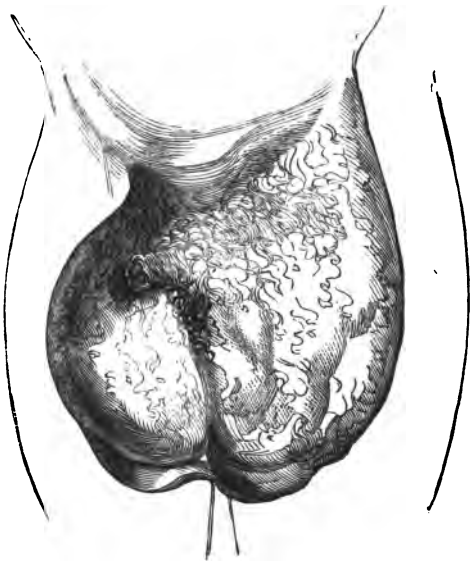

presented an irregular appearance, and measured 14 inches in circumference; the various convolutions of the contained intestines, as well as their peristaltic movements, were distinctly visible through the attenuated coverings of the hernia. On

Digitized by Google

the right side was seen also a considerable swelling, somewhat less than the left, of a more regular pyriform shape, looking very tense, feeling smooth on its surface, distinctly fluctuating. On application of the taxis, a considerable portion of the contents of the left scrotum could be returned into the abdominal cavity; not so the right, for on the least pressure the patient complained of pain, and desire to pass his water. The testicle could be distinctly seen, and felt as a rounded and moveable projection on the lower and fore part of tumor. Mr. Lane this time attempted to introduce a longer and somewhat larger gum catheter; but from its want of pliability, the introduction could not be accomplished. The shorter and more pliable instrument before in use was then tried, and a large quantity of dark, extremely offensive urine, with some admixture of blood, was drawn off. A plug was put in the catheter, which was left in the bladder. During the afternoon the patient became worse; by the evening he had become delirious. He had pulled the catheter out of the bladder. Coma soon set in, and he sank on Saturday the 16th.

The post-mortem examination was performed by Mr. Gange and Mr. Pilcher on Monday. Decomposition had somewhat advanced. The swelling of the scrotum was more flaccid than during life. Time and other circumstances prevented a careful or minute dissection, the examination being conducted by candle-light in a small room. The prostate was much enlarged, and firmly held down by its ligaments in its proper position in the pelvic cavity. The structure of the bladder appeared much altered. The protruded portion consisted of about two-thirds of the viscus, capable of containing about 50 ounces of water. At the situation of the inguinal canal, there was found an hour-glass contraction of the organ, the communication between the two portions being about one inch in diameter (fig. 4). The pelvic portion was capable of containing about 20 ounces of fluid, and was displaced forwards and to the right side. Both the ureters opened into this part. The urethral opening at the neck of the bladder was much dilated, being large enough easily to admit the finger. The epigastric artery was situated at the inner side of the neck of the hernia. Mr. Pilcher concluded

Digitized by Google

FIG. 4.

The pelvic portion of the bladder laid open; showing,

1. The Ureters.
2. The Orifice of the Urethra.
3. The Epigastric Artery.
4. The portion of the Bladder that lay in the Scrotum.
5. The Testicle.
6. The enlarged Prostate.

from this, that it must have been an old oblique inguinal hernia, in which the internal ring had been dragged down to the external by the constant weight. The protruded portion of the viscus was firmly adherent to its sac.

Mr. Pilcher remarked that he could not help indicating the great similarity between this case and one which fell under the notice of Mr. Keate, as quoted in Mr. Coulson's work "On Diseases of the Urinary Organs."

Digitized by Google

He had been unable to collect any statistical account of the frequency of these herniæ, most authors only mentioning them as of very rare occurrence.

The names of Pot, Petit, Sir A. Cooper, Clement and Lawrence, may be mentioned with some others as having devoted a few pages to this variety of rupture. The accompanying sketches, which exhibit accurately the parts as seen after removal from the body and dissection, were made by Mr. Chapman.

Mr. PILCHER, 19*th of October*, 1852.

3.—*Specimen of Encephaloid Cancer of the Kidneys.*

The specimen was removed from a male, aged sixty-four years, who had suffered during two years from occasional attacks of hæmaturia, the blood at times being in a fluid state, at others in clots, moulded to the calibre of the urethra. Pain was constant in the lumbar region and over the bladder. The urine, for many months before death, was passed involuntarily; the hand, when pressed on the abdominal parietes, could detect a tumor in the left renal region.

The left kidney, globular in form, weighed a pound and a half; the normal structures were quite destroyed, and replaced by a mass of encephaloid cancer; when cut, the numerous bleeding points gave it a general vermilion hue; the destroyed cortical and tubular structure had given place to cancerous matter in various states of consistence, from brain-like firmness to that of semi-fluidity. A clot occupied its centre; under the microscope it showed abundance of fatty matter, interspersed with cancer cells. The right kidney was but little above its natural size; its cortical structure was studded with spherical white deposits, firm to the touch, varying from a nut to a pea in size: when viewed under the microscope it showed a larger amount of cancer-deposit than the left kidney. No other organ was diseased. The bladder was contracted, so as only to hold a couple of ounces of urine. Numerous lumbar glands were enlarged by cancerous deposit.

Mr. OBRE, 18*th of January*, 1853.

Digitized by Google

4.—*Renal Calculi, the one at the Beginning and the other at the Ending of the Ureters.*

E. R., aged twenty, was admitted on the 5th of October, 1852, into St. George's Hospital, under my care. She had been ill for a week with continued fever and diarrhœa, without spots, one or two only excepted, which were on the surface of the abdomen. There was no tenderness in the region of the cœcum. The urine was generally passed with the motions, so that it could not be examined. At first the symptoms improved, but after a fortnight she was attacked with bronchitis, and the back became sore. By means of the water-bed and appropriate treatment she again improved. On the 6th of November some urine was procured; it was loaded with pus, and contained some albumen; no crystalline deposit or blood-globules were observed. She gradually sank and died on the 20th of November. On inquiry after death, her mother said, that when ten years old she had suffered from pain in the loins, had passed bloody urine, and had never been well since.

The intestines were congested externally, and internally the lower part of the mucous membrane of the ileum and rectum was thickened and vascular, with one or two ulcerations. The mesenteric glands were enlarged and congested. The liver was healthy.

The kidneys were much elongated; they were very vascular, and in both, on the surface, there were some raised spots of yellowish, soft deposit. The cortical structure was enlarged; the pelvis of each kidney was immensely dilated, and contained purulent urine. The right pelvis contained one or two loose portions of calculus, and the commencement of the ureter a largish calculus, about the size of the last phalanx of the little finger; it had grown down the ureter, so that it was turned out with difficulty. Below this the ureter was not dilated. On the left side the ureter was dilated: the lower extremity was occupied by two largish calculi, of the size of hazel-nuts, consisting of a thick deposit of oxalate of lime externally, with a uric acid nucleus. The bladder was healthy.

Dr. Bence Jones, *7th of December*, 1852.

Digitized by Google

5.—*Cyst in the Kidney, containing Cholesterine Crystals.*

J. B., aged forty, admitted into St. George's Hospital on the 27th of October, 1852, with anasarca, jaundice, and highly albuminous urine. The left cavity of the chest full of fluid, and the heart much enlarged. He died on the 19th of November, 1852.

On examination there was much yellow fluid in the cavity of the abdomen. Both kidneys were small, firm, and very granular on the surface. The cortical structure was much diminished. On the surface of both kidneys there were cysts, varying in size; some would contain scarcely a drop of fluid; two or three contained at least a drachm of dark brown, thick fluid, which was slightly acid to test-paper, and contained much albumen in solution. On examination of the contents of one cyst, by the microscope, the thickness was seen to depend on blood-globules, dark masses of granular matter, three or four times the size of the blood globules; some fatty matter; many very distinct plates of cholesterine, and a very few octohedral crystals. Another cyst contained the same granular matter; more blood-globules, but scarcely a crystal of cholesterine could be found. The pelves of the kidneys were very vascular; the renal arteries were but little thickened.

The left pleura was full of fluid; the heart weighed 18 ounces.

Dr. Bence Jones, *7th of December*, 1852.

6.—*The Contents of a Cyst in the Kidney.*

From the lining membrane of a cyst, the size of a small walnut, from the kidney of an intemperate man, aged thirty-seven, who died in King's College Hospital, on the 15th of February, 1849, of pneumonia.

The kidneys were both much smaller than natural, and were much congested; surface smooth; capsule adherent. Each contained one cyst, in corresponding situations. The tubes formed dilatations in the meshes of the matrix. A section of the kidney appeared mottled with small, whitish masses, which

Digitized by Google

upon microscopical examination, were found to consist of dilated tubes (or cysts?) (Plate VIII.)

Fig. 1 shows a portion of the lining membrane of the cyst.

Fig. 2 shows what is probably a portion of a uriniferous tube.

Fig. 3 indicates numerous free oil-globules and plates of cholesterine, which were also present in the fluid contents of the cyst.

Dr. Lionel G. Beale, 21*st of December*, 1852.

7.—*Calculus and Cyst in the Kidney.*

L. P., aged thirty-two, admitted into the Royal Free Hospital, under Mr. Gay, 2nd of November, 1852. Her face was pale, and had a decidedly "renal" aspect; she passed her urine frequently, and with intense pain; had considerable tenderness on pressure over the region of the bladder, and a constant aching pain along the inner side of the right thigh. Her urine contained much ropy pus, and some blood; had an alkaline reaction, but was in normal quantity. Her pulse was feeble, and general powers low.

She had been under the care of Dr. Todd, in King's College Hospital, for a similar complaint, about twelve months previously; and was so much benefited by the treatment that she thought herself for a time comparatively well. Her symptoms, however, gradually returned.

The bladder was sounded in expectation of finding a calculus, but in vain. Copaiba, with henbane and nitric acid, was given with good effect, so that, at the expiration of a month, her pain had ceased, and her urine had regained almost its healthy character; it was free from pus and blood, rather pale, and but slightly acid.

Sickness now supervened, but was relieved by hydrocyanic acid; after that, diarrhœa came on, and yielded to lead and opium. About the middle of December her legs began to swell, her mouth became apthous, her intellect began to fail; she complained of slight stiffness in the legs; her urine became

Digitized by Google

slightly albuminous; and thus she went on until the 12th of December, when she died.

She had not, from her own account, ever suffered from lumbar pains; and for the last month of her life she was entirely free from her urinary affection.

Post-mortem examination, thirty-five hours after death. Rigor mortis slight; old pleuritic adhesions; one ounce of fluid in the pericardium; some fat about the heart, and its substance pale; lungs slightly emphysematous; a cretaceous tubercle in the apex of the left one; liver large, fatty, and firmly adherent to the right kidney; spleen flabby.

The left kidney was large, and contained in its cortical substance a moderately-sized hydatid cyst, closely in contact with the lining membrane of its pelvis. (Dr. Babington thought, from the appearance of the kidney, that it was in the first stage of Bright's disease).

The right kidney was converted into a multilocular abscess; several of the loculi containing large lithic-acid calculi. On cutting through its tissue in several places, considerable quantities of milky, purulent fluid escaped. The tissue was examined microscopically by Dr. Brinton and Mr. Gay, was found to have lost its natural structure, and to consist almost entirely of fibrous tissue with an abundance of fat.

The intestines, bladder, and uterus were healthy. Mr. Gay remarked, that in this case the symptoms belonging directly to the primary and more serious affection were so slight as to have been completely masked by those which appertained to the evacuation of unhealthy urine.

The hydatid cyst appeared to have caused no great inconvenience. Mr. Gay mentioned the cases of a man and his wife who were under his care a few years since for hydatids, evidently of the kidney. They both complained of uneasiness in the loins; and acute pain in the situation of the anterior superior spine of the ileum. The urine was at first turbid; then mixed with pus and blood-corpuscles; and finally with genuine echinococci, the hooklets of which were seen by Dr. Peacock as well as by himself. These persons were both treated with large doses of iron, and ultimately quite recovered;

Digitized by Google

they are now alive, and although not robust, are in the enjoyment of good health.

Mr. Gay, 18*th of January*, 1853.

8.—*Calculous Abscess in the Pelvis.*

J. W., aged thirty-six, a warehouseman at London-bridge Wharf, of fair complexion and phthisical family; of temperate habits till quite latterly, when the nature of his complaint had induced him to take large quantities of gin. When eight years of age he suffered very severely from symptoms of stone in the bladder, and subsequently passed a calculus as large as a hazel-nut by the urethra. He never became robust, but continued subject to attacks of lumbar pain. When twenty-eight years of age, the symptoms became aggravated, and from this time till within two months of his death, the urine almost constantly deposited more or less of a thick cream-like sediment, which, on shaking, was easily miscible with the fluid. It never contained any ropy matter or blood, nor did he suffer from symptoms of calculus in the bladder.

On account of the increasing emaciation and pain in the back and loins he was frequently under medical treatment, but continued at his work until August last, when he had a severe attack of diarrhœa, which continued for a fortnight, and had recurred at intervals ever since. From that time he had never left the house. He was seen by Dr. Peacock in conjunction with Mr. Orton, his private medical attendant, about the 30th of December; at that time he complained chiefly of pain in the left lower extremity: the limb was found extremely œdematous, and the skin tense and smooth. This condition was stated to have commenced with pain and tenderness in the course of the femoral and inguinal veins, about two weeks previously. The other extremity was free from œdema. A very careful examination of the abdomen failed to detect any tumefaction, but deep pressure in the hypogastric and iliac regions occasioned some pain. The urine was passed without difficulty either before or after the act of micturition. It was sufficient in quantity, clear, of a pale straw-colour, and

Digitized by Google

free from albumen. There was no pain or tenderness on pressure in the lumbar regions, nor any sickness or vomiting; indeed, the appetite and digestion were good, and the tongue clean. He was much emaciated, and had a rapid, feeble pulse. Examination of the chest did not elicit any evidences of disease in the lungs or heart; the only marked symptoms of which he complained being the pain in the leg, the frequent attacks of diarrhœa, and the increasing debility and emaciation. By means of acupuncture the œdema of the leg was almost entirely removed, an enormous quantity of serum being evacuated, and astringents and tonics were prescribed. His strength, however, continued to decline. On the 8th of January the other leg began to swell, and, on the following day, a sharp attack of diarrhœa supervened, under which he sank and died on the 11th. The above notes were furnished by Mr. Orton and Mr. Hutchinson.

The *post-mortem examination* was performed by Mr. Hutchinson, two days after death. On opening the abdomen, the lower border of the great omentum was found to be firmly adherent to the parts above the crest of the pubes; and, on attempting to tear it away, the cavity of a large abscess was opened, which contained, besides about half a pint of thick fetid pus, a large irregularly-shaped calculus. The abscess was situated behind the peritoneum, in the space between the bladder and rectum, which viscera, denuded of their serous covering, constituted its anterior and posterior boundaries. (Plate VII., fig. 1)

Around the left kidney and ureter, the tissues were greatly thickened and condensed; the pelvis and calyces of the kidney were much dilated, so as to form a cavity capable of containing a large egg, and were lined by a soft villous membrane of a dark colour. The renal structure was much atrophied and indurated, and the exterior of the organ was almost inseparably blended with the adjacent parts. The ureter was large enough to admit the finger; its interior was lined by a membrane similar to that lining the pelvis of the kidney, and its coats were much hypertrophied and involved in the adjacent thickened cellular tissue. Immediately before

Digitized by Google

it entered the bladder, it communicated by several large apertures with the abscess before described; and when passing through the coats of the bladder, its canal was obliterated. The calculus weighed, when dry, one ounce and a half, and was about two inches and a half long and an inch wide in the centre, from which point it tapered to each extremity in a somewhat twisted form. One of the extremities was thinner and longer than the other, and this had, apparently, been moulded by the upper part of the ureter, while the calculus lay in the pelvis of the kidney. The surface was smooth and polished at the lower end and centre, rough at the upper or thicker extremity (Plate VII., fig. 2). Where the ureters lay in apposition with the iliac vessels, they were found imbedded in the condensed cellular tissue, and the vein was flattened, its coats thickened and indurated, and the cavity from Poupart's ligament to the vena cava, obstructed by partially decolorized coagula, more or less laminated, and adherent to the internal coat. At the lower portion of the vessel, the coagulum formed a cylinder not adherent to the internal coat, and with a small cavity in the centre. There was some recent coagulum in the left iliac vein, and the hepatic vein on the left side could not be distinctly made out.

The right kidney was twice its natural size, and rather flabby and pale on section. The bladder was not in any way diseased, and contained about six ounces of limpid urine. The colon was free from disease, but the coats of the rectum, where forming the boundary of the abscess, were thinned and easily lacerable. The gut contained yellow fæces, and presented no appearance of ulceration. Except in the pelvis, there were no traces of peritonitis, either old or recent. The other abdominal organs were healthy, but the small intestine and the upper part of the alimentary canal were not laid open. At the apex of the right lung there was an extremely well marked cicatrix, about the size of a crown-piece, with three or four isolated masses of putty-like tubercle around it. Some of these masses were larger than horse-beans, and all were surrounded by distinct and thick false membranes. The left lung contained no tubercle; the surface of each lung

Digitized by Google

Digitized by Google

DESCRIPTION OF PLATE VII.

FIGS. 1 and 2 illustrate Dr. Peacock's case of calculous abscess in the pelvis. Page 196.

Fig. 1. The calculus and its cyst.
Fig. 2. The calculus removed from the cyst.

FIG. 3 shows a peculiarly-shaped calculus removed from a cyst in the bladder, by Mr. Heath.

Digitized by Google

Fig 2.

Fig 3.

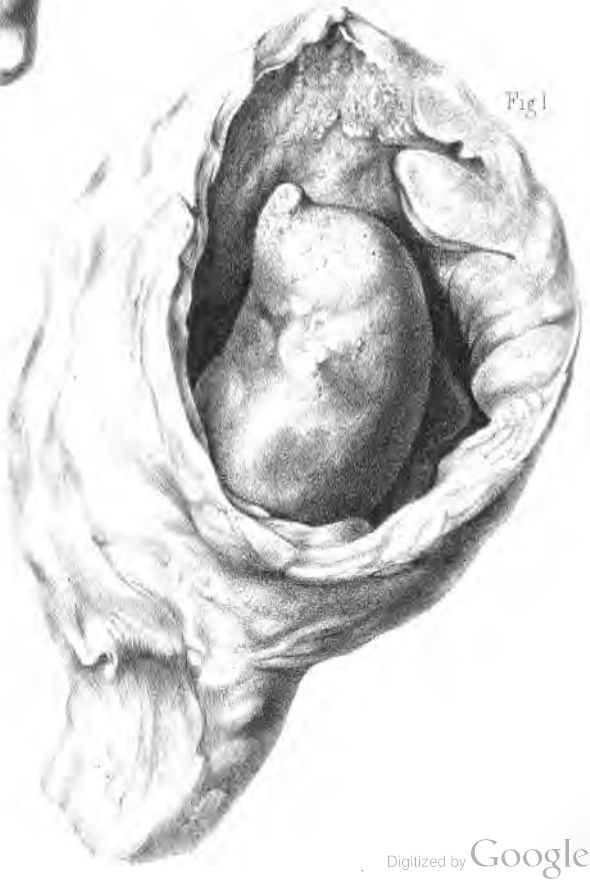

Fig 1

Digitized by Google

UNIV. OF MICH.

Tuffen West del. et. lith.

Ford & West imp. 54 Hatton Garden

Digitized by Google

was in places emphysematous. The heart was large and flabby.

In forming an opinion of the nature of this case, when the patient was seen, the previous history, though then less fully ascertained than since his death, at once directed attention to the condition of the kidneys and bladder as the seats of disease. In the absence, however, of any symptoms referable to those organs at that time, it appeared that the more recent symptoms had some other origin; and from the repeated attacks of diarrhœa and increasing emaciation, I was led to infer either that there was a deep-seated tumor connected with the mesentery and glands in the course of the iliac vessels, by which the absorption of chyle was prevented, and the veins were compressed; or what, from the absence of any evident tumefaction of any part of the abdomen, seemed more probable, that there was ulceration of the intestines, and that the œdema of the leg was due to the obliteration of the veins from the formation of fibrinous coagula, as is so frequently seen in the last stages of exhausting diseases. Whether the latter condition did not exist cannot be ascertained, as the upper portion of the alimentary canal was not examined. It is questionable whether, if an examination of the rectum had been instituted, the calculus could have been detected.

Dr. Peacock, 1*st of February*, 1853.

9.—*Large Cyst connected with Right Kidney.*

George L., aged sixty-two, was seen for the only time by Dr. Hare on the 5th of March, 1853; he was then evidently in a dying state, so that the examination made and the history obtained were necessarily imperfect; the following, however, is an outline of the facts ascertained, partly at that time, and partly communicated by Mr. Squire, under whose care he had been.

He was formerly a labourer, and more recently had been a carriage-cleaner, but from March, 1852, had given up work, and in October of that year had been admitted into the St. Marylebone Infirmary. For twenty years past had been a gin-drinker: he mentioned that some eight or ten years past,

Digitized by Google

he had had pain occasionally in the lower part of right side of the abdomen, and for nearly the same time there had been some swelling about the same part; his account of himself was not, however, in consequence of his almost moribund state, to be much depended on, so that it is doubtful whether there was any tumor there prior to about Christmas, 1850, when he got a gripe from a horse across the right lumbar region, which was described as having produced ecchymosis from the spine to the umbilicus; from that period he stated that he had "felt a weight and hardness there." When he entered the workhouse in October, he was emaciated and sallow, very feeble, and walked up stairs with difficulty. There was some anasarca, almost confined to the feet and ankles; the abdomen was rather large and generally full, the fulness being more marked at the right hypochondrium and in right humbar region than elsewhere; there was dulness and resistance there, and the existence of a tumor was evident, but it at that time appeared to be continuous with the liver; some dulness at the apex of the left lung was also noted.

He improved sufficiently to leave the infirmary on the 7th of December, and from that time Mr. Squire did not again see him till a few days before his death; the patient had, in the interim, lost much flesh and become much weaker.

When seen by Dr. Hare, he was exceedingly emaciated; complexion somewhat sallow or dirty-looking; he was lying on his back with head and shoulders raised; his respiration was difficult, with much mucus in the chest and throat.

In consequence of his great emaciation, the abdomen was much depressed above the pubes and over each iliac fossa, but much more so over the left one than the right; the right half of the abdomen, from the margin of the lowest costal cartilages nearly as far as pubes, was occupied by a tumor which extended transversely to beyond the umbilicus: it raised that side of the abdomen in the costo-iliac and right umbilical regions considerably higher than the corresponding parts of left side, giving the former a somewhat rounded appearance. On palpation a somewhat oval tumor was felt in right side of the abdomen; its surface convex and smooth; over the greater

Digitized by Google

part of it there was dulness on percussion, but some intestine overlapped its lower and inner part, thus producing a resonant stroke-sound; there was also resonance on percussion between the upper and inner border of the tumor and costal cartilages, though the upper and outer portion of it passed underneath the costal cartilages. The superficial veins of abdomen and lower part of the thorax to about the level of the nipple, were very much enlarged, especially over the right half of the abdomen; below the umbilicus they were also very tortuous: on emptying a portion of one of the veins of blood, by means of pressure, the vessel refilled from below. There was some swelling of both lower extremities, especially of the right one.

He died the same day, or the day after he was seen by Dr. Hare, colliquative diarrhœa appearing to be the immediate cause of his death.

Post-mortem examination.—Body much emaciated; the enlarged superficial veins very much less marked than during life; œdema of both lower extremities, somewhat more of right than left.

On opening the abdomen a large tumor was seen occupying the right half of it, and extending, about the region of the umbilicus, to beyond the median line of the body; the tumor was covered by peritoneum; and superiorly was, to some extent, overlapped by the edge of the right lobe of the liver, but a space existed between the right part of the border of the left lobe of the liver and the tumor; its left upper part was in contact with, and partially covered by, the pyloric end of the stomach, the shape of which viscus was somewhat rounder than usual. The lower part of the ascending colon lay in front of the lower part of the tumor, passing somewhat obliquely across it, from its inferior extremity to above the middle of its left border, whence the transverse colon extended almost horizontally to the left crista ilii, and terminated in an acute bend in the descending colon, which was much more flexed than natural; the caput coli extended below the inferior border of the tumor, and was much compressed between it and the brim of the pelvis; it was of a dark purplish colour externally, and felt

Digitized by Google

much thicker than natural; when cut into, the mucous membrane presented a remarkable appearance, being of a very dark purple colour, exceedingly thickened and uneven on its surface —mulberry-looking; there were also some patches of ulceration of mucous membrane in the caput coli, and along part of the large intestine. On subsequent microscopic examination it was found that the apparent hypertrophous condition of the mucous membrane just alluded to, depended upon an enormous aggregation of epithelial cells on its surface.

The liver was considerably enlarged, so as to extend to the extreme end of the left hypochondrium; the enlargement was chiefly due to the left lobe; it extended considerably higher than natural into the thorax, but much higher on right than left side; it also projected a short distance below the edges of the costal cartilages.

On removal, the tumor was found to be ovoid in shape, $6\frac{3}{4}$ inches in its longest diameter, and 6 transversely, and when laid on the table it measured $3\frac{1}{2}$ inches in thickness; it was of a light reddish-brown or fawn colour, and gave clear signs of fluctuation on percussion. At the posterior and outer part there projected, as it were, from it, the upper half of the right kidney; the pelvis of the kidney, and the ureter lying somewhat flattened at the back of the tumor, but neither the pelvis of the kidney nor the ureter was dilated; the lower half of the kidney was partly spread over some portion of the surface of the tumor, and partly absorbed. On opening the tumor, it was found to consist of a large cyst, the walls of which varied in thickness, but were for the most part from $\frac{1}{4}$ to $\frac{1}{2}$ inch in thickness; the outer portions of the cyst-walls were dense; the inner part was of a very light gray colour, with a slightly yellowish tinge, the surface being, moreover, rather flocculent, and somewhat soft; it consisted of fibrine. The contents of the cyst were an almost transparent pale yellowish-green fluid, quite limpid when the cyst was first opened, with the exception of a few flocculi (similar in colour and appearance to the lining membrane of the cyst) floating in it; after the fluid had been exposed a few minutes to the atmosphere, it formed a tremulous gelatinous mass. There was no communication between the

Digitized by Google

cyst and the pelvis of the kidney, but at one part the walls of the pelvis formed the only walls of the cyst. The portion of the kidney remaining appeared quite healthy, nor did it, nor the other kidney, contain any other cyst, with the exception of one about the size of a hemp-seed. The weight of the tumor, before it was opened, and with the portion of the kidney attached, was 3lbs. 0¼oz.

The left kidney measured 4½ inches in length, by two transversely.

There were a few largish tubercles (crude) scattered through both lungs, and at the apex of the left (?) were two cavities, one of which would admit a large horse-chesnut, lined with an exceedingly fine, thin, and smooth membrane; there was no cretaceous matter in the walls of, or surrounding, these cavities, which, indeed, were not very unlike one form of dilated bronchi.

Dr. HARE, *15th of March*, 1853.

10.—*Peculiar Form of Uric Acid Crystals.*

The crystals are in the form of spherical or polygonal grains, $\frac{1}{800}$ inch in diameter, showing a concentric and radiated structure. They dissolve almost entirely in liquor potassæ, leaving behind some granulous film, and some transparent capsules of homogeneous membrane. Acetic acid throws down a granular precipitate of protein-substance, and afterwards crystals of uric acid of an elongated shape. Nitric acid dissolves the grains with strong effervescence: the solution evaporated yields a pink colour. The grains, when crushed, show no crystalline structure.

The urine deposits these grains as it cools, is acid, slightly albuminous, contains mucous corpuscles, and a few faint casts.

The patient suffers from irritability of the bladder and urethra, but is in tolerable health.

Dr. HANDFIELD JONES, *21st of December*, 1852.

Digitized by Google

11.—*Peculiarly-shaped and Encysted Calculus.*

Mr. G. J. Y. Heath gave the following details of the case: "This calculus, which is of a very peculiar shape, was removed by Mr. H. Heath from the bladder of a lad of fourteen years of age, a patient in the Newcastle-on-Tyne Infirmary.

"He had begun to exhibit symptoms of stone at the age of three; but latterly, and especially whilst in the infirmary, it was observed that his symptoms were of a much less aggravated character than those from which persons afflicted with this complaint usually suffer. He was able to move actively about, without pain; neither did he suffer whilst or after making water.

"The stone was distinctly felt by the sound.

"On introducing the forceps at the time of the operation, the stone could not at first be found. The operator, in consequence, passed the right fore-finger into the bladder, and on turning it upwards, towards the pubes, detected the stone behind that bone. It was then easily seized by the forceps passed in that direction. On making a gentle movement to extract it, however, a portion of the calculus, afterwards ascertained to be the projecting knob, was broken off, and came away in the forceps. (Plate VII. fig. 3). The finger now detected the fractured extremity of the little neck, connecting the knob with the body of the stone, closely surrounded by what seemed the mouth of a sac.

"It was impossible to extricate the calculus from this cyst without using the knife. The mouth of the sac, therefore, was slightly and very carefully slit up with a probe-pointed bistoury. The stone was then picked out of its bed with the finger and thumb. After the removal of the stone the finger could be passed into the sac, as though into the finger of a glove, whilst within the sac the symphysis pubis was felt above, and the rami of the pubic bones on either side of the finger.

"The patient recovered without any unusual symptoms."

Dr. R. Quain, for Mr. Heath, *15th of March*, 1853.

Digitized by Google

12.—*Large Calculus from a Boy.*

This specimen was taken from a boy aged fourteen years. He came up from Maidstone, and was admitted into Charing Cross Hospital, under Mr. Hancock, five weeks since, with all the more distressing symptoms of stone. Seven years previously to this, he had laboured under the same symptoms, which not yielding to treatment, he was sent to an hospital for operation; but as the stone could not then be detected, he returned to the country. The boy again becoming much worse, his friends sent him up to Mr. Hancock. Chloroform was administered, and the usual operation performed; but from the size of the stone, the external opening required to be enlarged. It was then extracted, and found to weigh two ounces (sixteen drachms). Upon splitting, it presented a fine specimen of the common lithic-acid calculus; the centre nucleus being composed of lithate of ammonia, surrounded by a layer of oxalate of lime; then a series of crystallized laminæ of lithic acid, mixed on the outer parts with more or less of the phosphates.

In four weeks from the operation, the boy was running about the wards well; the external opening closed; the urine perfectly retained, and passed in a full stream.

Mr. Jabez Hogg, *3rd of May*, 1853.

13.—*Quasi-organized Fibrin discharged by the Urethra.*

The specimen, of which a portion was placed in the field of the microscope, consisted of a somewhat oval mass of fibrin, a little more than an inch in length, and about one-third of an inch in diameter at its broadest part. It was irregular and villous-like on the surface, and at one end presented an appearance as if it had been broken or separated from some part to which it had been attached. The mass had a pinkish buff colour, tore into shreds, and when treated with acetic acid, swelled up and became transparent. Mr. E. Baker, to whom Dr. Quain was indebted for an opportunity of examining the specimen, was satisfied of the presence of vascular points in the recent preparation. When placed under the microscope,

Digitized by Google

the appearance figured in plate VIII, fig. 4, was shown. The drawing has been made with great care, and will afford a better idea than any description of the object could do. The ramified character of the vessels is distinctly seen: they want, however, the distinct organization which vessels present, and when found, these ramifications seem to lose still further the characteristics of vessels. Considerable doubt was entertained by different competent observers as to what was the real character of these appearances, nor was it possible to decide the point. Whether vessels or not, Dr. Quain thought it well that the facts should be recorded; for if this was a specimen of organized fibrin, the fact was a most interesting one in the pathological history of this substance; if not, appearances so deceptive ought to be made familiar to those engaged in pathological investigations. The history of the case was one of great length and considerable interest. It was that of a lady now at an advanced period of life, who for many years had passed more or less constantly chylous urine. Her case had been investigated by Dr. Prout and other observers; but on no occasion had anything similar to the present substance been discharged. It had caused much inconvenience and difficulty in its passage. Dr. R. QUAIN, *17th of May*, 1853.

14.—*Case of complete Obstruction of the Urethra.*

The patient, aged fifty-three, who was the subject of this disease, was admitted into St. George's Hospital under the care of Dr. Nairne, on the 11th of November, 1852, with disease of the heart and kidneys, of which he died three months after his admission. During his residence in the hospital, he never complained of any difficulty in passing his water, nor did he make any allusion to the existence of any disease in the urethra. From these circumstances, unfortunately no history of his case could be obtained. During the examination of the body, it was ascertained that there was complete obstruction of the urethra for the extent of four inches. On introducing a probe into the meatus urinarius, it was found that the canal of the urethra was completely obliterated about two inches from

Digitized by Google

the orifice, and this obliteration extended as far back as within an inch of the termination of the spongy portion of the urethra. There was a fistulous orifice in the perinæum, situated immediately behind the scrotum, and on the left side of the perinæal space. This orifice was just sufficiently large to admit a large-sized probe, and led into a long and somewhat tortuous fistulous canal, which opened into the front part of the membranous portion of the urethra. The structures in the neighbourhood of the fistulous canal were very dense, hardened, and contracted, apparently the result of old inflammation. The urethra behind the internal orifice of the fistula was very much dilated, and the prostatic ducts much larger than natural. The bladder was contracted, but its muscular coat was much hypertrophied. Two small pouches formed by a protrusion of the internal lining membrane between the fibres of the muscular coat were found on the left side, and near the base of this organ. The ureters were not dilated; nor was the pelvis of either kidney larger than natural. The kidneys were small: they weighed together four ounces. The cortical portions in both were almost entirely gone, and numerous cysts of varying size were found on the surface, and also in the interior of the organ.

Mr. Henry Gray, *1st of March*, 1853.

15.—*Excessive Enlargement of the Clitoris.*

Mr. Shaw exhibited a fibro-cellular growth, weighing four pounds, and covered with warty vegetations on its surface, which he had removed, a few days before, at the Middlesex Hospital, from a woman fifty-four years of age. The tumor was bilobular, and presented at its lower part, in the mesial line, a depression, which Mr. Shaw considered to be the depression usually found beneath the prepuce of the clitoris. The base of the tumor was broad, and it was freely supplied with vessels in the lower third. The structure of the clitoris was found lost in the base of the growth. Under the microscope, the tumor exhibited in one part a formation corresponding to the subcutaneous cellular tissue of the mons veneris, but in other parts nucleated cells, having tolerably regular

Digitized by Google

outlines, and pale white fibres, containing nuclei, presented themselves. The tumor, according to the patient's account, had existed seventeen years, during the whole of which it had been slowly increasing. Neither its first formation nor its subsequent growth was attended with pain, and it was troublesome only from its large size and great weight. When the patient was first admitted into the hospital, about nine days prior to the operation, the tumor was extremely large, being much increased in size by œdema of the skin and cellular tissue covering it. By rest in bed, however, the fluid thus effused became absorbed, and the tumor shrank considerably in consequence. During the operation very little blood was lost while the upper part of the growth was being dissected away. The lower portions, however, were more vascular, and, being divided, blood issued from the mouths of numerous vessels as freely as water from the rose of a watering-pot. The operation was rapidly completed; about twelve of the largest vessels were secured by ligature, and the hæmorrhage from the remainder was arrested by the affusion of cold water and admission of cold air to the wound. The patient experienced no untoward symptoms after the operation.

From the entire absence of erectile tissue in the substance of the tumor, Mr. Shaw felt disposed to regard it as an example of enlargement of the prepuce of the clitoris, rather than of the clitoris itself; and he was the more inclined to take this view because the true structure of the clitoris was confused and imbedded in the fibro-cellular tissue at the upper part of the base of the mass. Mr. Shaw stated, that about a year before he had removed a tumor from the breast of a woman, the minute structure of which closely resembled that of the growth presented for the inspection of the Society. The Pathological Museum of the Middlesex Hospital contained two specimens of a similar disease developed in the coverings of the generative apparatus, and distinguished by a similar abundance of characteristic warty excrescences on the surface, and a similar production of the fibro-cellular element in the substance of the growth. Mr. Shaw brought forward a cast of the preputium clitoridis of a negro woman, which had become

Digitized by Google

lengthened and hypertrophied in consequence of weights which the females of that race are accustomed to attach to this structure in order to procure its enlargement. He considered that the tumor exhibited to the Society was an example of the like species of hypertrophy carried to an extreme degree.

Mr. SHAW, 16*th of November*, 1852.

16.—*Fatty Degeneration of the Uterine Fibres.*

The uterus was taken from the body of a married woman aged thirty-six, who died in St. Thomas's Hospital, four weeks after delivery. Her death was caused by inflammation of the uterus with purulent absorption. There was a circumscribed peritoneal abscess between the uterus and rectum; recent inflammation of the pericardium and pleura, and purulent deposits in the lungs, heart, and kidneys. The uterus measured about four inches in length, and its walls were a little more than half an inch thick. The mucous membrane, especially that of the os and cervix, was congested, and covered by a small quantity of discoloured mucus. The part to which the placenta had adhered was well-marked, being prominent, discoloured, and somewhat flocculent. The following is Mr. Rainey's report:—"Thin sections of this uterus examined under the microscope exhibit appearances very similar to those described in a former communication of mine on the same subject. (See "Transactions of Pathological Society," for 1851—1852, page 395). In this case the fatty degeneration is better marked than in that, owing probably to a longer time having elapsed from the delivery of the patient to her death. In the first case, the examination of the uterus was made three weeks after delivery; in the present, it was a month. The specimens shown in this instance to the Pathological Society, exhibit unequivocal marks of a fatty state of the uterine muscular fibres, which goes to confirm the correctness of the opinion before expressed, and the justness of the conclusion then arrived at; namely, that this change is most probably a

Digitized by Google

normal one, and that it occurs in the muscular fibres of the uterus in all cases after delivery."

Dr. Bristowe, 19*th of October*, 1852.

17.—*Uterine Tumors.*

About twenty years since Mrs. G. was delivered of a full grown child, still-born. As far as recollection will serve there was nothing peculiar about the case at the time; but in the course of a year or two afterwards she complained of uneasy sensations about the uterus; weight, and fulness; difficulty in stooping; micturition and defæcation painful; vaginal examination gave pain, and the uterus was evidently enlarged. These uneasy sensations were generally relieved, in the course of ten days or a fortnight, by the application of leeches externally, gentle aperients, attention to diet, and absolute rest. In her own mind Mrs. G. referred this, and the subsequent attacks, to the period of her confinement; and these attacks have recurred at intervals of twelve or eighteen months; in fact, whenever she was exposed to cold or fatigue, or her general health was disturbed. Of late years they have generally been associated with hepatic obstruction, terminating in jaundice; the uterus also had become much increased in size, with at times slight leucorrhœa, but no ulceration was visible with the speculum. During this lengthened period the catamenia were regular in their appearance, till about eighteen months since, when (in her forty-sixth year) they finally ceased, without any aggravation of the painful or inflammatory symptoms, though evidently with increased enlargement of the uterus, which rendered the passage of the fæces (unless in a liquid state) a matter of some difficulty and inconvenience.

About six weeks prior to her death, which took place on the 6th of November, 1852, she had a recurrence of inflammatory symptoms, which were much relieved by the application of leeches, and the administration of alteratives and salines. After the subsidence of the urgent uterine symptoms those of the liver became prominent, with almost constant vomiting

Digitized by Google

and pain, and as usual, jaundice; the fever assumed a typhoid character, complicated with meningitis, and she sank rapidly.

Post-mortem examination.—The gall-bladder was enormously distended with bile, and contained about twenty calculi, one of which completely blocked up the cystic duct, and could not be dislodged without breaking up. The uterus was studded with tumors, of the characters of which Dr. Quain has been so good as to give the following description.

Dr. RAMSBOTHAM, 16*th of November*, 1852.

Additional Observations on the Preceding Specimen.—The tumors vary in size from that of a small bean to that of a small-sized hen's egg; in consistence, from that of a solid fibrous tumor to that of liver; in colour, from a pale, pinkish, flesh-colour to a pale yellowish buff. They are all more or less embedded in layers of tissue, from which they can be almost turned out, as if from cysts.

Microscopic sections show, in the more dense tumors, an arrangement of delicate fibres, so interlaced as to form meshes and loculi, more or less oval in form, in which cells exist. The fibres occasionally, though not uniformly, form right angles by their intersections. There is no juice or fluid obtained from the more dense tumors by scraping. There is a thin, opaque fluid to be obtained in small quantity from the softer tumors. This fluid is found to contain a considerable number of cells. These cells are generally spherical; they average the size of pus-globules: some are considerably larger, some smaller. All the cells contain well-marked granules; several two, three, or more small nuclei; and a few larger cells appear as the nidus of several smaller cells. There is no great variety in the form of the cells; they are generally spherical or oval. There is a good deal of fatty matter mixed up with the elements of the softer tumors; and in some parts there is so much earthy matter as to give a calcareous consistence to portions of the tumors.

These appearances do not afford sufficient ground for deciding whether the tumors are of a malignant character or not; this important point appears to me, in this case, to be capable

Digitized by Google

of decision only by a reference to the influence which the disease had exerted over the constitution, and its tendency to appear in other organs and textures.

Dr. R. Quain, 16*th of November*, 1852.

18.—*Fibrous Tumors of the Uterus.—Uterine Polypi.*

The tumor was of an oval form, measuring three inches in its long, and two inches in its transverse, diameter. Its structure presented the usual appearances of the fibrous tumors of the uterus, but was less dense than that usually seen in these tumors when contained in the uterine parietes. It had doubtless been developed in the muscular parietes of the uterus, into the cavity of which it had escaped in consequence of ulceration of the portion of the lining membrane of the uterus, and probably of a thin layer of muscular tissue, which covered its uterine surface. Its expulsion from the uterine cavity was preceded by slight pains, but was not followed by any unpleasant symptoms.

The specimen is in the museum of St. Thomas's Hospital.

Also, a uterus, projecting into the cavity of which were six *Mucous-membrane Polypi;* and in the muscular parietes, two fibrous tumors.

Four of the polypi were about the size of small peas, and were attached by broad bases to the mucous membrane of the uterus, one about the centre of the posterior wall; one a little above this was situated at the angle of reflection between the anterior and posterior walls on the right side, and the other two were attached to the anterior wall, close to the fundus, on the right side. They were all inclined to the spherical form, somewhat altered in shape by compression, and presented a smooth external surface, through the delicate investing membrane of which small vesicles were apparent. On section, they presented essentially similar appearances, and were seen to consist of a congeries of small vesicles intermixed with a variable quantity of areolar tissue; the latter element was most abundant in the polypus springing from the posterior wall.

Digitized by Google

Of the two remaining polypi, one was attached by a very slender peduncle, half an inch in length, to the angle of reflection between the anterior and posterior walls on the right side, a little above the cervix uteri, into the cavity of which it hung. This polypus was of an oval form, measuring half an inch in its long diameter, and on section presented a central cavity, chambered, as if originally consisting of a group of three or four vesicles, and surrounded by close-textured areolar tissue. The other polypus was attached to about the centre of the cervix uteri, at the angle of reflection between the anterior and posterior walls, on the left side: it was of a flattened cylindrical form, about a line in breadth, and rather less than half an inch in length; its free extremity was somewhat enlarged; no central cavity could be satisfactorily traced either in its extremity or body, though it probably existed, as these polypi are usually hollow in their entire length. Imbedded in the muscular substance of the posterior wall of the uterus, towards the fundus, were two incipient fibrous tumors, one measuring three-eighths and the other a quarter of an inch in diameter, of close texture, and presenting the ordinary appearances of these growths; the spherical form, distinct outline, slender connexion with the muscular tissue, curvilinear distribution of dense fibrous bands, &c., were well marked. They were developed close to the peritoneal surface, in which they produced slight elevations.

With respect to the relative frequency of the fibrous-tumour polypus, and the other varieties of polypi, taken as a group, Mr. Adams stated that his experience led him to decide in favour of the latter; for while he had met with many examples of polypi of the uterus connected with and developed from the mucous membrane or its glandular appendages, and situated either in the cervix or body of the uterus, he had seen very few specimens of the fibrous-tumour polypus. Dr. Ramsbotham and Dr. Oldham concurred in the opinion above expressed by Mr. Adams.

Mr. WILLIAM ADAMS, *7th of December*, 1852.

Digitized by Google

19.—*Uterine Polypi.*

Dr. Ramsbotham remarked, that, as the subject of uterine tumors had occupied the Society's attention lately, he wished to exhibit a few specimens, because they tended, in his opinion, to determine the question (which was still *sub judice*) as to some of them being of a malignant character or otherwise. It was true that a section of the common uterine tubercle displayed an appearance very much resembling that of scirrhus. There was the same greyish-coloured matter intersected in different directions by the same kind of thin, dense, white lines, so as to make the appearance of the two surfaces very similar; but he was not prepared to concede that similarity of appearance necessarily involved similarity of nature: he thought something more was required; and, except in this particular, these "fleshy tubercles," as Hunter called them, had no analogy with malignant disease. They did not inoculate the neighbouring organs, not even the glands in their vicinity; and although they sometimes did undergo the process of softening in their centre, that was the exception and not the rule; and they were much more prone to take upon themselves calcareous degeneration. The size which they sometimes attain, too, would argue against the supposition of their malignancy. He displayed one, attached to the uterus, of the size of that organ when eight months gravid. Indications of softening were to be observed in the centre here; but a tumor of a malignant nature did not often acquire such a magnitude. In another preparation there were two tumors, each considerably larger than the fœtal head at birth, placed antero-posteriorly, and compressing the uterus between them. The woman from whom this specimen was taken, died from the irritation which the bladder and rectum, as well as the other pelvic contents, sustained; and in one of the tumors there was a depression moulded on the promontory of the sacrum, large enough to allow the fist of a child three or four years old to lie in it. As a proof how little these tumors interfere with the structure of the different parts of the uterus, unless they are imbedded in its substance, he displayed a pre-

Digitized by Google

paration where a tubercle as large as a pullet's egg was attached by a pedicle to the fundus, and where the os uteri was so natural, that he was in the habit of showing it at his lectures as the best specimen of its shape that he could find. And, further, that they did not prevent impregnation taking place, and gestation going on to a period near the full time, was evident by another, where a transverse rent of the neck of the uterus had occurred in labour; while the whole substance of the body and fundus was largely studded by tubercles of various sizes. It was not uncommon for polypus and fleshy tubercle to exist together. In one preparation there was a fleshy tubercle, a small polypus, and an incipient dropsical condition of both ovaries: and in another the stem of a polypus, which he had removed by ligature, springing from the fundus, while two or three large tubercles were imbedded in its substance. The lady whose uterus was thus diseased died from an accidental cause more than eighteen months after the operation; and it was curious, that although the stem remaining was nearly as long and as thick as a man's thumb, and quite within the uterine cavity, for the last twelve months of her life she menstruated with exactness. Though polypus and fleshy tubercle often existed together, he could not regard them as identical tumors. To illustrate this he showed a polypus, the size and shape of an elongated Windsor pear, attached to the fundus uteri. He could not understand how that shape could be obtained while the polypus was still entirely within the cavity, as in the case under consideration. It could not be fashioned by the shape of the uterine cavity, because it was narrowest where the uterus was widest, and *vice versa*.

Dr. RAMSBOTHAM, 21*st of December*, 1852.

20.—*Fibro-Cystic Tumor of the Uterus.*

The patient from whom this tumor was taken was fifty-six years of age; she was admitted into St. George's Hospital, under Dr. Page, on the 15th of December, 1852, with general dropsy dependent upon old cardiac diseases, and of which she died on the fifth of January, 1853. During her residence in

Digitized by Google

the hospital she never complained of any symptoms to lead to the belief of the existence of a tumor in the uterns; consequently no history of the origin and growth of the tumor was obtained. On making a post-mortem examination of the body, there were found two tumors connected with the uterus. One of these was an ordinary fibrous tumour, growing from the fundus of the uterus; the other was a fibro-cystic tumor, growing from the lining membrane of the cervix. The former was of a circular form, and about the size of a small cricket-ball, growing from between the layers of the muscular coat of the uterus. Towards the peritoneal surface, the muscular coat formed a distinct external investment for the tumor; towards the uterine cavity it also invested it. The cavity of the uterus was compressed and partially obliterated by this tumor.

The fibro-cystic tumor which was found to be connected with the lining membrane of the cervix, was of an entirely different character. Its size and form were not unlike that of a dried plum, and it was connected with the lining membrane by an exceedingly narrow pedicle. In the fresh state, its surface was covered with thick viscid glutinous secretion, of a faint-yellow colour, like the white of egg. The tumor consisted of a congeries of cysts, of a size varying from a pin's point to a horse-bean; their walls were formed of exceedingly dense fibrous tissue, and their cavities contained a thick viscid fluid precisely similar to that found on the outer surface in its fresh state. The neck of the tumor was composed of mucous and fibrous tissues, a continuation of those which form a constituent part of the neck of the uterus. To the pedicle a smaller tumor, about the size of a horse-bean, was found to be attached, the structure of which was in every respect precisely similar to the one above described. The mucous membrane, where it was continued on to the surface of the neck of the tumor, presented a continuation of the same transverse and longitudinal folds that are found on the mucous lining of the cervix, so that it would appear that in the first instance the tumor had originated beneath the lining membrane, which it had pushed outwards, forming an investment for it.

Mr. Gray, 15*th of February*, 1853.

Digitized by Google

21.—*Unusually large Fleshy Mole expelled from the Uterus.*

Mr. Hutchinson remarked that his object in inviting the attention of the Society to the specimen, was to elicit information as to the origin of these formations. Some years ago he had in his possession a fibrinous cast of the whole interior of the uterus, measuring about two inches in length, and one in breadth at its upper part, and presenting at its angles prolongations, which had evidently corresponded with the openings of the Fallopian tubes. It was hollow, and at its lower part showed marks of having been accurately moulded on the os uteri. The walls were composed of firm lymph, and were about an eighth of an inch in thickness. No trace of ovum could be found. It had been expelled by a married woman, who had long suffered from painful menstruation, during an attack of unusual severity. Mr. H. was inclined to question the opinion commonly received, that these formations always resulted from changes in the structure of blighted ova. He believed that they might result from inflammatory exudation from the uterine mucous membrane, analogous to what takes place in croupal affections of the trachea, and some rare forms of enteritis.

The specimen exhibited was a mass about the size of a fist, lengthened out into a shape very strikingly resembling that of an unimpregnated uterus. It was solid and firm in all parts, and its section presented a vascular surface, composed of tough and organized lymph, in which were embedded numerous small white bundles, about twice the thickness of a pin. These latter might be readily drawn out, being enclosed in a smooth, glistening envelope. When unravelled and placed under the microscope, they were seen to consist of delicate fibro-cellular tissue. The greater part of the mass had the structure just described; but at its lower part, posteriorly, was an irregular portion, the size of a walnut, which cut smoothly, and much resembled decolorized blood-clot. It was not hollow, though its centre was less solid than other parts. Its surface was smooth and rounded, and had attached to it the remains of thin areolar membrane, by which it would seem to have maintained a connection with the mucous membrane of the uterus.

Digitized by Google

It had been expelled by a married woman, aged twenty-six, the mother of three children, of which the youngest is now two years and a-half old. She menstruated last in February, 1852, and three months afterwards began to suffer from dragging pain in the side, which was soon after followed by a discharge of bright blood. The latter symptom subsided in the course of a day or two to a mere draining, which then lasted for two months, at the end of which time she noticed a hardness in the left iliac region, attended with a sense of weight and coldness in that part. These symptoms increased, and being unable to satisfy herself as to her condition, she, in November, 1852, put herself under the charge of the obstetric physician to the London Hospital, and continued in attendance until the following February. On February 9th, a powerful dose of cathartic medicine was prescribed, and under its operation she was on the following day seized with bearing-down labour pains, which in the course of twelve hours terminated in the expulsion of the mass exhibited. Moderate hæmorrhage attended the expulsion, and continued to recur for several days afterwards.

The case occurred under the care of Mr. Filliter of Bethnal-green Road. Mr. HUTCHINSON, *15th of March*, 1853.

22.—*Muscular (so-called Fibrous) Tumors of the Uterus.*

The specimen exhibited was one of some interest; it was removed from a patient whose case is related by Dr. Waller in the "Medical Times and Gazette," for April, 1853. The following is a very short abstract: A healthy woman, forty-one years of age, had been married fifteen months, during which time she had miscarried twice, but in a third pregnancy succeeded in attaining the full period. No sign of uterine affection appeared during utero-gestation, except a slight and easily-arrested hæmorrhage about the end of the eighth month. When labour came on, a large tumor of bony hardness, supposed to be an exostosis, was found to obstruct the passage of the child. As it was impossible to deliver the woman *per vias naturales*, the Cæsarian section was had recourse to. She survived the operation thirty-six hours.

Digitized by Google

Post-mortem examination.—The tumor supposed to be an exostosis, was found to be really a fibrous tumor, occupying the space between the rectum and vagina. The uterus itself measured five inches in length, the incision four. The os, cervix, and anterior wall were healthy, but the lips of the incision gaped widely, being apparently prevented from closing by the traction exerted on them by the tumors behind. The fibrous tumors were connected solely with the upper two-thirds of the posterior wall of the uterus, and formed an irregular lobulated mass about nine inches long, five broad, and three or four deep; the mass scarcely extended higher than the summit of the uterus, but quite three inches below the os, and as much as five below its lowest point of attachment. The depending portion terminated in an irregular, lobulated, pedunculated mass, about the size of a large orange. It was this that had impeded parturition. On section, the muscular tissue of the uterus was found to envelop some of the tumors, but in others to extend merely for a short distance into their base; this was the case with that hanging into the recto-vaginal pouch. The tumors presented the ordinary characters of fibrous tumors; were denser than the uterine walls, somewhat fleshy in appearance, and constituted of fibres curving and twisting in all directions with the utmost complexity.

The present seemed a favourable opportunity for investigating the real nature of the so-called fibrous tumors. Vogel, in his "Pathology," states that some at least of these growths are really muscular, and absolutely identical in structure with the walls of the uterus; but so far as I have been able to learn, the observations of this pathologist seem to have been confined to the unimpregnated organ. Now the tissue of the undeveloped uterus is so difficult of satisfactory investigation, presents so little that is characteristic, and the nucleated fusiform fibres which become developed into muscle are so much like those found in various other organs and tissues, that it might reasonably be doubted whether there was not some little error in the observation, or whether, supposing the anatomical characters to be really the same, the tissue of the tumors was not physiologically distinct from that of the uterine walls. I have, on

Digitized by Google

several occasions, compared the structure of fibrous tumors with that of the uterus, and so far as these observations went, they were confirmatory of Vogel's views; still the examinations had always been somewhat superficial; and I had a thorough conviction in my own mind, that however much they might resemble, they were far from being identical with one another, and that careful investigation under favourable circumstances, would establish the correctness of this, and the error of the former view.

The chance of examining these tumors in the fully-developed uterus, was too good an opportunity for settling this doubtful point, to be neglected; for it was clear, that if the tumors were really muscular, they would become developed with, and in proportion to, the walls of the uterus itself; their elementary structure would resemble that of the gravid organ, and would consequently possess scarcely any features in common (so far as microscopic examination was concerned), with those presented by ordinary fibrous tumors; whereas, if the tumors were essentially fibrous, they (while the walls of the uterus became developed into muscular tissue) would retain their primitive character, or at most undergo such slight alteration as the increased vascularity and activity of surrounding structures were capable of effecting, and therefore would contrast remarkably with the walls of the organ in which they were embedded.

The microscopic examination of the tumors and of the uterine walls was conducted with considerable care. Portions of different tumors (taking care not to mistake any of the muscular tissue enveloping them for the tumors themselves), were submitted to examination; and contrary to anticipation, in all instances, without exception, were found to present precisely the same characters as the muscular tissue of the uterus itself; they were so similar indeed, that it was quite impossible to say of any specimen observed under the microscope, whether it was taken from the normal or from the abnormal structure. The tumors consisted of fusiform, pellucid, fasciculated muscular fibres, identical in size, shape, general appearance, and arrangement, with those of the uterine

Digitized by Google

parietes. There did not appear to be more fibrous tissue in the tumors than in the uterus, and though it is true that the fibrous tumors were denser than the parietes of the womb, this was a distinction quite unappreciable under the microscope. See figs. 5 and 6.

Fig. 5.



Fig. 6.



(For a description of the fibres of the uterus, refer to Mr. Rainey's paper in the "Philosophical Transactions" for 1850, pt. ii., p. 515; and for additional drawings, either to the plate accompanying that paper, or to a plate of the preceding volume of the Transactions of the Society).

Through the kindness of Dr. Crisp, I have had another opportunity of examining the structure of fibrous tumors in the gravid uterus. The case is recorded in the "Transactions

Digitized by Google

of the Medical Society of London," first vol. new series, p. 122. The patient was thirty-six years of age, and pregnant with her sixth child; her last was born nineteen months previously, with no unfavourable symptom: six months subsequently to this event she miscarried. The only sign of anything wrong during the present pregnancy, was the occurrence of occasional slight hæmorrhage during the last six weeks of gestation. The tumor did not impede the birth of the child, but the patient died four days after delivery, apparently from exhaustion. The tumor proved to be a fibrous polypus, springing from the right side of the uterus above its neck: it was ovoid, and measured fourteen inches long by five thick.

In this case the tumor had been for several years in Goadby's solution: still, under the microscope, it was seen clearly to consist of muscular tissue, arranged as above described; the individual fibres being merely somewhat corrugated and irregular in outline from the action of the fluid in which it had been immersed. See

Fig. 7.



These two examinations, the only ones I have had the opportunity of making, confirm in a remarkable and (to me) unexpected manner, the statement made by Vogel; and from the condition of the organs with which the tumors were connected, they are clearly free from all fallacy. The questions now to be determined are:—"Do all so-called fibrous tumors resemble these? or are such cases as the present to be looked on as rare and exceptional?"

It is true that uterine fibrous tumors do present certain differences among themselves; some are harder, some softer than others; some redder, some paler; in some the arrangement of the fibres is exceedingly complex, in others com-

Digitized by Google

paratively simple; still, in spite of these and other variations, they have all so many characters in common, that they have almost invariably been included under the same name—fibrous tumor. The tumors under consideration resembled these; the arrangement of the fibres to the naked eye was like that of fibrous tumors generally, the only difference being, that they appeared somewhat softer and more succulent than usual, a difference readily accounted for. From these facts I am induced to express a confident opinion that further examination will prove that all so-called fibrous tumors of the uterus, at least in their earlier stages before degeneration has taken place in them, are essentially muscular tumors, not simply fibrous tumors containing a greater or less quantity of muscular fibre mixed up with them, as Mr. Paget seems to think, but developments of true and undoubted muscular tissue, to which the term of muscular tumor, and that term only, is strictly applicable.

This view of their character may possibly be advantageously borne in mind and acted on in practice, for from their very nature, it follows that they must during pregnancy enlarge in an equal ratio with the uterus itself; so that a tumor of small dimensions, and unattended with inconvenience, may during this period attain to very considerable bulk, and from its situation and size interfere seriously with the parturient process, or in other ways induce dangerous or fatal consequences. I am aware that there is no novelty in stating that they *do* grow during pregnancy, but the preceding view of their nature may serve to impress that fact more vividly on the mind, since it shows that they *must* grow, not in that vague sense which is conveyed in the statement that they grow from partaking in the activity of neighbouring structures, but in that positive and determined manner which is expressed by the fact that they must, from the very nature, at least attain a bulk the ratio of which to its former bulk is that of the gravid to the unimpregnated uterus.

Dr. Bristowe, 19*th of April*, 1853.

Digitized by Google

23.—*Encephaloid Cancer of the Uterus, with secondary affection of the neighbouring Lymphatic Glands.*

A. B., a married woman, thirty-nine years of age, was admitted into St. Thomas's Hospital under Dr. Waller's care, labouring under cancer of the uterus. At time of admission she was in a state of great prostration, and died at the end of three weeks. During her stay in the hospital she passed per vaginam fragments of soft, white, encephaloid matter, varying from the size of a filbert downwards, accompanied by a most offensive discharge, but no hæmorrhage.

Autopsy.—The body was extremely emaciated; the right lower extremity œdematous, and its superficial veins enlarged and tortuous. The uterus was somewhat hypertrophied, yet scarcely altered in shape; its muscular tissue was generally a little indurated; the mucous membrane of its fundus was soft and pulpy, and some of the subjacent muscular tissue appeared to have been destroyed. Its cervix had almost entirely disappeared, a ragged, ulcerated surface being left facing the vagina, except on the left side; and here a granular or nodular pulpy mass was prolonged from it and continued into the walls of the upper part of the vagina. The upper half of the vagina was in an ulcerated and granular condition; the state of the lower part of this surface appeared to be and probably was simply the effect of excoriation; the upper, however, was much more extensively destroyed (little more than peritoneum being left behind), and, together with the ulcerated neck of the uterus, formed beyond doubt the base whence sprung the encephaloid mass which during life had been so copiously discharged. The nodular mass before alluded to, and an occasional pulpy granulation, indicated such to be the fact. The Fallopian tubes and ovaries were healthy, the surface of the latter being simply a little thickened and fissured. Neither the bladder nor the rectum was involved in the uterine disease.

In the left iliac fossa, upon the ileo-pectineal line, and between this and the external iliac vessels, which were lifted up by it, was a tumor as large as a hen's egg. On section it was clearly seen to be produced by an encephaloid condition of the

Digitized by Google

lymphatic glands; it consisted of a soft, white material, yielding a creamy juice, marked with occasional vascularity, and presenting two or three small, firm, yellowish deposits. The outline of many of the original glands (increased somewhat in size) was well marked. Some few of the glands in the lumbar region of this side were to a greater or less degree similarly affected.

The right side of the abdomen was occupied by an irregularly-ovoid, and somewhat lobulated tumor, about equal in bulk to a large cocoa-nut. Its central part filled the right iliac fossa, whence it extended upwards into the lumbar region as far as the kidney, downwards into the upper third of the true pelvis, forwards beneath Poupart's ligament; and on the outer side of the femoral vessels for two or three inches down the thigh. It lay quite behind the peritoneum, upon the muscles and ureter; the outer part of the broad ligament of the uterus was somewhat dilated to receive its largest anterior lobule (as large as half a hen's egg), yet it can scarcely be said to have been occupied by any part of the tumor. Its peritoneal surface was smooth and shining, and the deep livid hue of some portions was readily discernible through it. The tumor conveyed, especially in its more prominent parts, a decided sense of fluctuation, so that its cystic character was anticipated. Its section presented a very remarkable appearance: it seemed more like that of a diffused aneurism rather than anything else, or like the cavity of the heart distended with a mixture of the various forms of coagula there found. On closer examination, however, it appeared that rather more than one half of the tumor consisted of encephaloid matter, a mass as large as a moderate sized orange occupying its posterior and inner portion, and the remainder forming the walls of a series of intercommunicating cysts filled with coagulum. This presented the most varied appearance, being in some parts recent, soft, black-currant-jelly-like; in others fibrinous, more or less laminated, elastic, and much resembling in character the fibrinous coagula of the heart. The degree of coloration varied between these extremes, and the consistence presented an equal range. The coagula or their interstices were infil-

Digitized by Google

trated with a large amount of brownish, tolerably-transparent serum, the presence of which had contributed to produce the sense of fluctuation before remarked. The actual wall of the cystic portion of the tumor, that is, the layer of actual cancerous matter which limited it, was for the most part exceedingly thin and somewhat transparent, but it was connected externally with neighbouring parts, such as fat, muscle, peritoneum, &c., which virtually aided in the formation of the parietes, and gave them a degree of strength and thickness they would not otherwise have possessed. The inner surface of these parietes was everywhere studded with outgrowths of cancerous matter, varying from points scarcely visible to the eye to nodules as large as a filbert: the smaller ones were globular, the larger more or less irregular from the presence of secondary growths which projected from their surface. Many of the smaller ones sprang from broad bases, but the majority, including those of larger size, were connected by comparatively narrow attachments, though never perhaps actually pedunculated. They were smooth and shining on the surface, as though covered by a serous investment. In substance they were soft; in colour white and opaque, often more or less streaked and infiltrated with blood, and not unfrequently converted into cysts filled with coagulum. From the parietes numerous septa projected into the cavity of the tumor, so as to divide it more or less perfectly into a cluster of secondary cysts. In some instances these septa were tolerably thick, had a definite margin, and were formed of a central lamina of fibrous tissue prolonged from the external healthy parts, carrying with it (as it were) a duplicature of the cancerous layer, thus appearing to be an indication of the original lobulation of the tumor. More frequently, however, they were exceedingly delicate, varying in thickness between that of ordinary writing and tissue paper, and were prolonged irregularly among the clots separating them more or less from one another, and finally losing themselves among them. Each kind of lamina was studded with cancerous growths like those before described. In the latter variety, however, they were generally somewhat small, and in some cases their number and

Digitized by Google

size appeared to diminish inversely as their distance from the parietes of the tumor.

Besides laminæ, thin filaments were prolonged from the walls of the cavities into the substance of the clots; these were sometimes very thin and transparent, at others more or less encroached on at their bases by encephaloid matter, and even in their course presented nodular enlargements. The clots varied in their degree of adhesion to the containing parts, and in some cases, of which the prolongation of the tumor into the thigh was an example, were very readily separable. Some of the coloured clots were distinctly invested by a thin, colourless film, which was evidently merely a discoloration and condensation of their surface; but whether in any case these became attached by the malignant growth, and thus assisted in forming the before-described laminæ, was not very clear.

The solid part of the tumor, which consisted of encephaloid matter, was for the most part soft, had an opaque white colour, yielded cream-like juice, and had the ordinary characters of soft cancer; but it was permeated by numerous cavities and channels of various size, containing coagula of different ages, and presenting on a small scale the characters of the coagula before described. A few were filled with a kind of reticulum, infiltrated with serum, possibly the remnant of pre-existing clots; some of these cavities had smooth surfaces, and in a small number slight traces of nodular growth were observable. The external iliac artery and vein were raised from their position by the tumor, and, though passing through its substance, were much nearer its anterior than its posterior aspect; the walls of both were unaffected, but the vein was much compressed, and its opposed surfaces adherent in one or two places by thin bands; the lower half of the vein contained in the tumor was filled with a flattened, tough, buff-coloured, adherent coagulum. This increased in quantity when the pressure was absent, and all the veins of the thigh, as far as they were traced (nearly to the knee), were distended with adherent coagula, which assumed more and more the colour of the blood in their passage down the thigh. The inferior cava

Digitized by Google

contained a thin cylinder of post-mortem coagulum, entangled in which, a little below the renal veins, was a tough, buff-coloured, ribbed coagulum, about as large as a bean, which had evidently been carried to this point from the external iliac vein. There was no trace of inflammation or other change in the vena cava. All the other organs of the body were healthy.

Specimens from different parts of the morbid growths were examined by the microscope, and presented a considerable uniformity of structure. Fragments that came from the uterus during life were found to consist almost entirely of nucleated cells, presenting something of a cylindrical arrangement, and the same was observed when the parts were examined after death; it appeared that in the diseased mass there was a tendency to a papilliform mode of growth. The encephaloid nodules of the tumor in the right iliac fossa were formed altogether of nucleated cells, generally of a globular or more or less irregularly polyhedral form, and varying between the $\frac{1}{400}$th or $\frac{1}{300}$th and $\frac{1}{2000}$th of an inch in diameter; the smaller ones contained one nucleus, the larger two, three, or even more. The nuclei varied between the $\frac{1}{1000}$th and $\frac{1}{3000}$th of an inch, and frequently presented one, two, or three nucleoli. The cell-walls were thin, and for the most part easily distended by endosmose; their contents were faintly granular, and in some instances studded with oil or even converted into compound granule-cells. The delicate transparent laminæ lying between contiguous coagula appeared to consist solely of layers of these cells; and the nodules springing from them were composed of aggregations of the same into hemispherical masses, aparently uncovered by any investing membrane. The clots exhibited the usual microscopic characters. The larger encephaloid mass presented cells in abundance, but they were less perfect, and intermingled with numerous granule-cells and molecular, oily matter. The tumor in the left iliac region was similar in structure.

The chief, and perhaps only point of interest in this case, is the character of the tumor occupying the right side of the abdomen. How is it that a tumor in that particular situation should present that peculiar form of growth? If the presence

Digitized by Google

of a cyst be once explained, the nodular form of growth is not in itself remarkable, for it is the ordinary mode in which soft cancer developes itself on the surface of natural serous membranes, such as the pleura and peritoneum, and even on that of abnormal ones, as appears to have been the case in a specimen of cancer attacking a cystic ovary, exhibited by myself during the last Session. The main question then, is, How did the cysts originate? for there can be little doubt that the tumor originally was solid and glandular, like that occupying the corresponding situation on the left side. The explanation I am disposed to offer is this:—The solid encephaloid glandular mass having attained a certain size, became in places softened and degenerated; the vessels being involved in these changes ruptured, and gave origin to more or less copious extravasations of blood, which, like apoplectic effusions, infiltrated and destroyed the surrounding textures; the consequence was the formation of a series of cavities filled with coagulum, and communicating more or less one with another; the walls of these, like those of apoplectic cysts, at first ragged and ill-defined, gradually assumed a smooth and cyst-like character; but formed as they were of malignant structure ever ready to burst into active growth, that passive condition of surface was little likely to be retained, and speedily gave origin to nodular encephaloid growths.

That such was the mode of formation is not improbable; for, in the first place, extravasations of blood are known to give rise to cysts, apoplectic cysts to wit; the same also appears to have happened in a tumor removed from the thigh by Mr. Solly, an account of which was given by me in the last volume of the Society's Transactions: 2ndly, All the cavities in the tumor under consideration were loaded with extravasated blood, this appearing to hold true, both of the smaller cavaties in the solid portion of the tumor, as well as of the larger and more manifest cysts; moreover, many of the nodular growths were themselves infiltrated with blood, or even converted into cysts filled with coagulum: and 3rdly, Had they originated in any other way, it seems scarcely probable that the evidences of that origin would have been so effectually concealed.

Digitized by Google

The septa dividing the coagula from one another may have been produced in more ways than one. 1st, In some cases they were probably the remains of the original structure that intervened between the primary extravasations: 2nd, In other instances there seems reason to believe that they were the remnant of the boundary wall of large-sized nodular growths which had been converted into secondary cysts by extravasation into their interior: and 3rdly, It appears not improbable that occasionally the surfaces of clots had become the seat of encephaloid deposit; and this was borne out to some extent by the fact of the numerous filaments (which attached them to the surrounding parts, and which were probably recent organic connections marking the commencing organization of the clots) being more or less encroached on by the cancerous deposit.

These explanations are not to be considered as applying to those partial but thick and definite septa which have been already alluded to, as being probably indications of the original lobular condition of the tumor.

Dr. Bristowe, 1*st of February*, 1853.

24.—*Tubarian Pregnancy.*

Dr. J. Hall Davis exhibited a fœtus and the generative organs of a female who had been the subject of extra-uterine fœtation, affecting the left Fallopian tube. The patient was thirty-two years of age, and had been pregnant five times previously; had four healthy living children, and had suffered one miscarriage. Dr. Davis first saw the patient on the 23rd of June, in company with her medical attendant. She believed herself to be between four or five months pregnant; the menses had been absent for five months. After a close investigation, Dr. Davis found all certain signs of pregnancy absent: the entire hypogastrium was free from any enlargement perceptible to the taxis; the breasts contained no milk, and were flaccid. Examination per vaginam discovered the uterus small, mobile, and light upon the finger; through the walls of the vagina no enlargement could be detected.

About ten days before the above visit, the patient had been

Digitized by Google

suffering from jaundice, diarrhœa, and vomiting, which had yielded to suitable treatment. During the vomiting a red discharge and a clot of blood had escaped from the vagina, with slight pain. A miscarriage was feared, but did not occur, and the patient regained her health and spirits. Dr. Davis did not see her again till the 26th of July, when he was hastily summoned at the request of her medical attendant. Vomiting of offensive, feculent-smelling matters; spasmodic pains of the abdomen, attended with tympanitic resonance, but with no great tenderness; obstinate constipation, great anxiety of countenance, and serious constitutional disturbance, were the distinguishing features which presented themselves, No enlargement of the uterus was perceptible externally, nor by vaginal examination. In the right iliac fossa a circumscribed tumor was now felt, perfectly immovable and slightly tender; the breasts were flaccid. On making a vaginal examination, the os uteri was discovered sufficiently open to admit the tip of the forefinger, but nothing was found presenting, and there was no discharge from the uterus, nor had there been any since the 23rd of June. The evidence of a distinctly circumscribed enlargement in the right iliac fossa, not present in June, induced Dr. Davis to form the opinion, in which he was joined by his friend, Mr. Wilkinson,* the surgeon in attendance, that the patient was the subject an extra-uterine fœtation, ovarian or tubarian, an opinion which was arrived at, on a consideration of the absence of any other apparent cause for the swelling, of the patient's reiterated conviction that she had the feelings similar to those experienced by her in former pregnancies, with some strange additional sensations, which she could not explain, and which had made her apprehensive of the result. The bowels were relieved by repeated enemata, which gave the patient great relief. Medicines were given to allay the vomiting, but with only partial success. After a few days it was found necessary to administer narcotics freely, in order to relieve suffering, and to procure sleep.

* Mr. W. H. B. Wilkinson, of the Caledonian Road, with whom there was also present at the post-mortem examination, with Dr. Davis, Mr J. C. Cornelius.

Digitized by Google

The sufferings of the patient heightened daily in severity. She died at 3 A.M. on the 3rd of August, remaining perfectly conscious to the last. At the examination of the body, no blood was seen to be extravasated into the peritoneal sac, nor were evidences of general peritonitis discoverable. The intestinal tube along the course of the small intestines was highly congested and distended with gas. The enlargement which had been perceived during life was adherent to the right iliac fossa, and to the peritoneum at the right internal abdominal ring, and was formed by the left Fallopian tube, which had been displaced from its natural position on the left side of the pelvis. The portion of the tube containing the fœtus was situated nearly midway between its uterine and ovarian extremities—being, perhaps, rather nearer to its uterine end. The left ovary was healthy, and exhibited on section the cavities of several Graafian vesicles, and a "true corpus luteum;" the uterus and right ovary were also healthy. When the dilated Fallopian tube was dissected away from its attachments, which consisted of bands of false membrane adherent to the circumference of the tumor, and the mass thrown forwards and inwards, the fœtus, hitherto concealed, was brought into view, closely invested by the amnion and chorion, but without any inclosed liquor amnii. The head of the fœtus was in its most dependent part, and occupied a situation to the right of the vagina, opposite its attachment to the cervix uteri. The fœtus appeared to be of about four months' growth, which would agree with the calculations of the deceased. It had evidently undergone much compression, for the outline of skeleton was marked in the skin, the upper extremities were adherent to the sides of the body, and the lower to one another. The upper portion of the sac containing the fœtus was filled by the placenta and clotted blood. The tumor lay right over the cœcum, and thus an explanation of the fæcal vomiting and obstinate constipation was afforded. The dilated Fallopian tube was rent at its under surface, but the aperture must have been closed by adhesions, as no extravasation of blood had taken place. All the remaining abdominal viscera were healthy. Dr. Davis remarked, that, in all probability,

Digitized by Google

the rupture of the Fallopian tube took place at the fourth month, a few days before the visit of the 23rd of June, instead of at the second, the more usual period of rupture in tubarian pregnancies. The patient's death did not arise from any shock coincident with the rupture of the cyst, nor from hæmorrhage into the abdominal cavity, nor from peritonitis, but from intestinal obstruction and irritation, dependent on the position of the tumor, and from the suffering and exhaustion produced by the condition in which she was placed.

Dr. J. Hall Davis, 16*th of November*, 1852.

25.—*A large Ovarian Tumor.—A Uterine Polypus.*

The specimen was taken from a patient aged forty-five, married, and the mother of three children, who had died from malignant disease of the right ovary of less than two years duration, in the Hospital for Women. The tumor consisted of a very large cyst with thick walls, capable of containing upwards of thirty-five pints of fluid. At the lower part of the cyst, and apparently developed within its walls, was a solid mass somewhat larger than the fœtal head at the termination of pregnancy. To the naked eye, this mass, on being cut into, had all the appearance of medullary cancer; and on an examination of various parts of it microscopically, a large number of spherical nucleated cells in various stages of development were discovered, together with numerous caudate nucleated cells: some of the cells contained single nuclei, while in some several were found. There was also much granular matter, oil-globules, &c. The disease had been diagnosed during life as malignant; and as it was thought that the tumor had contracted adhesions with the peritoneum —which proved to be the case—no attempts were made to extirpate the mass. The left ovary was perfectly healthy, as were the remaining abdominal viscera. The thoracic viscera were also healthy.

A very *large polypus* of the uterus was also exhibited by Dr. Tanner. It measured nine inches in length, 14½ inches in circumference at its thickest part, and weighed 2½ lbs. As

Digitized by Google

far as could be ascertained from the history of the symptoms, it had existed rather more than two years.

Dr. Brinton, for Dr. Tanner, *5th of April*, 1853.

26.—*Ovarian Tumor, with Cysts, containing Fat and masses of long Hair.*

M. A. F., a married woman, aged twenty-eight, came under the care of Dr. Hare as an out-patient of University College Hospital in May, 1852, for phthisis, at which period she presented evident physical signs of a largish cavity at the apex of the left lung: she attended the hospital for a few weeks, but afterwards being unable to leave the house, except for short distances, Dr. Hare did not again see her till after her death on the 11th of April, 1853.

She dated her cough from January, 1852. In the July following, she had some hæmoptysis for three weeks, and during this period it recurred three times rather profusely—once amounting to nearly half a pint. She had no return of hæmoptysis after this, till the day of her death, when, while lying on the sofa, she was suddenly seized with an attack, and in the course of three or four minutes, brought up about three pints of blood, when she sank back and expired.

Though she made no mention while she attended the hospital of any symptoms referable to the uterus, it was afterwards ascertained that as much as seven or eight years before, the abdomen was observed to be rather large, especially at the catamenial periods, for a week before and after which she also suffered much from pain in the lower part of the body, and constantly from a sensation of weight in the same part: the catamenia remained regular till five months before her death. She was married in June, 1850; miscarried (supposed to be at second month of gestation) in January, 1851: though she miscarried, her abdomen continued larger than was habitual with her, but no further notice of the subject was taken, nor did she apply for any medical opinion on account of it.

The body was much emaciated, and there was some œdema

Digitized by Google

of both legs. Adhesion of the upper part of the right lung: in the lower and middle lobes of this lung, there were great numbers of patches of well-marked and well-defined pulmonary apoplexy, varying in size from a filbert to a large pin's head. There was some blood also in the bronchi; in the upper lobe, the spots of pulmonary apoplexy were much less abundant; while, on the other hand, the tuberculous matter was much more abundant there, as well as more advanced, than in the lower part of the lung. The left lung was universally and very strongly adherent; and it consisted chiefly of an enormous cavity (occupying two-thirds of its bulk from the apex downwards), which contained some puriform fluid mixed with blood.

On removing the intestines from the lower part of the abdomen, a tumor of a palish cream-colour was found occupying and completely filling up the pelvis, and projecting upwards so as to reach about half an inch above the level of the upper border of the symphysis pubis: it was covered and separated from the abdominal parietes by the intestines; its upper surface was a little convex, smooth, and about the size of the brim of the pelvis; it was situated between the uterus and the bladder, the former being somewhat elongated as if carried up by the growth of the tumor, by which it was also compressed; one of the Fallopian tubes was adherent to it, the other was not so; there were no adhesions between the tumor and any other part, except the Fallopian tube; the ovary was lost in the substance of the tumor, but the other ovary was of normal size.

When removed, the tumor was found to weigh nearly three pounds; it felt solid, but firm pressure left a permanent indentation on its surface; it consisted of four cysts, the walls of which were thin; their contents varied somewhat; the largest of the cysts (the size of a very large orange,) was completely full of a mass of light-coloured hair, thoroughly intermixed with a small quantity—perhaps a fourth or a fifth of its bulk—of fatty matter; the hairs varied from a line or two to eight inches in length. The other cysts were filled with a fatty matter, rather more transparent than that of the first-named cyst, and of the consistence of lard; interspersed amongst the

Digitized by Google

fat were a few hairs, but insignificant in quantity compared with the large mass filling the first cyst. No bones, teeth, or other portion of a fœtus existed.

The hairs were irregularly twisted in all directions: none of them could be satisfactorily traced as inserted into or closely connected with the cyst-walls; they were cylindrical, and about the same diameter as five human hairs; one end of each hair was, in almost every instance that was examined, found to be finely pointed; the other end, in some of the hairs, appeared to be abruptly broken off; to others there was a distinct bulbous termination; but in a few, which were very carefully examined, each end of the hair terminated in a point, and no bulb could be discovered even under a high power of the microscope. The fat consisted chiefly of margarine.

Subsequently to the exhibition of the specimen before the Society, Dr. Hare examined the effect of heat upon the fatty matter, and found that a portion of it became fluid at a temperature of about 85°, while at the temperature of the body, the whole of it assumed the consistence and somewhat the appearance of very thin gruel, so that during the life of the patient, the hair contained in the cysts must have been surrounded by a thin, oily fluid; and had an examination of the patient, per vaginam, been made, a sensation of fluctuation might probably have been communicated to the finger (unless it had come in contact with the cyst filled with hair), while the post-mortem examination would have exhibited the apparently contradictory fact of the tumor being solid.

Dr. HARE, *3rd of May*, 1853.

27.—*Fatty Matters Discharged from a Tumor situated between the Rectum and Vagina.*

Dr. Ramsbotham gave the following history of the case:—

At two o'clock A.M. of Sunday, the 21st of November, 1847, he was sent for to a patient of the Royal Maternity Charity, in labour with her first child. She had been in pain all the day before; the os uteri was high, very rigid, thick, and dilated to the size of a shilling. The pelvic cavity was almost entirely

Digitized by Google

occupied, the sacrum being filled by a tumor larger than the closed fist of a man, which did not leave more than an inch of space at any one part, and rendered it very difficult to reach the os uteri; there was no perceptible fluctuation in it. Great care was taken to preserve the fœtal membranes entire. They broke at eleven o'clock on Monday night. The pains, which previously had not been strong, and recurring only every half-hour, were now rather increased both in power and frequency; still the os uteri was indisposed to dilate. She was not in a condition to bear bleeding; but nauseating doses of antimony were given without any apparent good effect. Through Tuesday the uterus was very inactive; and on Wednesday at seven A.M., the tumor was punctured by a long trocar through the vagina; a large tea-cup-full of thick, yellowish matter, exactly in appearance like thick custard, was collected, and probably as much more was lost. It became solid when cool, and analysis proved it to be chiefly composed of fat-globules. As shown in tubes, this substance had the consistence and appearance of butter.

At the time the puncture was made, the tumor gave to the finger the impression of its being perfectly solid. After the evacuation of the cyst, it almost entirely disappeared; and could scarcely be felt either by the rectum or vagina. At four P.M. on the same day, the pains having been very strong since the operation, the pulse having risen to 140, and other symptoms of commencing exhaustion having shown themselves, there being also unequivocal evidence of the child's death, though the os uteri was not more dilated than the size of a crown-piece, Dr. Ramsbotham perforated the skull, and after much exertion, owing to the condition of the os uteri, delivered the patient. She progressed very satisfactorily for nine days, but on the night of the 3rd of December, was seized suddenly with violent abdominal spasms. These were relieved by opium, but the abdomen swelled and became tympanitic; vomiting of everything swallowed supervened. No cause could be assigned for these symptoms, which continued a week, when they disappeared as suddenly as they had come on. She gradually recovered; and a month after delivery might be said to be

Digitized by Google

convalescent. The abdomen was then quite flat; the os uteri quite healthy; and not the least vestige of the tumor could be felt either by the rectum or vagina. In a few months, however, she was received into the London Hospital, under Dr. Ramsbotham, in consequence of a circumscribed tumor in the lower part of the abdomen on the right side, which was regarded as ovarian. This tumor has remained stationary till this date, and when she was examined, per vaginam, a year ago, there was not the least enlargement of a morbid kind to be detected in the pelvis, and the uterus was in its natural position.

From this case, as well as others on record, Dr. Ramsbotham urged the necessity of puncturing every tumor not absolutely osseous (except in cases of the polypus kind, which should be removed) that impeded the passage of the child in labour; however unpromising such a proceeding might *a priori* appear. In two cases given by Ingleby, a quantity of gelatinous fluid was taken away, although the tumors bore the character of perfect solidity.

The kind of fluid evacuated in this case was unusual; and Dr. Ramsbotham stated that he only knew of one case on record where the fluid removed by a trocar from a tumor that impeded parturition, was of the same character; that case is given by Mr. Kirch in the "Lancet" for the 30th of March, 1838. Eight ounces of fluid "like honey in appearance," were let off, but as it became solid in five minutes, it was evidently fatty.

It is well known that fat and teeth and hair often form parts of the contents of an ovarian cyst, but he believed it was very rare to find one entirely filled with fatty matter.

Dr. RAMSBOTHAM, *2nd of November*, 1852.

28.—*Specimen of Degenerated Placenta.*

Mrs. H., aged thirty-five, was delivered at eight and a half months of a small fœtus, which had died apparently about five months after conception. There was less hæmorrhage than usual, and the uterus contracted readily and firmly immediately after-

Digitized by Google

Digitized by Google

DESCRIPTION OF PLATE VIII.

FIGS. 1, 2, 3, illustrate Dr. Lionel Beale's specimen of the contents of a cyst in the kidney. Page 193.

Fig. 1 shows a portion of the lining membrane of the cyst.

Fig. 2 shows what is probably a portion of a uriniferous tube.

Fig. 3 indicates numerous free oil-globules and plates of cholesterine, which were also present in the fluid contents of the cyst.

FIG. 4 illustrates Dr. Quain's specimen of quasi-organized fibrin discharged by the urethra. Page 205.

FIGS. 5 and 6 illustrate Dr. Handfield Jones' case of degeneration of the placenta. Page 238.

Figs. 5, 6, 7. Three villi, from fœtal portion of placenta, containing oily and calcareous matter: 7 is simply atrophied, and contains none.

Fig. 8. Atrophied cell-growth.

Fig. 9. A villus, with an investment of atrophied nuclei.

Fig. 10. A villus, full of calcareous matter.

Fig. 11. Maternal portion of placenta, infiltrated with fibrine.

Fig. 12. The same, treated with acetic acid.

Digitized by Google

Fig. 2.



Fig. 1.

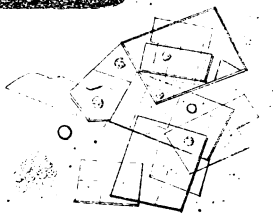

Fig. 3.

D'L. Lionel Beale del

Fig. 4

X 150 dia.'

Tuffen West del

Fig. 5.



Fig. 7.

Fig. 6.

Fig. 8.

Fig. 9.

Fig. 10.

Fig. 12.

Fig. 11.

D' Handfield Jones del Tuffen West sculp.

Digitized by Google

Ford & West imp. 54, Hatton Garden.

Digitized by Google

wards. She is a person of feeble anæmic constitution, and was confined under similar circumstances thirteen months ago. From her condition on this occasion she suspected this child would not be born alive. She felt the usual sensations of pregnancy till between the fourth and fifth month, when she quickened, and the motions of the child gradually diminished after that time; the breasts which had enlarged also subsided, and she had a sensation of weight at the lower part of the abdomen. She had previously borne three healthy living children, but since then had suffered much distress in consequence of scarlet fever in her house, which proved fatal to two of her children. The four menstrual periods intervening between the birth of the first and the conception of the second fœtus were perfectly natural and regular.

The free surface of the placenta presented nothing remarkable; the attached uterine surface was of a mottled reddish colour, with prominent portions of various size here and there; these were whiter than the surrounding tissue, tolerably well circumscribed, less tough than the intervening general stratum, which cuts very firm. The thickness of the general stratum was about one-sixth of an inch, of the patches one-third. A vertical section shows a superficial layer of semi-translucent vellum-like aspect, with a kind of loose reticular tissue adherent to it below. The upper thin layer consisted of a dense, tough material, which appeared under the microscope as a fibro-homogenous expanse, exhibiting here and there traces of cell-formation, and imbedding in its deeper surface remains of the villi of the fœtal portion and of their investing cell-layer. Acetic acid rendered the fibro-homogenous substance more transparent, and brought into view numerous elongated nuclei. The reticular tissue before mentioned was composed of slightly branched villi, which were in various stages of atrophy and degeneration, but were very distinct. Some were simply of pale granulous texture, and showed no investing cell-layer and no capillaries in their interior; others contained much oily matter; others again oily and oleo-calcareous matter, as proved by the effervescence which took place on adding an acid. Some of the villi were converted into opaque masses of oleo-

Digitized by Google

calcareous matter. The thicker patches contained a greater quantity of fœtal structure which was loaded with oily matter, and had much also dispersed in the interstices of its villi. There was no trace of the uterine sinuses. (Plate VIII.)

It is very clear that the disease of the placenta in this instance primarily affected the maternal portion, and that the fœtal was only in a state of consequent atrophy or degeneration. The maternal portion was reduced to a bloodless, dense layer of solidified fibrine. What now was the nature of the process by which this change was effected? Rokitansky speaks of inflammation of the placenta giving rise to a plastic fibrinous deposit, which at first is reddish, but in the course of time assumes a pale red, greyish or yellowish red, or even yellowish-white tinge; at the same time it becomes firmer, and together with the included obliterated tissue, contracts and shrivels. The inflammation has thus terminated as it usually does, in induration and obliteration of the placental tissue, which is converted into an elastic, tough, leathery callus, resembling elastic tissue. According to this great pathologist we should therefore consider the specimen above described as the result of inflammation; but it seems to us more probable that the fibrinous effusion which took place in the maternal portion and so considerably altered it, was not the product of any hyperæmic condition, but was solely dependent on an unhealthy crasis of the blood. This fluid we know is apt, in certain low cachetic conditions of the system, to contain an excess of fibrine, which has also an unnatural tendency to coagulate, so that it sometimes in this way blocks up arteries or veins, without any inflammation of the coats of the vessels having taken place. It is the more probable that the process in this case was similar; that fibrine was simply deposited in the uterine sinuses where they enter the placenta, because there does not seem to have been any trace of inflammatory action observed at any time during the course of the pregnancy, and it is scarcely to be supposed that inflammation of such a structure as the placenta should take place without some constitutional symptoms. We should class this degeneration of the placenta with many instances of cirrhosis of the liver,

Digitized by Google

thickening and contraction of the mitral valve, white pericardial patches, and chronic thickening of serous membrane. These we believe are intimately connected with an unhealthy condition of the fibrinous element of the blood, which seems to have an abnormal tendency to be effused and to pass into the form of imperfect fibrous texture. The condition of the fœtal portion of the placenta is of some interest with respect to the subject of fatty degeneration. It is clear that it was only affected by a process of atrophy, its function being put an end to, and its own blood-vessels being in some degree compressed. Thus atrophying, it became the seat of the deposit of oily and calcareous matter, in fact, underwent much such a change as the coats of the aorta do in atheroma. Another point of interest is the retention of the dead fœtus for so long a time, probably nearly to the full period. In a case communicated to me by Dr. Tyler Smith, where the disease of the placenta was precisely similar, this tendency to observe the normal period of gestation was still more strongly marked, as the fœtus was not thrown off till full term.

Dr. Handfield Jones, 19*th of October*, 1852.

29.—*Malformations of the Umbilical Cord.*

The specimens showed twistings and adhesions of the umbilical cord which must have occurred at a very early period of formation. The children were of the usual size, well formed, and born at the full time. One was a first child, the other the seventh; one a face presentation, the other presented naturally.

Dr. Crisp observed that he had exhibited the first specimen at the London Medical Society, twelve months since; and it was considered by Dr. Murphy and Mr. Streeter, who had paid much attention to diseases and malformations of the fœtus, to have been unique; but strange to say, the second case had occurred in the practice of the same gentleman (Mr. Skegg, of St. Martin's Lane), rendering it more than probable that these abnormal conditions of the cord had generally escaped observation. The circuitous course which the blood must

Digitized by Google

have taken in these children did not appear to have interfered with their growth. The specimens when seen together were of greater interest. Dr. Crisp, *5th of April*, 1853.

VI.—DISEASES OF THE OSSEOUS SYSTEM.

1.—*Chronic Hip-joint Disease, in which the Head of the Femur was dislocated and separated from the Shaft.*

The patient was an emaciated boy, twelve years of age, of whose case no history could be obtained. The skin over the great trochanter was ulcerated, and the bone exposed; several other ulcerated openings existed about the hip-joint. A very extensive abscess occupied the front of the upper fourth of the thigh, extending nearly over the whole dorsum of the ileum and into the acetabulum; it was continuous beneath Poupart's ligament with another which occupied the whole venter, and a considerable portion of the cavity of the true pelvis. The thigh was flexed on the abdomen, and what appeared to be the head of the bone lay in the acetabulum; the two surfaces were rounded, accurately moulded to one another, and quite denuded of cartilage. It was soon perceived, however, that the real head of the bone was situated in a cavity formed by condensed cellular and muscular tissue above and between the acetabulum and great sciatic notch; it was a hemisphere of hard bone, without a trace of cartilage adherent to it; the convex surface was smooth; the flat one more or less irregular, from alternate elevations and depressions; this surface had no correspondence in shape with the extremity of the shaft. The anterior fifth of the acetabulum was healthy, and covered with cartilage; the remainder, however, was denuded and expanded, especially behind or at that part into which the extremity of the femur fitted. The surface of the dorsum immediately above the acetabulum was covered with lymph, and softened; but in the remainder of its extent it was covered by muscles, which themselves formed the walls of the abscess. The cartilaginous epiphysis of the crest of the ileum was perfectly bare

Digitized by Google

in the abscess occupying the venter, and a large portion of this part of the ileum was exposed and softened, or more or less covered by adherent lymph. The chief point of interest in this case was the separation between the head and the shaft of the femur. It was clearly a case in which dislocation from disease had occurred some time prior to death; the same causes that had induced ulceration and destruction of the articular cartilages had caused destruction of that between the shaft of the femur and the not yet completely ossified epiphysis of the head, and, as a natural consequence, separation had taken place; the head retaining the position into which it had been dislocated, the extremity of the shaft falling back again into the acetabulum. And that this was not of very recent occurrence, is manifest from the fact, that the extremity of the shaft was not at all adapted in form to the epiphysis, from which it had been dislocated, but that it accurately fitted the somewhat altered acetabulum, which it was found to occupy, the two having become adapted to one another by mutual attrition.

Dr. Bristowe, *7th of December*, 1852.

2.—*Disease of the Ungual Phalanx of the Great Toe.*

The patient, a healthy looking young man, aged twenty-six, was admitted into the Royal Free Hospital for a diseased toe. The whole toe, but especially the terminal phalanx, was enlarged; the skin tense and inflamed, and the seat of the nail was occupied by a ragged, unhealthy looking ulcer, without any indication of healing, except the production here and there on its surface, and in the situation of the root of the nail, of some whitish substance,—evidently imperfectly developed nail-tissue. Eighteen months before applying at the hospital, the lad met with a severe bruise of the toe; a sharp attack of inflammation followed, and the nail separated; subsequently those processes of thickening and ulceration commenced, which led to the present condition of the toe, in defiance of all the remedies that have been employed, in order to arrest their progress. The pain of the whole toe having been very severe, and its

Digitized by Google

general appearance so unfavourable, Mr. Gay readily complied with the patient's request to amputate the disease.

The bone was cut through vertically for examination, and found to be generally enlarged by expansion of its structure, and not by any deposit of new matter in its substance. It was also uniformly more vascular than in a healthy state. The periosteum was inflamed and thickened. At the extremity of the phalanx the membrane was exceedingly dense, and contained a portion of bony matter, equal in size to that of a large pea. This osseous deposit had evidently taken place in the periosteal tissue, and had increased at the expense of that tissue, until a very thin layer alone remained to separate it from the tip of the phalanx. Mr. Gay brought forward the specimen, as he deemed it an excellent illustration of the mode by which exostoses are sometimes produced, in conformity with the views laid down by Mr. W. Adams, in the third volume of the Society's "Transactions," especially that form of the affection which is frequently met with in connection with the last phalanx of the toe; not doubting but that ultimately this isolated position of bone would have been consolidated with that of the phalanx itself. The only difference between Mr. Adams' cases and the one now presented is, that in the former the deposit appears uniformly to take place in *cartilage*, whilst in this the *fibrous* tissue is the matrix. The conclusion that both warrant, in opposition to the views of Rokitansky, is the same, namely, that the new bone-formation may take place independently of that with which it subsequently becomes consolidated.

The basement tissue of the ulcer was examined and found to consist of nucleated cells and epithelium; whilst the supposed nail-tissue was observed to consist entirely of areolar or fibrous tissue. Mr. Gay, 21*st of December*, 1852.

3.—*Disease of the Hip Joint.*

The specimen was taken from a man thirty-five years of age, who had suffered for more than fifteen years from disease of this oint. The patient could only lie on his left side, with the right

Digitized by Google

leg supported on the left thigh. The head of the femur was evidently on the dorsum of the ileum, the integuments were ulcerated over the great trochanter, which was exposed on its external surface; the discharge was very copious, and the patient died from exhaustion.

On examination, the limb was found generally atrophied, the femur not being larger than that of a child of ten years of age, excepting at the condyles, which were tolerably developed. At the junction of the inferior with the two superior thirds, the thigh bone presented a most remarkable curve, the concavity of which looks forwards and a little inwards. On the level with this curve the bony structure is the same as that above and below, only at its internal part may be observed the remains of the large vascular foramen almost obliterated. The neck is nearly in the direction of the shaft, and forms with it but a slight angle; it is reduced to one-fourth its natural length, especially in front. Properly speaking, the head does not exist, the neck being mounted superiorly and in front by a few bony prominences, presenting all the character of caries. Some detached bony fragments were found on opening the joint, and one of them was as large as a hazel-nut. Around the base of the neck were attached several fibrous filaments, constituting an incomplete capsule, which was attached above to the ileum. The great trochanter, flattened, deformed, and reduced to a simple layer of bone, sharp at its superior edge, is carious on its external surface, which was exposed during life. The lesser trochanter is natural, excepting as regards its size. The os innominatum is strangely bent at the junction of the ileum with the ischium and pubes, and to such a degree, that the anterior edge of the ileum forms a right angle with the horizontal branch of the pubes. The os innominatum is atrophied in its whole extent, especially the pubes and ischium, but less in proportion than the femur. The acetabulum is greatly deformed, its edges being flattened, so that there is only a slight concavity left. Towards its posterior and superior extremity, the rim of the acetabulum is completely destroyed, and in its place a small, wide, flattened bony surface, which probably corresponded with a part of the head of the femur before it was

Digitized by Google

destroyed. Above this bony surface there is a considerable thick fibrous mass inserted in the lower part of the external iliac fossa. This fibrous mass forms a covering concave below, and in this concavity are lodged the neck of the femur and the remaining portion of the head, so that there is a complete luxation on the external iliac fossa. The head of the femur does not immediately touch the bony surface of the external iliac fossa, from which it is separated by a part of the fibrous mass just mentioned. The glutæi muscles had completely disappeared in the midst of a thin, cellulo-fatty mass. Mr. Coulson observed that, if the joint had been opened during life, and the sequestra taken away, a great source of irritation would have been removed, and life prolonged.

Mr. COULSON, *4th of January*, 1853.

4.—*Arthritic Enlargement of the Head of the Thigh Bone and Patella.*

Mr. Solly said, on presenting these specimens, that the Society would remember that Mr. Wm. Adams had obtained and brought forward proof that this disease "did not result from an inflammatory expansion of the osseous tissue, as stated by Rokitansky and other pathologists, but was produced by a growth of new bone external to the old." Section of the caput femoris showed this very distinctly.

He also exhibited a specimen of the same disease from the patella of another patient. Mr. Solly stated his belief that the disease was a form of fatty degeneration. In both these instances the patients had fatty degeneration of the heart. He added that he had other cases in private practice which he feared were attended with the same visceral disease.

Mr. SOLLY, *1st of February*, 1853.

5.—*Encephaloid Disease of the Femur.*

F. B., aged thirty, a labourer, after suffering for some time from gradually increasing weakness of the knee, fell down and

Digitized by Google

was taken to the Egham workhouse, eight months ago, with supposed fracture of the lower end of the femur. The limb was placed in splints, and immediately began to swell, but without pain, and after the patient had remained in the hospital for some months he left it in a condition not much better than when he entered it. He remained at home until three months back, when the increased size of the joint and occasional pain incapacitated him, and he entered Middlesex Hospital on the 15th of March, 1853.

On examination, the left knee-joint was found to be enlarged in every direction to half as much again as is the natural size. To some extent the joint still retained its usual outline, and in fact looked as if it was surrounded under the skin with a quantity of soft, doughy substance, which was heaped together more in one point than in another. The swelling was most conspicuous in the inner side, where it projected in the form of a tumor which reached as high as the external boundary of the patella, and here the surface was firm and crackling, as though the swelling were enveloped in parchment or a layer of elastic cartilage; but the rest of the tumor was of a soft and doughy consistence.

It is an interesting circumstance, that marked circumscribed pulsation was discovered in this part of the swelling two days before the operation, though it can be positively stated that it was not perceptible ten days previously.

In the popliteal space a considerable mass could be felt, of the same soft texture. The patella was superficial and immoveable, the lateral motion of the joint considerable, but flexion much impaired. There was very little pain, nor had the patient suffered any during the progress of the case. No disease could be detected in any other part of the body, but the femur for some distance above the joint seemed thickened. If there was any enlargement of the glands in the groin, it was of the slightest kind. The patient had a sallow, cachetic appearance, with a rapid pulse, and there was some emaciation.

Amputation was proposed, but not assented to by the patient until the 31st of March, when the limb was removed by the antero-posterior flap operation.

Digitized by Google

Immediately after its removal the limb was carefully injected with size and vermilion, and on the next day was examined in the following manner. An incision was made around the lower part of the patella, and this bone turned back upon the femur, which was not easily done on account of the intimate adhesion which existed between the femur and the lower surface of the patella, for the joint was entirely destroyed by the morbid growth within. Next the lateral ligaments were divided and the tibia separated from the femur, when it became evident that the disease was confined to the latter bone. A lateral section was now made through the condyles and shaft of the femur, and the tumor thus divided into two halves. Much of the bone was so soft as to admit of division by the scalpel.

The lower end of the femur, especially the condyloid portion, was expanded into a thin shell, closely enveloping the tumor, which lay within it just as a cocoa-nut lies within the outer gourd. There was no trace of the cancellous structure, which had been entirely absorbed, leaving behind it here and there evidences of its former existence in the shape of little bits of necrosed bone.

The left condyle was by far the most affected, and it was evident that the disease had commenced here. The structure of the tumor was of the ordinary medullary character, more vascular in some parts than in others, and contained a central patch, which was whiter and firmer than the other portions. Into various parts of the tumor spots of hæmorrhage had taken place. A further examination, which was made by Mr. Sibley the registrar of the hospital, and myself, showed that the two structures also exhibited microscopical differences. The whole mass was almost entirely made up of cellular growth; the more central portion exhibiting several varieties of the cancer cell: the majority large and granular, with a spheroidal nucleus containing a nucleolus; many others contained large granules of fat, which vary in amount, some being completely filled, and showing the usual appearances of the mulberry cell. These cells are enveloped in a species of stroma composed of large fusiform cells, resembling the cells of fibro-plastic lymph; a

Digitized by Google

few of them have both nucleus and nucleolus, and the circumferential portion of the tumor is mainly composed of this latter —the true cancer cells being few in number.

The femur, above the tumor, was thickened, and the medullary canal narrowed, whilst the periosteum showed marks of chronic inflammation; and at two opposite points of the tumor there was deposit of fresh bone. The osseous structure of the tibia exhibited that vascular and ecchymosed condition of its compact tissue which has been noticed by Mr. Stanley as present in other examples of encephaloid disease. On careful examination, this seems to depend upon enlargement of the Haversian canals and blood-vessels of the bone, and is perhaps dependent merely upon obstructed circulation, and not upon any peculiar unsoundness of the bone connected with malignant disease. At all events I have known a patient remain perfectly well after the removal of a limb in which this state of the circulation was well marked; and indeed Mr. Stanley himself mentions two instances of this. The popliteal artery was displaced by the extension of the disease into the ham.

There are several points of interest in this case to which I wish briefly to refer:—

1st. The remarkable immunity from pain during the whole course of the disease; for though this is a usual circumstance attendant upon encephaloid disease, yet it is certainly strange that the femur should bear distention to so great a degree without obvious inconvenience.

2nd. The entire absorption of the cancellous structure of the bone, which has kept pace so exactly with the increasing size of the tumor, that with the most trifling exceptions no portion of it has suffered death or become necrosed.

3rd. The sudden development of pulsation in one portion of the tumor, which evidently proceeded from the large size of the vessels supplying it, when partially compressed against the hard cartilaginous covering.

I must not omit to mention that this patient was under the care of my colleague, Mr. Moore, who amputated the limb, and has permitted me to lay the case before the Society.

Mr. Mitchell Henry, *5th of April*, 1853.

Digitized by Google

6.—*Dissection of a Dislocation of the First Phalanx of the Thumb, complicated with Fracture of the Metacarpal Bone.*

The specimen was taken from a male subject in the dissecting-room of King's College. The first phalanx of the thumb was dislocated forwards, resting on the anterior surface of the head of the metacarpal bone, and forming a false joint closely surrounded by a strong, thick, capsular ligament. The flexor brevis, adductor, abductor, and opponens-pollicis muscles were shortened and somewhat atrophied, having accommodated themselves to the altered position of the bones.

The fracture of the metacarpal bone was oblique, and had firmly united; the inferior fragment projecting slightly on the dorsal aspect, and leaving an oblique groove just above the point of junction, in which rested the extensor tendons. These had, no doubt, been instrumental in pressing forward the upper fragment, and in aiding the flexors in resisting reduction of the phalanx, which would also be rendered more difficult by the mobility of the head of the metacarpal bone. The skin over the head of the latter bone was thickened, and a small bursa was developed beneath it. The new joint had apparently been a tolerably useful one.

Mr. JOHN WOOD, *17th of May*, 1853.

7.—*Section of a Knee Joint affected with Membranous Anchylosis.*

The joint was anchylosed in a bent position. The cartilages had been completely removed, and the synovial membrane changed into a strong fibrous tissue connecting the patella to the trochlear surface of the femur, and the condyles to the tibia. The crucial ligaments and fibro-cartilages were atrophied, and scarcely distinguishable in the membranous mass. The specimen was chiefly remarkable for the presence of a piece of detached bone in the centre of the joint, which had separated from the articular surface of the tibia. It was about an inch long, half as broad and a quarter as thick, and lay transversely across the joint, so as to be nearly cut in half by

Digitized by Google

the longitudinal section. It was firmly connected above to the fibrous tissue, and separated from the tibia by a small quantity of thick pus, which was so completely covered in by the peripheral ligamentous structures as to present no external communication nor apparent swelling. All symptoms of active disease in the joint had been absent for at least a year. The limb was amputated from a woman, for a compound fracture of the ancle-joint caused by the abnormal position of the limb. The muscles were extensively affected with fatty degeneration.

Mr. JOHN WOOD, *17th of May*, 1853.

VII.—DISEASES OF THE EAR.

1.—*Case of Ulceration of the Fibrous Laminæ of the Membrana Tympani.*

R. F., aged between eighty and ninety, formerly a sailor, was, when I saw him a short time previous to his death, so deaf, that he required to be spoken to in a loud voice, close to his left ear. The right ear was in a worse state than the left, but it was not wholly useless. Upon examination of the right ear, the membrana tympani was observed to be very concave externally, and appeared as if it had fallen inwards towards the promontory: at its superior and posterior part the membrana tympani had been withdrawn from the bone to which it was formerly attached, had passed inwards towards the promontory, and had left exposed in the external meatus the portion of bone which had formerly been a part of the tympanic cavity. The membrana tympani was white like cartilage; the normal position of the malleus was indicated by a vertical white ridge, anterior and posterior to which was a depression about a line in diameter; the anterior being the deeper. In the left ear the membrana tympani was not so thick or so concave.

History of the case.—Many years previous to his death, perhaps thirty or forty, this patient fell overboard into the sea, but did not remain long in the water. This accident was followed by a discharge from each ear, accompanied by dulness of

Digitized by Google

hearing, which in the course of three or four months increased so much, that at the end of that time he became as deaf as at present: the deafness was not affected by a cold or any accidental circumstance.

Dissection.—Right ear. The dermoid layer of the membrana tympani appears to have been destroyed by ulceration; portions of the fibrous laminæ have also disappeared, and the remaining parts are very thick and white. The inner surface of the membrana tympani is adherent to the inner wall of the tympanum; the malleus has been pushed upwards and backwards, and is anchylosed to the upper wall of the tympanum. The investing membrane of the tympanum is very thick, and it occupies all the space that is not filled by the membrana tympani. The base of the stapes is not so moveable as natural. The left ear is in much the same state as the right, excepting that the membrana tympani is not so thick: the malleus is not anchylosed, and the stapes is more moveable.

Observations.—Ulceration of the fibrous lamina is not unfrequently the effect of the application of cold water to the outer surface of the organ. It seems to result from the inflammation of the dermoid layer, which speedily terminates in ulceration, not only of its own substance, but also of the fibrous lamina. In some cases the entire substance of each membrana tympani has been destroyed in the course of a few days, and this unaccompanied by pain of any importance. Another cause of ulceration of the fibrous lamina, is chronic catarrhal inflammation of the dermoid layer. Among the results of this affection may be mentioned anchylosis of the stapes, calcareous degeneration of the membrana tympani, caries of the upper wall of the meatus externus, and contraction of the canalis caroticus.

Mr. Toynbee, 21*st of December*, 1852.

Digitized by Google

2.—*Case of complete Bony Anchylosis of the Stapes to the Fenestra Ovalis.*

J. S., aged seventy-seven, formerly a sailor in the Royal Navy. The history of his case was as follows: Thirty years ago he was engaged in an action, during which the noise from the cannonading was so tremendously loud, that he became quite deaf in both ears, and he remained so during six weeks; at the end of that period the power of hearing in a great measure returned, but not completely. He remained dull of hearing for some time, and he then gradually became so deaf as require to be shouted to; and in this condition he has remained during the last eight or ten years. Upon examination it was observed, that he could hear only when shouted to close to the right ear, the left ear being wholly useless, and a shout into it when the right ear is closed, is not heard. *Right ear.*—Meatus dry; membrana tympani opaque; Eustachian tube pervious. *Left ear.*—Meatus dry; membrana tympani white and more concave externally than natural.

Post-mortem examination.—The external meatus contained no cerumen: it was dry, and the ceruminous glands atrophied. Membrana tympani opaque, especially in parts, and having a mottled appearance; the handle of the malleus was more fixed than natural, so that when pressed upon by a probe, it moved but very slightly, and offered a firm resistance. The mucous membrane of the tympanum was not much thicker than natural, but there were delicate bands of membrane between the ossicles; the chain of bones was nearly fixed, and the stapes did not move in the least when pressed upon. The cochlea appeared healthy: the vestibule and its contents did not deviate from the normal state excepting at that part of its wall to which the base of the stapes was attached. Upon careful inspection the circumference of the flat base of the stapes was observed to be of an ivory whiteness, which extended to the adjacent wall of the vestibule for a quarter of a line around the base of the stapes; this ivory whiteness depended upon the presence of bony matter which firmly connected the stapes to the wall of the vestibule, and completely obliterated all indi-

Digitized by Google

cation of the space between them. The membrane of the fenestra rotunda was thicker and more opaque than natural.

Left ear.—The external meatus contained no cerumen, and was like the right ear. Membrana tympani opaque at parts; the long process of the malleus was almost immoveable; and the chain of ossicles was nearly a fixture. The tensor tympani muscle was much atrophied. The stapes was immoveably fixed to the margin of the fenestra ovalis. Upon opening the cochlea, the membrana fenestræ rotundæ was observed to be thicker than natural, and the surfaces of the lamina spiralis had not the regular appearance usually present. Upon examining the lamina by the aid of the microscope, the nerve-tubes did not present their usual number, regularity, or distinctness; and in place of some of them were seen numerous oil-globules. The membranous labyrinth appeared atrophied in parts, and thick in others, and the opening of the semicircular canal was filled by otoconi. At the outer wall of the vestibule, in the position usually occupied by the base of the stapes, was seen a mass of white bone a line and a half in diameter, which wholly buried the base of the stapes, connecting it firmly to the surrounding bone, and slightly projecting into the cavity of the vestibule. Mr. TOYNBEE, *4th of January*, 1853.

3.—*A Case of Perforate Membrana Tympani, treated by the substitution of an Artificial Membrane.*

Having, during the course of the past year, performed certain experiments and dissections which led me to the conclusion that the guttural orifice of the Eustachian tube was closed, except during the act of deglutition, I was subsequently induced to infer, that for the function of hearing to be perfectly performed, it is requisite that the tympanum should be a closed cavity. The opinion generally entertained is, that the constantly open state of the guttural portion of the tube allows of the displacement of air; which displacement, according to the advocates of this opinion, is requisite for the propagation of an impulse. Now it is well known, that no displacement of air is requisite for the propagation of the sonorous undulations across the tympanum

Digitized by Google

to the labyrinth; and, on the contrary, it appears highly desirable that these undulations should be confined to the tympanum, the walls of which are so admirably adapted to the production of resonance, and that they should not be allowed to be expended in the cavity of the fauces, there to be absorbed by its thick mucous membrane. The effect of confining these undulations to the tympanic cavity is to concentrate them upon the labyrinth. Having arrived at these conclusions, it occurred to me, that in cases of perforation of the membrana tympani, where the sonorous undulations were of course allowed to expend themselves in the cavity of the meatus, the dulness of hearing generally present might be ascribed to this cause. I accordingly determined to endeavour entirely to close the orifice in the next case of perforated membrana tympani that presented itself to me, and the result was not only satisfactory in that case, but I have since applied the artificial membrane with success in between thirty and forty cases.

The substances I have used for making the artificial membrana tympani are vulcanized india-rubber and gutta-percha, in very thin layers. Each is constructed by attaching to one surface of a small circular portion of either of these substances a fine wire, or some other material whereby the membrane can be passed down to its proper situation, and adjusted so as to cover completely the orifice in the natural organ; or, when it is wholly destroyed, to occupy its place.

The first case in which I used the artificial membrana tympani, I now bring before this Society. It is as follows.

Peter Turnbull, aged forty-three, formerly in the army, from which he was discharged on account of his deafness, was admitted under my care at St. Mary's Hospital, on the 12th of January, 1852.

His history was, that sixteen years since, without any other assignable cause than an ordinary cold, he became slowly dull of hearing; and five or six years since he perceived a discharge from each ear, which has continued to the present time. The power of hearing has so much diminished, that at present he requires speaking to loudly, close to his head.

Upon examination, an aperture, between one and two lines

Digitized by Google

in diameter, was observed in each membrana tympani, and the mucous membrane of the tympanum; the source of the discharge was more thick and red than natural. The treatment consisted in keeping up counter-irritation over each mastoid process by the use of an injection composed of three grains of acetate of zinc to an ounce of water. A slight improvement followed the use of these measures, but the power of hearing still remained so defective, that he was unable to follow any avocation. In the commencement of June, I tried the effect in the left ear of an artificial membrana tympani, composed of a very delicate layer of vulcanized india-rubber, and the good effect was at once decided. When it was placed so as completely to close the orifice, the patient made a movement of his lips, and said: "I hear as differently as possible from what I have done for years; everything sounds clear." The patient went away with the artificial membrane in his ear, hearing general conversation perfectly.

The following morning he came to my house, and said that he had accidentally moved what I had introduced into his ear, since which he had been "as dull as ever." I replaced the artificial membrane, when he again heard well; and being supplied with one which he could introduce or remove at pleasure, he has worn it during the day ever since; and he has not complained of pain or discomfort from it. When wearing the artificial membrane he hears as well as any other person; but when it is removed, he requires speaking to in a loud voice near to him.

The man was then introduced; the artificial membranes were then taken out by him, and the members of the Society had the opportunity of examining the perforate condition of the membrana tympani. When spoken to after the membrane had been removed, he could not hear unless the voice was very loud; but when the membranes was introduced (which it was by himself) he heard ordinary conversation perfectly well.

Mr. TOYNBEE, 1*st of February*, 1853.

Digitized by Google

4.—*On the mode of Dissecting the Ear for the purpose of Pathological Investigation.*

The best mode of *removing* the ears for the purpose of dissection is (the calvarium being sawn off in the usual way), to take both out together by means of two transverse vertical sections. The anterior of these sections should pass in a line a little anterior to the anterior clinoid processes and the posterior, in a line through the posterior third of each mastoid process. By means of these two sections, the trumpet-shaped extremity of each Eustachian tube, a portion of the mucous membrane of the fauces, and the whole of the remaining portion of each organ of hearing, can be taken out. The disadvantage of this procedure is, the disfigurement which is apt to take place by the falling-backwards of the face. To avoid this disadvantage, another mode of removing the ears has been more usually resorted to, and this consists in taking out each petrous bone separately, in the following manner:—The calvarium having been sawn off, an anterior section is to be made from without inwards, on each side, on the same line as in the first plan, but extending as far as, but not through, the body of the sphenoid bone; a posterior section on each side is then to be made in the same line as in the first plan, but not extending through the basilar process of the occipital bone; the apex of each petrous bone is then to be separated by chisel or saw, from the sphenoid and occipital bones; and each petrous bone, the outer ear and integuments being detached from it, is then to be drawn upwards, taking care to remove as much of the soft parts as possible. With this second plan there is a difficulty in removing the whole of the guttural portion of the Eustachian tube; with care, however, this may be effected, especially if the final sections separating the petrous bones from the occipital and sphenoid, be made to pass obliquely from above, downwards and inwards. The organ of hearing having been removed, the dissection may be conducted in the following manner:—The auditory nerve in its meatus should be first carefully examined.*

* It is desirable to remove for examination the part of the base of the brain to which the portio dura and portio mollis nerves are attached.

Digitized by Google

The external meatus is to be inspected by removing its anterior wall by means of a cutting forceps;* the state of the epidermis, the ceruminous glands and secretion, the dermis, periosteum, and bone, are to be noticed. The outer surface of the membrana tympani is then to be examined, the state of its epidermoid and dermoid laminæ, the degree of tenseness it possesses, and the amount of motion possessed by the malleus when it is gently pressed upon by means of a fine point. The next step is, to examine the guttural orifice of the Eustachian tube, to lay open the cartilaginous tube with the scissors, and then to expose the cavity of the osseous portion by means of the cutting forceps. In doing this, the tensor tympani muscle is exposed; its structure should be examined, and if it has not a healthy appearance, portions of it should be submitted to microscopic inspection. The upper wall of the tympanum is next to be removed by the forceps, in doing which, great care must be taken not to disturb or disconnect the malleus and incus, which lie immediately beneath it. When the tympanic cavity is exposed, the first thing is, to draw on the tensor tympani muscle, and to observe to what extent its traction makes tense the membrana tympani, and moves the ossicles. The incus and stapes are now to be gently pressed with a fine point, so as to ascertain their degree of fixedness; the tendon of the stapedius muscle is also to be pressed. The condition of the mucous membrane of the tympanum and mastoid cells is next to be examined, and any peculiarity of the cavity, the existence of bands of adhesion, &c., &c., noted. The most delicate part of the dissection has now to be undertaken, namely, that of the internal ear. The first step consists in exposing the cavity of the cochlea and vestibule by removing with the cutting forceps a small portion of the upper bony wall of each. Before reaching the vestibule, the superior semicircular canal will be cut through and removed, and the membranous canal should be carefully drawn out of it and examined. Upon inspecting the cavities of the vestibule and cochlea, it is desirable to see that the quantity of perilymph is natural, as well as its colour and

* It is requisite to have two or three pairs of these forceps; they are made by Messrs. Ash, of Broad-street, Golden-square.

Digitized by Google

consistence; the outer surface of the membranous labyrinth having then been looked at, it should be opened so as to expose the endolymph and otoconi, and portions of the membranous labyrinth submitted to microscopic investigation. This having been effected, the remaining membranous semicircular canals are to be exposed, and the connection of the base of the stapes to the fenestra ovalis carefully examined. The last stage of the dissection consists in removing portions of the cochlea, in examining them microscopically, and in exposing from within, by following the course of the scala tympani, the membrane of the fenestra rotunda. The only organ which now remains unexamined, is the stapedius muscle; to expose it, the course of the aquæductus Fallopii, beginning at the stylo-mastoid foramen, should be followed until the base of the pyramidal eminence containing the muscle is reached.

Mr. TOYNBEE, *15th of February*, 1853.

5.—*Neuroma of the Auditory Nerve.*

The man (H. B., aged seventy-three) from whom the preparation was taken, was seen by me during his life on account of his deafness. The history of his affection was, that about twenty years previously he slowly became dull of hearing, the cause being, as he considered it, a cold. He complained that he was rendered much worse during a cold; that he then could not hear unless he was shouted to: he never complained of any noises in the ears.

Upon examination I found that he could not hear, except when spoken to in a loud voice, within two yards of him.

Right Ear.—Membrana tympani surface dull, white like cartilage at the lower part; my watch was not heard, but the crack produced by pressing two nails together was heard distinctly. Eustachian tube pervious.

Left Ear.—Meatus externus full of cerumen; this being removed, it was found that the power of hearing in this ear was not quite so good as in the right. He could, however, hear a loud voice with it, when within a yard of him, and the crack of

Digitized by Google

the nails was also distinctly heard; the membrana tympani was dull and opaque. Eustachian tube pervious.

Dissection.—Right Ear.—The fibrous laminæ of the membrana tympani were thicker than natural, especially at the lower part, where they were white like cartilage. This thickening seemed to affect the circular laminæ more than the radiate. Delicate bands of membrane connected the incus to the wall of the mastoid cells and the stapes to the promontory. The stapes was attached to the fenestra ovalis much more rigidly than natural, and upon removing a portion of the fenestra ovalis this attachment was found to consist of the capsular ligaments, which were much more thick and firm than natural. The mucous membrane covering the trumpet-shaped extremity of Eustachian tube was thicker and more vascular than natural.

The perilymph of the vestibule and the fluid of the cochlea were opaque, and of a reddish colour.

Left Ear.—Membrana tympani more opaque than natural. There was a small quantity of mucus in the tympanic cavity: the investing membrane was somewhat thicker and more vascular than natural. The stapes was so firmly fixed in the fenestra ovalis that considerable pressure was required to move it. The cochlea was healthy.

In the internal auditory meatus, besides the portio dura and portio mollis nerves, both of which were in a healthy state, there was a tumor about the size of a small pea. (Plate IX. fig. 1). This tumor was of the consistence of the white matter of the brain, and it received at its posterior part a small filament from the vestibular nerve; while, from its anterior part, a small branch entered the cochlea. The tumor was composed of matter very similar to gelatine, in which nerve-tubules were observed to be distributed. Some of these tubules seemed to terminate in rounded extremities.

Mr. Toynbee, *15th of March*, 1853.

Digitized by Google

VIII.—MISCELLANEOUS SPECIMENS, TUMORS, &c.

1.—*Excessive number of White Cells in the Blood.*

Dr. Quain presented this specimen, taken from a patient in an adjoining room, and in doing so, mentioned that this appearance was one which had recently attracted considerable attention. It would be seen that under the microscope the red globules of the blood had accumulated as usual in *rouleaux*, and that throughout the rest of the field were numerous globules, considerably larger than blood-globules, and containing several granules or nucleoli. These appearances had, no doubt, been rendered familiar to the members by the work of Dr. Hughes Burnett on the subject. The history of the case was the following:—J. D. (from whom the specimen had been taken), aged thirty-seven, a butler in a gentleman's family, extremely regular in his habits, having always lived in a healthy situation, and never had ague: indeed, with the exception of an attack of scarlet fever, when in his twenty-first year, he never ailed. His family in general has been healthy. About twelve months before he came under notice he had begun to cough—to suffer from shortness of breathing—and to be less equal to his work than previously. Within the last two or three months these symptoms have become aggravated. He observed, about the same time, his abdomen increasing in size, and his legs swelling; and subsequently small tumors formed in the axilla, at the root of the neck, and in the groin. He had never had hæmoptysis, nor loss of blood in any form. He presented himself at the Brompton Hospital at the end of last month, supposing that he was suffering from phthisis. Dr. Quain then obtained from him the detail of the preceding facts, and found that the symptoms of which he had complained were becoming daily aggravated. He looked pale, and rather sallow. He had not lost much flesh; he suffered much from the shortness of breathing, and debility; he could lie in any position, and had no difficulty in swallowing. The abdomen was found enlarged by the presence of a certain amount of fluid in the peritoneum, by a large solid tumor in the situation of the

Digitized by Google

spleen, and by some addition to the size of the liver. The legs were œdematous. The heart's action was excited, and accompanied by a loud, though soft murmur, accompanying the first sound, and audible at the base. There was no disease of the lungs, save bronchitis. In the axilla, the groin, and at the base of the neck, were a number of small nodules of a reddish hue, raised above the skin, and evidently formed by enlargement of the lymphatic glands. He voided about two pints of urine daily, which presented a dirty, turbid aspect, and was loaded with lithates, but was free from albumen. His fæces were dark coloured. Some alkaline diuretics were prescribed, in combination with juniper. Under this treatment the urine has become clear and more abundant; the œdema of the feet and legs is less; but in other respects he continues much as before.

Dr. Quain added that the interest belonging to this class of cases induced him to mention another, which had recently fallen under his notice, in which there existed a diseased condition of all the blood-globules. E. F., forty-three years of age, a female, the wife of a publican, having borne eleven children, presented herself at the hospital on the 16th of September. She had lived for many years in a healthy situation, was temperate, and enjoyed good health, save that when, being eighteen years of age, living in Bedfordshire, "on a sandy, dry soil," she had an attack of ague. She had never suffered from loss of blood, and was very well until the preceding March, when she suffered from pain and swelling in the abdomen, which in a week laid her up, and she has never since been well. Her menstrual functions ceased, and she lost her flesh and strength. The spleen was found to be much enlarged; and the blood, examined by the microscope, showed that all the red globules were more or less altered in structure, presenting an irregular granular character. The contrast was very remarkable when a drop of healthy blood was placed on the glass at the same time. This patient was seen but once. It was ascertained that she died soon after this visit in a state of extreme exhaustion.

Subsequent history of the first case.—This patient began, a few days subsequently to the date of the preceding report, to complain of increased debility and difficulty of breath-

Digitized by Google

ing. The swelling of the legs became distressing, and the œdema, extending to the scrotum and penis, caused him much inconvenience. The distress was somewhat diminished by punctures made in these parts, and by spontaneous superficial openings which formed in the legs. From both an abundant watery discharge proceeded. His debility, however, increased, and he died exhausted on the 8th of December.

The *post-mortem examination* was made after an unavoidable delay of forty-eight hours; decomposition (the weather being mild) had progressed rather rapidly. There was considerable œdema of the lower section of the body, and livid discoloration of the back part. The upper extremities and chest were pale and thin; lymphatic glands, some as large as half a walnut, were seen in the groins and axilla. There existed scarcely any rigidity. The head was not examined. On opening the chest the lungs collapsed but little. Each pleural cavity contained about 8 ounces of dirty-brownish serosity. There were pretty extensive adhesions of both pleura, chiefly posteriorly, and of the left lung to the greater extent. Puckerings existed at the summits of both lungs. Much frothy bloody fluid escaped from each on section. The pericardium contained about four ounces of fluid, similar to that found in the pleura. The heart itself appeared as a pale, soft, flabby mass. Its cavities were quite empty; very little blood could be obtained from any of the larger vessels. The valves of the heart were tolerably healthy. The muscular fibres had, under the microscope, a confused, granular aspect. They were probably in a state of fatty degeneration, but the decomposition which had taken place renders this point doubtful. The blood presented appearances similar to those described as having been present during life.

In the peritoneal cavity there were about twenty ounces of dirty-yellowish serum. *The liver*, which was found to weigh six pounds, was paler than natural, but felt firm and solid. The increase in size seemed (when investigated by the microscope) to be due to hypertrophy of all the elements of which the organ is composed, rather than to a special increase in one. The

Digitized by Google

gall-bladder contained about three drachms of thin, dark-coloured bile.

The *stomach* and *intestines* were much distended by flatus, but otherwise presented nothing abnormal.

The *spleen* measured 13 inches in length by 11 in width, and weighed five pounds. It felt exceedingly solid and firm, and was of a dark red colour. The microscopic examination, which was not made till further decomposition had taken place, was not, therefore, satisfactory; abundance of cells, similar to the white cells of the blood, caudate fibres, and cells aggregated as if in capsules, were observed.

The *kidneys* were large, soft, and rather rough on removing the capsules.

The *mesenteric glands* were enlarged, so were the lumbar lymphatic glands. On removing one of each class of glands, they communicated to the touch a soft, elastic feel, as of a cyst filled with fluid. On section this was found to depend on the presence of an abundance of fluid of a creamy consistence, and a beautiful pink colour, the latter more marked in the lymphatic gland, infiltrated through the meshes of the glandular texture. The fluid was seen under the microscope to contain an immense number of cells; these cells, which were nearly all spherical, varied infinitely in size; the majority being about the size of the white globules of the blood: a few were larger, and many smaller; all contained nucleoli and granules. There was no very apparent difference between the contents of the mesenteric and lymphatic glands. Dr. QUAIN, 16*th of November*, 1853.

2.—*Large Phlebolithes from a Horse.*

Three large phlebolithes, taken from the external jugular vein of a horse, which had prevented the blood from entering the vein, and therefore caused a contraction of the vessel, were presented by Mr. Simonds. There was also diseased condition of the liver in the same animal. The specimen was accompanied by coloured drawings of the morbid parts.

Mr. SIMONDS, 18*th of January*, 1853.

Digitized by Google

3.—*Cysto-Sarcoma of the Mamma.*

This specimen of "cysto-sarcoma" of the breast had been recently removed by Mr. Shaw from an unmarried woman, aged fifty-four, admitted into the Middlesex Hospital on the 12th of July. She was of healthy constitution, and not aware of any hereditary predisposition to cancer. She first observed the tumor twenty years ago, as a small movable lump at the axillary edge of the left mamma. Eight years ago, when the catamenia ceased, it began to enlarge; but until lately had never given her pain, except after a hard day's work as a charwoman. About ten days previously, it became inflamed at its lower part, pointed, the skin broke, and some thin matter escaped. Shortly afterwards another swelling formed in an adjoining part, with a similar bursting of the skin and discharge of matter; and the openings soon expanded into large circular sores. These sores occupied the inferior part of the tumor, which was as large as a child's head at birth, and of greatest size at its lower part. The surface of the sores was ragged, divided by fissures, of a spongy, glazed appearance: it secreted a watery fluid inoffensive to the smell, and protruded considerably beyond the level of the skin, the edges of which were even and sound, and partially overlapped. The glandular structure of the mamma had given place to irregular lobulated masses of firm, elastic substance, with two or three globular swellings visible on the surface, which felt like cysts distended with fluid. The skin was everywhere movable over the tumor, which itself was movable on the chest. The nipple was flattened, not retracted. Numerous large tortuous veins were visible upon and around the tumor.

26th of November.—The patient had been repeatedly advised to have the breast removed, but would not consent to an operation till this day, when it was performed. The tumor had increased about one-sixth in size. Patches of new but imperfect skin had formed on the face of the sores, which appeared to be fungous growths developed from the bottom of ruptured cysts. Three or more of the globular swellings seen on the surface had at different times become inflamed, then burst, and discharged a brownish thin fluid, and afterwards shrunk.

Examination of the Breast after the operation.—Scarcely any of

Digitized by Google

the glandular structure of the mamma could be discerned. The tumor consisted chiefly of four or five principal masses of irregularly-shaped fibrous substance of different sizes, closely held together by the remains of the gland-structure; and connected with these were several cysts, some of which contained fluid of various appearance and amount. When sections of the lobular masses were made, the cut surface was of a light pink and greyish colour; and, from the substance being divided into small lobules, it was uneven, though apparently homogeneous, glistening in the light. Each of the masses affected, more or less, the globular form; and around them could be traced concentric layers of dense fibrous membrane, closely adhering to them, but yet recognizable as the remains of the walls of cysts, in which it was presumed the solid growths had originally been developed. Some of the masses were invested all round with these adherent capsules; but, in others, part of the growth protruded into distinct cysts, containing thin fluid of a reddish-brown colour. At these parts, the lobes were vascular to some depth; their surface had a warty or cauliflower-like appearance, resembling a mulberry in colour and roughness; the pedicles of the warty excrescences were commonly broad and flat, but a few were thin, so that the small tumors were pendulous. The fungous substance of the ulcers was divided into irregular lobules, presenting in some parts, from the parallel or concentric arrangement of the fissures, a foliated appearance. Owing to the different directions of growth of the various lobes of the tumor, and to their mutually encroaching on each other, the shape of the cysts was irregular. The intra-cystic tumors were submitted to a careful microscopic examination, with the object of ascertaining whether any traces of the mammary glandular structure could be discovered in them: minute thin sections showed them to be composed almost entirely of nucleated cells, with granules distributed among the tissue: the cells resembled those of healthy mammary structure, and there were numerous compound granular bodies, consisting of aggregated fat-globules, besides fatty granules, irregularly interspersed; but in no part could tubes or their cœcal terminations be distinguished. Mr. SHAW, *17th of December*, 1852.

Digitized by Google

4.—*Lobular Hypertrophy and Scirrhus in the same Breast.*

In this specimen lobular hypertrophy or "chronic mammary tumor" co-existed with ordinary scirrhus.

The former condition existed at the axillary margin of the gland; the latter at its centre; and their distinctive marks could be recognized before the operation.

The central lump (which lay under a retracted nipple, and was of stony hardness) measured $1\frac{1}{2}$ by 2 inches. On microscopical examination, it showed cell-growth uniformly infiltrated through a fibrous network. The nuclei measured from $\frac{1}{2750}$th to even $\frac{1}{1833}$th of an inch in diameter.

The axillary margin was irregular with general knottiness and pedunculated outgrowths, partially cystic. The structure of these knots was entirely glandular; their section broke into branched follicles, or endothelial casts of follicles, floating freely about in the field of the microscope. The nuclei measured from $\frac{1}{3666}$th to $\frac{1}{2750}$th of an inch in diameter.

Mr. Simon referred to other cases which had fallen under his notice, illustrating an intimate connexion between scirrhus and this other alteration supposed to be non-malignant; especially to a case where there had been removed from a woman's breast, at the close of suckling, a tumor which her medical attendant called a lacteal concretion; subsequently, along the axillary margin of the breast, there occurred a disease (for which Mr. Simon removed the outer half of the gland), which, to the touch, to the naked eye, and to the microscope, presented the characters of lobular hypertrophy; finally, she came a second time under Mr. Simon's care, about a year after this operation, and died with cancerous growths in the axilla, in the opposite breast, in the integument, and in internal organs. Mr. Simon, 18*th of January*, 1853.

Report on the preceding specimen.—The chief point of interest in the specimen of diseased breast presented to the Society by Mr. Simon, is the coexistence of scirrhus with the structural change known as lobular hypertrophy. No one who examined, even in a cursory matter, the hard, knobby tumor in the centre

Digitized by Google

of the gland, could doubt its being true scirrhus; but to make quite sure of the fact, portions of it were placed under the microscope, and found to present the well-marked characteristics of cancer, namely, compound cells among the meshes of a fibrous stroma.

The small knots which, before the operation, had been felt along the outer margin of the breast, were of a pinkish colour and firm consistence, resembling, on a superficial inspection, indurated lymphatic glands, but when cleared from the surrounding fat they proved to be outgrowths from the gland itself; the largest being about the size of a hazel-nut.

Portions of this were placed under tho microscope, and found to consist of fibrous tissue and branching follicles. The latter were larger than the secreting follicles of a healthy mammary gland, and filled with closely aggregated cells, about half the size of the cancer-cells in the scirrhous portion of the breast.

The relative quantity of the two elements varied considerably in different portions of the outgrowth. In some parts it seemed as if the hypertrophied follicles had thrust aside the fibrous tissue surrounding them; while in other parts the follicles were almost hidden by the abundant fibrous tissue in which they were imbedded.

As a more detailed account of the microscopical appearances of the specimen will be communicated by Mr. Simon himself, we have contented ourselves with the present brief notice of its structure.

Mr. Fergusson and Mr. Dixon, *1st of February*, 1853.

5.—*Morbid Growth involving the Walls of the Chest.*

The morbid parts were removed from G. C., a shoemaker, aged fifty-six, who died at Stoke Newington, while under the care of Mr. Toulmin, with symptoms of glandular disease and hydrothorax. Five weeks previous to last Michaelmas, up to which time he was in perfect health, he perceived a small tumor in the axilla; this gradually extended over the thorax, and he became an in-patient at St. Thomas's, for this affection. While in the hospital some dyspnœa supervened, which be-

Digitized by Google

came more and more severe, until two days before his death, when it left him. Mr. Denny, the apothecary of the Stoke Newington Dispensary, examined him three or four days previously to the fatal issue, and found that there was no respiratory murmur on the right side, while that of the left was puerile. At the time of his death, the whole surface of the left thorax was tumefied and red, presenting torn and nodular masses: it was throughout very dense and hard; the tumefaction and hardness extended to the shoulder, and the whole arm below the deltoid was œdematous. On cutting through the tissues of the right thorax they were found matted together, the muscular tissue of great density and in close connexion with a dense mass of whitish or roseate, heterogeneous, lardaceous texture, binding it to the ribs. The growth infiltrated much of the muscular tissue, and the pectoralis minor seemed entirely converted into it; a similar growth of the size of a fist was found under the sternum, at the ziphoid cartilage; and from the middle of the sternum to the commencement of the brachea, and mounting up to the right clavicle, was a large mass, of the heterologous formation, communicating, through the third intercostal space, with the external growth. The right pleura was found filled with serum, so as to compress the corresponding lung to the size of a fist. No marked disease was discovered in any of the thoracic or abdominal organs; and especially was there no trace of a similar deposit found elsewhere. All the abdominal organs were enlarged, but neither in the liver, spleen, kidneys, or mesenteric glands was any morbid growth.

A large piece from under the pectoral muscle, examined carefully, exhibited a faint, pinky-white colour, marked by lobules closely resembling those of the pancreas in size and consistency. Muscular fibres were seen shooting into and disappearing in the mass. Under the microscope it showed blood-vessels; and the muscular tissue, surrounded by the growth, partly retained its healthy appearance; but much of it, as well as that not in immediate contact with the tumor, was in a state of granular degeneration, and the fibres had entirely lost their striæ. The morbid growth was made up of oval cor-

Digitized by Google

puscles, varying in size from $\frac{1}{5}\frac{1}{0}\frac{1}{0}$th of an inch, and of fibroid elongated cells. The former were partly homogeneous, but generally studded with minute glistening (oily) spots. Acetic acid produced no alteration in the appearance of the corpuscles. The growth in the anterior mediastinum, which was firmer to the touch, presented a more entirely fibrous structure than the mass underlying the pectoral muscles. Between the fibres similar corpuscles were seen as in the latter.

Dr. SIEVEKING, *15th of February*, 1853.

6.—*Medullary Cancer of Leg.*

E. C., a healthy little girl, seven years old, was brought to my house, on the 12th of January, 1853, from Rotherhithe, where her parents resided and she was born, on account of a swelling of her left leg. Her mother stated that the outside of the child's leg had been contused about two months before, and that about five weeks since it first began to swell. The child, during this period, had become thin, and her rest had been disturbed by severe local pain. The pain was most intense in the evening and the first part of the night. She had had rigors, especially of an evening. The girl's general health was but little disturbed. The patient had a clear, delicate, bright skin, bright colour in the cheeks, black irides, and well-formed features, but a decidedly strumous diathesis. Her little brother was the subject of strumous disease of the knee joint. In the region of the upper third of the fibula of the left leg was a swelling, the circumference of which measured eleven inches, whilst that of the same region of the healthy limb was eight. The left leg and foot were swelled, but not œdematous. At this visit, although the thought of carcinoma crossed my mind, I yet hoped that an abscess might form, for a sensation as of deep fluctuation was just perceptible. The skin was not discoloured. The secretions being a little disturbed, and the tongue white, a mild alterative and tonic were administered, and local fomentations were employed.

January 20th.—The child had been a great sufferer since the last visit; she was thinner, and looked distressed. The swell-

Digitized by Google

ing had increased three-quarters of an inch in circumference, and a sensation of fluctuation seemed even more manifest. The temperature of the swelling was 96°; of the corresponding region of the healthy limb, 88° (Fahr.) The treatment before advised was continued.

February 7th.—The circumference of the limb in the region of the swelling was now 14 inches, it having increased $2\frac{3}{8}$ inches in eighteen days. Nodules could now be felt in various parts of the tumor, which were soft and yielding; and the whole mass had extended upwards, downwards, and backwards. The sensation of fluctuation had disappeared, and I now no longer entertained any doubt of the nature of the disease, believing it to be carcinoma. The child's healthy aspect had faded, but the pain had somewhat abated, (probably from the fascia having yielded to the outburst of the growth.)

February 23rd.—The child was admitted into Guy's, the tumor having extended, her health failing, her rest prevented by her sufferings, and the surface of the tumor nodulated, the skin congested, and the veins large. Amputation of the leg was advised, as the only means by which to save the child's life; but to this the parents would not consent, and they removed her home. A few days after this, Mr. Murdoch of Rotherhithe explored the tumor, but a sanguineous discharge was all that came away.

March 9th.—The girl was again admitted into Guy's, the tumor having increased, the superficial veins more distinct about and over it, the skin shining and tense. Her general health was rapidly failing, and the parents were desirous that the removal of the limb should be performed.

The drawing presented was made at this time, and it faithfully represents therefore thirteen weeks' growth, or about three months.

The limb was not in any way affected above the knee, and the inguinal lymphatic glands, so far as manipulation indicated, were in a normal condition.

March 12th.—I removed the leg by a circular-flap amputation, above the knee. The tissues appeared perfectly healthy.

A section of the disease made through the vertical axis of

Digitized by Google

the fibula displayed a mass of carcinoma medullare surrounding and destroying the body and shaft of the bone, and the surrounding muscles. The outline of the periosteum of the fibula was very curiously apparent, and lines like rays extended outwards from a body representing the figure and form of the bone. In the lower third of the fibula the new formation was developed between the osseous tissue and the periosteum.

Mr. BIRKETT, 15*th of March*, 1853.

7.—*Two large Tumors of the Breast.*

The first specimen was a tumor removed from the left breast of a woman, aged fifty-five, by Mr. Fergusson. After removal, it was found that the hand could be passed from the surface into a deep pouch, the great extent of which had not been discovered during life, in consequence of the extreme sensitiveness of the external surface of the tumor to the touch.

This cavity was laid open, and from all sides of it passed off in different directions smaller channels, varying much in diameter as well as in depth. The walls of these cavities were smooth, moistened with a mucous secretion and a little pus. The epithelium was large and scaly. When a section was made through different parts of the tumor, certain portions were found to be very hard, and presented a lobulated arrangement, while in other situations the tissue was found to be soft and pulpy, owing to an œdematous condition of the areolar tissue.

The hard, lobulated portions, upon microscopical examination, were found to consist chiefly of fibrous tissue, the fibres of which, for the most part, were arranged in curved lines, intersected in every point by similar fibres. In the meshes formed by this tissue were a few faintly granular cells, some being of an oval or circular form, others elongated, and a few spindle-shaped and prolongated at either end into delicate fibres. A few only contained a nucleus, the majority being of a granular structure, and the outline faint and ill-defined. Free oil-globules, blood-corpuscles, and granular particles, were also present. Small portions of the ducts, which had been broken

Digitized by Google

off in preparing the specimen, were seen here and there scattered about the field. The epithelium of the ducts was abundant, distinct, and well defined.

The addition of acetic acid to a small portion of the hard fibrous matter, rendered the preparation more transparent: the cells were seen more distinctly, their outline being well defined, but they appeared smaller than before the addition of the reagent.

The great bulk of this tumor consisted, therefore, of fibrous or hypertrophied cellular tissue, the looser parts being infiltrated with much serous fluid—a point to which Mr. Fergusson drew attention.

The microscopical characters of one of the small œdematous and pendulous portions of the tumor projecting into the large central cavity, is shown in Plate IX, fig. 2. The large dark bodies are, I believe, mucous follicles. The cells were devoid of nuclei, highly granular, and differed much in size. The addition of acetic acid caused a nucleus to become visible in a few; others were scarcely affected, or their outline only rendered more distinct by the addition of this reagent.

The lining membrane of the large central cavity was covered with much scaly epithelium.

The patient from whom this tumor was removed, was fifty-five years of age, unmarried, and followed the occupation of cook.

The catamenia ceased about eighteen months ago. About two years before her admission she was struck on the left breast by a man's elbow. A tumor about the size of a walnut appeared a few months afterwards, and increased very slowly in size until menstruation ceased, when it commenced growing very rapidly. Nineteen months after the tumor had first been seen, its size was so great as to render removal absolutely necessary.

The tumor presented a soft fungous portion externally, in the form of two lips (the opening of the pouch above referred to), between which there was a fissure large enough to admit three fingers very readily. The surface was exquisitely painful, and secreted a moderate quantity of pus.

Digitized by Google

The tumor was removed on the 19th of February, and was found to weigh five pounds. "The patient is now in a condition to leave the hospital, and the wound is healed (March 15th)."

Large tumor, weighing 18½ pounds, removed from the left breast of a woman, aged forty years. A cavity was also present in this tumor, but only extended to a depth of five or six inches. Upon making a section of the mass, numerous cysts containing fluids of very different character were opened. The cysts varied in size from that of a walnut to that of an orange. Some contained clear serum, others a dark-brown grumous fluid.

The greater portion of the tumor consisted of a firm, hard, and somewhat transparent substance, disposed in large and indistinctly lobular masses, a section of many of which showed the cut orifices of large venous, sinuous, and lacteal, ducts. The hard, glairy, transparent part of the tumor consisted chiefly of fibrous tissue, with a few granular cells, and cells containing oil-globules (Plate IX. Fig. 3, A). The fibrous tissue was infiltrated with much serous fluid, and a thin section, which at first appeared perfectly transparent, became quite opaque upon the application of heat, or upon the addition of nitric acid. Adjacent to the perfectly transparent parts of the tumor were others which were more opaque, and appeared as represented at B. In these situations, the fibres were less distinct in consequence of being obscured by the presence of numerous minute granular cells.

Fig. 4, C, Plate IX., shows a portion of a milk-duct, with its thick layer of epithelium, with granular cells and fibre-cells from the adjacent parts of the tumor.

Here and there interspersed in numerous parts of the tumor were some small opaque white spots, about the size of a hemp-seed, or a little larger, consisting of matter much resembling cream. These were most abundant at the base of many small pendulous processes, which were found to project into some of the cysts. Upon microscopical examination, these white spots were found to be made up of large cells containing oil, free oil-globules, and numerous crystalline plates of choles-

Digitized by Google

Digitized by Google

DESCRIPTION OF PLATE IX.

FIG. 1 illustrates Mr. Toynbee's case of neuroma of the auditory nerve. Page 259.

Fig. 1. (*a*) represents the portion of nerve supplying the cochlea; (*b*) the branch to the tumor; (*c*) the portion to the vestibule.

FIGS. 2, 3, 4 illustrate Dr. Lionel Beale's cases of tumors of the breast. Page 272.

Fig. 2. Portion of one of the œdematous pendulous masses, about the size of a pea, which projected into the cavity: blood-vessels, mucous follicles, granular cells, with a few blood-corpuscles and oil-globules, are shown in it. Magnified 200 diameters. Drawing about half observed size.

Fig. 3. Portion of hard and transparent part of tumor. (A) Fibrous tissue infiltrated with serum; this became quite opaque upon the application of heat, or by the addition of nitric acid. (B) Contiguous portion, containing numerous minute cells, fat-cells, and free oil-globules.

Fig. 4. (C) Portion of tube, with epithelium. (*d*) Fat-cell. (*e*) Oil-globule. (*f*) Fibre-cell. These are from the hard part, constituting a considerable portion of the bulk of the tumor. (D) One of the opaque white spots seen in many parts of the tumor, consisting of a collection of fat cells (*g*) apparently forced out of the ducts, and plates of cholesterine.

Digitized by Google

Fig 1.

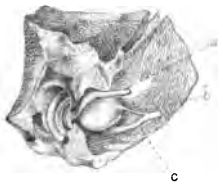

H Poynter del

Fig 2.

A.

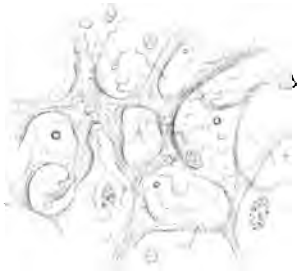

Fig 3.

B



C.

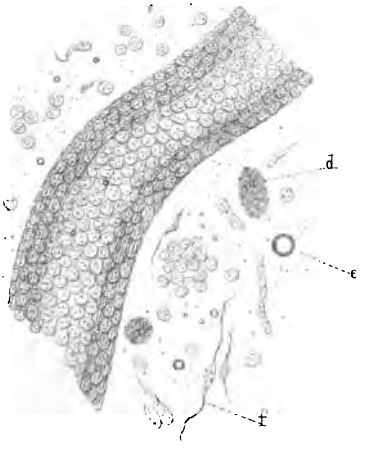

Fig 4.

D.

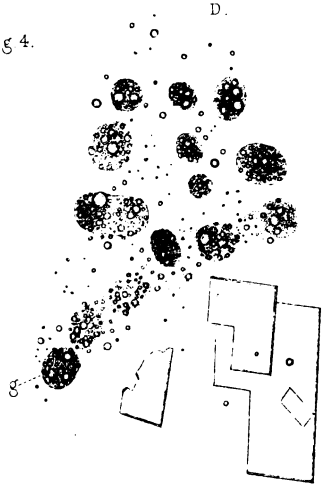

Digitized by Google

Digitized by Google

terine (Plate IX., fig. 4, D). The cells resembled those found in the ducts of the healthy gland, and such as are often present in the colostrum.

The patient from whom this tumor was removed was married, but had never had any children. She was admitted into the hospital on the 24th of February, 1853, under the care of Mr. Fergusson. The catamenia ceased eight months ago. Two years before admission the patient noticed a small tumor in the left breast, which increased very slowly at first, but grew rapidly when she ceased to menstruate. The tumor at the time of operation was as large as three adult heads, and measured three feet round the base. It was removed on the 26th of February, 1853, and was found to weigh 18½ pounds.

Dr. LIONEL BEALE, *15th of March*, 1853.

8.—*Gelatiniform Cancer of the Breast.—Removal.—Return of the Disease in the Cicatrix, after five Years and a half.—Death by Effusion into the Chest.*

Mrs. B., aged fifty-six, came under my care on the 13th of September, 1834, at the London Dispensary. The following history was taken at the time: She is a healthy-looking woman; has been many years married, but has had no family. She has considerable enlargement of the thyroid gland, which has existed since she had the hooping-cough when a child. She ceased menstruating at the age of fifty-one.

She was under the care of the late Mr. Tyrrell seven years ago, for a tumor (not ulcerated) in the right breast, and another in the right armpit, both of which were removed by the knife, and the wound healed perfectly in a month. She was compelled to use her arm soon afterwards, and has ever since been constantly compelled to do so. About eighteen months ago a hardness was noticed on the termination of the wound towards the nipple. A scab then formed, which when removed was followed by another, and there has been, and still is, in this situation, a small ulcer, with stony, hard, puckered edges, very firmly attached to the parietes of the chest. About one-

Digitized by Google

third from the outer termination of the cicatrix is a small lobulated tubercle, which has existed four months, and which evidently increases. It is of purple colour, covered with crimson vessels, and surrounded by a similar stony induration, firmly attaching it to the chest.

She has now and then darting pains in these spots; all other parts of the cicatrix appear quite healthy; there is no hardness or pain in the axillary or cervical glands; there is no cough or evidence of pulmonary affection; there is a superficial ulcer upon the left leg, but her general health is exceedingly good; her face is florid; her appetite is good, and she rests well. A henbane pill night and morning, and a lead lotion, were prescribed.

November 21st.—The ulcer is much the same; tubercle rather larger and more oval; the vessels have disappeared, and it is of purple colour; it broke last night, and discharged a teaspoonful of blood, and there is in this situation a deep-red cauliflower-like-looking fungus, the size of a pea, covered with blood. She does not suffer much pain; pulse 96; tongue lean; bowels open.

November 24th.—Fungus larger; discharges a bloody serum; more pain; the tumor seems ulcerating below.

December 1st.—Fungus has degenerated into an ulcer larger than a shilling, with pale, hard edges; in the centre are two or three chocolate-coloured lobules like grapes, from which a bloody ichor discharges; no other alteration. Opiate lotion.

December 15th.—Much easier; ulcer much the same; is going into the country for a month.

September 21st, 1835.—She remained two months in the country, and returned very much better in health. I did not, however, see her again until to day. She looks much the same. For the last four days she has had cough and dyspnœa, and a difficulty of lying down upon the right side. For the last week her right arm has swollen considerably, and been painful; there is coldness, thickness, and some œdema of the fingers of this hand, and considerable heat and swelling about the elbow. The first ulcer is much the same as before; the other is larger and less vascular. Axillary glands do not appear hardened

Digitized by Google

There is not much pain. Powdered opium, one grain at night and in the morning.

November 27th.—The ulcers had scarcely varied at all; the redness of the integuments of the right arm and the swelling somewhat subsided, but the hardness and tenseness continued. She had a troublesome cough, wheezing, dyspnœa, and sense of weight in the chest, with great emaciation; and although relieved by blistering, expectorants, hyoscyamus, and mild tonics, she died in the evening from effusion into the chest.

Post-mortem examination, three days after death.—The arm had very considerably diminished in size, but was somewhat thickened. It was not examined. The tumors in the course of the cicatrix had extended as far as the ribs, and implicated them. They were specimens of colloid cancer, and appeared much the same as during life, although not so vascular. One had a fibrous appearance, the other, a vascular; and into one of these blood had been effused. Upon incising it posteriorly, the gelatiniform appearance was beautifully shown. The lungs were congested, and the air-cells somewhat dilated, but they were not at all affected by malignant disease. There was about a pint of serous fluid in each side of the chest. The heart was healthy. The other viscera were not examined.

Remarks.—This preparation seemed to deserve the attention of the Society, although not a recent specimen: partly as it illustrates the efficacy of the removal of the breast affected with malignant disease, occasionally, with a view of prolonging life, even though a perfect cure cannot be obtained; but chiefly in consequence of the following remarks by Mr. Birkett in his valuable work upon diseases of the breast.

"A form of carcinoma termed colloid or gelatiniform cancer, is found very rarely in the female breast. Professors Muller and Rokitansky have each seen one case of this morbid growth in the mammary gland. There is a preparation of this disease in the Museum of the London Hospital, and in that of St. Thomas's.

"I have been able to obtain only one specimen for minute examination, and this was from my friend Mr. Robinson, of Camberwell, who removed it several years ago. It had been in

Digitized by Google

spirit, and therefore, perhaps, its characters were changed. A thin section, however, presented under the microscope, a very striking resemblance to the structure delineated by Professor Muller in his work. The chief peculiarity of this tissue is to preserve its transparency after long immersion in alcohol." page 252.

Mr. R. R. Robinson, 17*th of May*, 1852.

*** Specimens of disease were also presented by Dr. Sibson, Mr. Avery, Dr. Risdon Bennett, Mr. Brook, Dr. Hamilton Roe, Mr. W. Adams, Mr. Marshall, and Mr. E. Pye Smith; but descriptions of these specimens have not been communicated to the Secretaries.

Digitized by Google

INDEX.

Abdominal aorta, aneurism of, 110.
Abscess, calculous, in the pelvis, 196.
„ of the periosteum, with pericarditis, 61.
Abscesses of the liver, with ulceration of the portal vein, 165.
Anæmia, with fatty liver, hepatic peritonitis, ulceration of stomach, hæmatemesis, 133; report on, 136.
Anchylosis, bony, of stapes to fenestra ovalis, 253.
„ membranous, section of knee-joint affected with, 250.
Aneurism of abdominal aorta, 110.
„ ascending aorta, 105.
„ „ bulging into right ventricle, and closing pulmonary artery, 112.
„ „ communicating with the pulmonary artery, 114.
„ of commencement of aorta, with malformed aortic valves, 108.
Anus, artificial, operation for; intestinal obstruction, 147.
Aorta, abdominal, aneurism of, 110.
„ ascending, aneurism of, 105, 112, 114.
„ atheromatous deposit on, and rupture of one valve of, 100.
„ aneurism of commencement of, with malformed aortic valves, 108.
Aortic valves, diseased, 102.
„ „ with fibrinous deposit, 99.
„ in an infant, malformation of, 96, 101.
„ malformed; aneurism of commencement of aorta, 108.
Apoplectic clots; onanism; ossification of the cerebral arteries, 19.
Apoplexy of the pons Varolii, 28.
Arteries, small, of the brain, ossification of, 117.
Arthritic enlargement of head of femur and of patella, 246.
Artificial anus, operation for; intestinal obstruction, 147.
„ membrane, substituted for perforate membrana tympani, 254.
Ascending aorta, aneurism of, 105.
„ „ bulging into right ventricle, and closing pulmonary artery, 112
„ „ communicating with pulmonary artery, 114.
Atheromatous deposit on the aorta, and rupture of one of the valves, 100.
Auditory nerve, neuroma of, 259.

Base of the brain, tumor at, 16; report on, 18.
Bichloride of mercury, poisoning by, 140.
Bladder, hernia of, into the scrotum, 187.
Blood, excessive number of white cells in, 261.
„ extravasation of, into the pons Varolii and cerebellum, 15.
„ „ into the spinal cord, 13.
„ „ into the substance of the brain, 22.

Digitized by Google

Bone, arrest of, in the œsophagus, with disease of spinal marrow, &c., 27.
Boy, large calculus from, 205.
Brain, extravasation of blood into the substance of, 22.
„ kidney, and liver, scrofulous tumors in, 20.
„ ossification of the small arteries and capillaries of, 117.
„ softening of, with fibrin in the sinuses of, 25.
„ „ from obstruction of middle cerebral artery, 29.
„ tumor at the base of, 16.
Breast, lobular hypertrophy and scirrhus of, 267; report, 267.
„ two large tumors of, 272.
„ gelatiniform cancer of, 275.

Calcareous concretions of the peritoneum, 164.
Calculi, renal, in the kidneys, 192.
Calculous abscess in the pelvis, 196.
Calculus, and cyst in the kidney, 194.
„ large, from a boy, 205.
„ peculiarly-shaped, and encysted, 204.
Cancer, encephaloid, of dura mater, spine, ribs, &c., 7.
„ „ of uterus, and the neighbouring lymphatic glands, &c., 224.
„ „ of the kidneys, 191.
„ epithelial, of the tongue, in a gouty subject, 121.
„ medullary, (?) of liver, masked by, and mistaken for, simple pregnancy, 167.
„ „ of leg, 270.
„ „ of pleura and endocardium, 39.
„ and miliary tubercle, coëxistence of, in the lungs, 35; report on, 37.
„ and tubercle in the lungs, 102.
„ villous, of large intestine, 154.
Capillaries and small arteries of the brain, ossification of, 117.
Carcinomatous growths, encephaloid, from the dura mater, 2.
Caries of the dorsal vertebræ, 4.
Cerebellum, congenital absence of part of; chronic hydrocephalus, 31.
Cerebellum, extravasation of blood into, 13.
Cerebral arteries, ossification of, 19.
„ artery, middle, softening of brain from obstruction of, 29.
„ vessels, fatty and earthy degeneration of, 28.
Chest, effusion into, consequent on relapse after operation for gelatiniform cancer of breast, 275.
„ morbid growth involving the walls of, 268.
Chloroform, death by, in fatty degeneration of the heart, 76.
Cholesterine crystals in a renal cyst, 193.
Clitoris, excessive enlargement of, 207.
Closure of foramen ovale after birth, mode of, 85.
Concretions, calcareous, of the peritoneum, 164.
Congenital absence of part of cerebellum; chronic hydrocephalus, 31.
„ union of two aortic valves, 100.
Contraction of mitral orifice, with diastolic murmur, 104.
Cord, spinal, extravasation of blood into, 13.
Crus cerebri, scrofulous deposit in, 23.
Cyanosis, 81.
„ remarks on the production of, 87; report on, 94.
Cyst in the kidney, containing cholesterine crystals, 193.
„ contents of, 193.
„ with calculus, 194.
„ large, connected with the right kidney, 199.
Cysto-sarcoma of the mamma, 265.

Death, sudden, in an infant: malformation of aortic valves, 96.
Degenerated placenta, 238.
Degeneration, fatty and earthy, of the cerebral vessels, 28.
„ „ and enlargement of heart and liver, 63.
„ „ and granular, of the heart, 71.

Digitized by Google

Degeneration, fatty, of the heart; death by chloroform, 76.
„ „ „ death by rupture of the left ventricle, 80.
„ „ „ in a child, 80.
„ „ (?) in an infant; malformed aortic valves, 96.
„ „ of the uterine fibres, 209.
„ of the mucous membrane of the stomach, 124.
Deposit, unorganized, in the spleen, consequent on typhus fever, 170.
Deposits, fibrinous, in the spleen, thoracic glands, &c., 177; report on, 178.
Diaphragmatic and pulmonary pleura, medullary cancer of, 39.
Diastolic murmur, with contraction of mitral orifice, 104.
Diathesis, fibro-albuminous, 142.
Dilated stomach, 137.
Diseased aortic valves, 102.
„ „ with fibrinous deposits, 99.
„ mitral valve, 103.
Dislocated first phalanx of thumb, with fractured metacarpal bone, dissection of, 250.
Dissecting the ear for pathological investigation, 257.
Dorsal vertebra, the last, fracture of, 1.
„ vertebræ, caries of, 4.
Dura mater, encephaloid cancer of, &c., 7.
„ „ carcinomatous growths from, 2.

Ear, diseased, 25.
„ dissecting, for pathological investigation, 257.
Encephaloid cancer of the dura mater, spine, ribs, &c., 7.
„ „ of the kidneys, 191.
„ „ of the uterus, involving neighbouring lymphatic glands, &c., 224.
„ carcinomatous growths from the dura mater, 1.
„ disease of femur, 246.
Enchondroma of left testicle, 180.
Encysted, peculiarly-shaped calculus, 204.
Endocardium of right ventricle, cancerous nodule of, 39.
Enlargement and fatty degeneration of heart and liver, &c., 63.
„ excessive, of the clitoris, 207.
Epithelial cancer of the tongue, in a gouty subject, 121.
Extravasation of blood into the pons Varolii and cerebellum, 15.
„ „ into the spinal cord, 13.
„ „ into the substance of the brain, 22.

Fallopian tubes and peritoneum, deposit of tubercle in, 157.
Fat and hair in cysts in ovarian tumor, 234.
Fatty condition of the heart in various diseases, 68.
„ degeneration and enlargement of heart and liver, 63.
„ „ of heart; death by chloroform, 76.
„ „ „ death by rupture of left ventricle, 80.
„ „ „ in a child, 80.
„ „ „ in an infant, with malformation of aortic valves, 96.
„ „ of the uterine fibres, 209.
„ and earthy degeneration of cerebral vessels, 28.
„ and granular degeneration of heart, 71.
„ liver, with hepatic peritonitis, ulceration of stomach, hæmatemesis, &c., 133; report on, 136.
„ matters discharged from a tumor between the rectum and vagina, 236.
Femur, encephaloid disease of, 246.
„ head of, dislocated and separated from the shaft, in chronic hip-joint disease, 242.
Fenestra ovalis, bony anchylosis of stapes to, 253.
Fibrin in sinuses of the brain, 25.
„ quasi-organised, from the urethra, 205.

Digitized by Google

Fibrinous deposit on surface of intestine, with diseased kidney, 142.
„ deposits, with diseased aortic valves, 99.
„ substance obstructing middle cerebral artery, causing softening of brain, 29.
Fibro-albuminous diathesis, as connected with diseased kidney, and fibrinous deposit on surface of intestine, 142.
Fibro-cystic tumor of uterus, 215.
Fibrous tumors of uterus; uterine polypi, 212.
Foramen ovale, mode of closure of, after birth, 85.
„ very small; cyanosis, 81.
Fracture of last dorsal vertebra, with destruction of spinal marrow, 1.
„ metacarpal bone, and dislocated first phalanx of thumb, dissection of, 250.

Gelatiniform cancer of breast, 275.
Gouty subject, epithelial cancer of tongue in, 121.
Granular and fatty degeneration of the heart, 71.
Growth, morbid, involving walls of chest, 268.

Hæmatemesis, malignant (?), with ulceration of stomach, hepatic peritonitis, fatty liver, &c., 133; report on, 136.
Hæmatoid crystals in hydatid of liver, 166.
Hair and fat in cysts, in ovarian tumor, 234.
Heart, fatty condition of, in various diseases, 68.
„ „ degeneration of; death by chloroform, 76.
„ „ „ death by rupture of left ventricle, 80.
„ „ „ in a child, 80.
„ „ „ in an infant, with malformation of aortic valves, 96.
„ „ and granular degeneration of, 71.
Heart and kidneys, diseased, 73.
„ and liver, fatty degeneration and enlargement of, 63.
„ malformation of; closing of orifice of pulmonary artery, &c., 81.
„ with a single ventricle; cyanosis, 87; report on, 94.
Hepatic peritonitis, with fatty liver, ulceration of stomach, hæmatemesis, &c., 133; report on, 136.
Hepatitis, lobular, terminating in extensive suppuration, 171.
Hernia of the bladder into the scrotum, 187.
Hip-joint, disease of, 244.
„ „ head of femur dislocated, and separated from the shaft, 242.
Horse, large phlebolithes from, 264.
Hydatid of liver, containing hæmatoid crystals, 166.
Hydatids of left lung, after typhoid fever, and double pneumonia, 44.
Hydrocephalus, chronic; congenital absence of part of the cerebellum, 31.
Hypertrophy of stomach, 128; report on, 133.
„ lobular, and scirrhus of breast, 267; report on, 267.

Jejunum, rupture of; laceration of mesentery, 151.
Internal strangulation, caused by adhesion of vermiform process to ovary, 146.
Intestinal obstruction; operation for artificial anus, 147.
Intestine, fibrinous deposit on surface of, with disease of kidney, as connected with the fibro-albuminous diathesis, 142.
„ large, villous cancer of, 154.
„ small, almost complete obstruction of, from injury, 156.
„ specimen of, in typhoid fever, 142.
Intestines, small, ulceration, stricture, and perforation of, 152.
Intervertebral cartilage, ulceration of, 27.

Digitized by Google

Investigation, pathological, dissecting the ear for, 257.

Kidney, calculus and cyst in, 194.
„ contents of cyst in, 193.
„ cyst in, containing cholesterine crystals, 193.
„ disease of, with fibrinous deposit on surface of intestine, as connected with fibro-albuminous diathesis, 142.
„ encephaloid cancer of, 191.
„ liver, and brain, scrofulous tumors in, 20.
„ right, large cyst connected with, 199.
Kidneys and heart, diseased, 73.
„ lungs, and spleen, tuberculous deposit in, 41.
Knee-joint, section of membranous anchylosis of, 250.

Leg, medullary cancer of, 270.
Liver, abscesses of, with ulceration of the portal vein, 165.
„ brain, and kidney, scrofulous tumors in, 20.
„ fatty, with hepatic peritonitis, ulceration of stomach, hæmatemesis, anæmia, 133; report on, 136.
„ „ with tuberculous infiltration of lungs and spleen, 42.
„ and heart, fatty degeneration and enlargement of, 63.
„ hæmatoid crystals in hydatid cyst of, 166.
„ large tumors in, masked by, and mistaken for, simple pregnancy, 167.
„ scrofulous, with caries of dorsal vertebræ, 4.
Lobular hepatitis, with extensive suppuration, 171.
„ hypertrophy and scirrhus of breast, 267; report on, 267.
Lung, left, hydatids of, after typhoid fever and double pneumonia, 44.
Lungs, coëxistence of cancer and miliary tubercle in, 35; report on, 37.
„ „ „ „ „ and tubercle in, 102.
Lungs, spleen, and kidneys, tuberculous deposit in, 41.
„ „ tuberculous infiltration of, with fatty liver, 42.
Lymphatic glands, secondary encephaloid cancer of, 224.

Malformation of aortic valves, 96, 101.
„ of heart, closure of pulmonary artery, &c., 81.
„ of pulmonary sigmoid valves by excess, 102.
Malformations of umbilical cord, 241.
Malformed aortic valves, aneurism of commencement of aorta, 108.
Malignant (?) hæmatemesis, with ulceration of stomach, fatty liver, &c., 133; report on, 136.
Mamma, cysto-sarcoma of, 265.
Marrow, spinal, destruction of, with fracture of the last dorsal vertebra, 1.
„ „ disease of, following arrest of bone in the œsophagus, 27.
Medullary cancer of pulmonary and diaphragmatic pleura, 39.
„ „ „ of leg, 270.
Membrana tympani, ulceration of fibrous lamina of, 251.
„ „ „ perforate, substitution of artificial membrane for, 254.
Membrane, mucous, of stomach, degeneration of, 124.
Membranous anchylosis, section of knee-joint for, 250.
Mercury, bichloride of, poisoning by, 140.
Mesentery, laceration of; rupture of jejunum, 151.
Metacarpal bone, fractured, with dislocated first phalanx of the thumb, dissection of, 250.
Miliary tubercle and cancer, coëxistence of, in the lungs, 35; report on, 37.
Mitral orifice, contraction of, with diastolic murmur, 104.
„ valve, diseased, 103.
Mole, unusually large, and fleshy, from the uterus, 217.
Morbid growth, involving walls of chest, 268

Digitized by Google

Mucous membrane of stomach, degeneration of, 124.
Muscular tumors of the uterus, 218.

Neuroma of auditory nerve, 259.

Obstruction, complete, of the urethra, 206.
„ intestinal: operation for artificial anus, 147.
„ of middle cerebral artery, causing softening of brain, 29.
„ of small intestine, almost complete, from injury, 156.
Œsophagus, arrest of bone in, followed by disease of spinal marrow, 27.
Omentum and stomach, chronic thickening of, resembling malignant disease, 127; report on, 128.
Onanism: apoplectic clots; ossification of cerebral arteries, 19.
Optic thalamus, scrofulous deposit in, 23.
Orbit, pus in the, with diseased ear, &c., 25.
Ossification of cerebral arteries, 19, 117.
Ovarian tumor, large; uterine polypus; 233.
„ „ with cyst, containing fat and hair, 234.
Ovary, adhesion of vermiform process to, causing internal strangulation, 146.

Patella and head of thigh-bone, arthritic enlargement of, 246.
Pathological investigation, dissecting the ear for, 257.
Pelvis, calculous abscess in, 196.
Perforate membrana tympani, substitution of an artificial membrane for, 254.
Perforation of the stomach, 123, 140.
„ with ulceration and stricture of the small intestines, 152.
Pericarditis, probably caused by abscess of the periosteum, 61.
Pericardium, adherent and perforated, with enlarged and fatty heart and liver, 63.
Periosteum, abscess of, with pericarditis, 61.
„ of spine and ribs, encephaloid cancer of, 7.
Peritonitis, hepatic, with fatty liver, ulceration of the stomach, hæmatemesis, &c. 133; report on, 136.
Peritoneum, calcareous concretions of, 164.
„ and Fallopian tubes, deposit of tubercle in, 157.
„ primary scirrhus of, 159.
Phalanx, first, of the thumb, dislocated, with fractured metacarpal bone, dissection of, 250.
„ ungual, of great toe, disease of, 243.
Phlebolithes, large, from a horse, 264.
Placenta, degeneration of, 238.
Pleura, pulmonary and diaphragmatic, medullary cancer of, 39.
Pneumonia, double, with hydatids of left lung, complicating typhoid fever, 44.
Poisoning by bichloride of mercury, 140.
Polypi, uterine, 212, 214.
Polypus, uterine, 233.
Pons Varolii, apoplexy of, 28.
„ „ and cerebellum, blood extravasated into, 15.
Portal vein, ulceration of, with abscesses of liver, 165.
Pregnancy, simple, large tumors of liver masked by, and mistaken for, 167.
„ tubarian, 230.
Pulmonary artery, closure of orifice of, &c., 81.
„ „ aneurism of ascending aorta, closing, 112.
„ „ „ „ communicating with, 114.
„ and diaphragmatic pleuræ, medullary cancer of, 39.
„ sigmoid valves, malformation of, by excess, 102.
Pus in the orbit, 25.
Pyloric orifice of stomach, ulceration at, 121.

Quasi-organized fibrin from the urethra, 205.

Rectum and vagina, fatty matters

Digitized by Google

discharged from a tumor between, 236.
Renal calculi in the ureters, 192.
Ribs, encephaloid cancer of periosteum of, &c., 7.
Rupture of an aortic valve, with atheromatous deposit, 100.
„ of jejunum: laceration of mesentery, 151.

Scirrhus and lobular hypertrophy of breast; 267; report on, 267.
„ primary, of peritoneum, 159.
Scrofulous deposit in right optic thalamus, and crus cerebri, 23.
„ liver, with caries of dorsal vertebræ, 4.
„ tumors in brain, liver, and kidney, 20.
Scrotum, hernia of the bladder into, 187.
Sigmoid valves, pulmonary, malformation of, 102.
Sinuses of the brain, fibrin in, with cerebral softening, 25.
Softening of the brain, with fibrin in sinuses of, 25.
Spinal cord, extravasation of blood into, 13.
„ marrow, destruction of, with fracture of last dorsal vertebra, 1.
„ „ disease of, caused by arrest of bone in œsophagus, 27.
Spine, encephaloid cancer of periosteum of, &c., 7.
Spleen, lungs, and kidneys, tuberculous deposit in, 41.
„ „ tuberculous infiltration of, with fatty liver, 42.
„ thoracic glands, &c., fibrinous deposits in, 177; report on, 178.
„ unorganized deposit in, consequent to typhus fever, 170.
Stapes, bony anchylosis of, to fenestra ovalis, 253.
Stomach, degeneration of the mucous membrane of, 124.
„ enormously dilated, 137.
„ extensive ulceration of, with hæmatemesis, anæmia, hepatic peritonitis, fatty liver, &c., 133; report on, 136.
Stomach, hypertrophy of, 128; report on, 133.
„ perforation of, 123.
„ „ „ „ : cicatrized ulcers, &c. 140.
„ and omentum, chronic thickening of, resembling malignant disease, 127; report on, 128.
„ ulceration at the pyloric orifice of, 121.
Strangulation, internal, caused by adhesion of vermiform process to the ovary, 146.
Stricture, ulceration, and perforation of small intestines, 152.
Suppuration, extensive, following lobular hepatitis, 171.

Testicle, left, enchondroma, of, 180.
Thalamus, optic, scrofulous deposit in, 23.
Thigh-bone, and head of patella, arthritic enlargement of, 246.
Thoracic glands, spleen, &c., fibrinous deposits in, 177; report on, 178.
Thumb, dislocated first phalanx of, with fractured metacarpal bone, dissection of, 250.
Toe, great, disease of ungual phalanx of, 243.
Tongue, epithelial cancer of, in a gouty subject. 121.
Tubarian pregnancy, 230.
Tubercle and cancer, coëxistence of, in the lungs, 102.
„ deposit of, in peritoneum and Fallopian tubes, 157.
„ miliary, and cancer, coëxistence of, in lungs, 35; report on, 37.
Tuberculous deposit in lungs, spleen, and kidneys, 41.
„ „ infiltration of lungs and spleen, with fatty liver, 42.
Tumor at base of brain, 16; report on, 18.
„ between rectum and vagina, fatty matter discharged from, 236.
„ fibro-cystic, of the uterus, 215.
„ large ovarian: uterine polypus, 233.
„ ovarian, with cysts containing

Digitized by Google

fat and masses of long hair, 234.
Tumors, large, of breast, 272.
„ uterine, 210.
„ „ fibrous: uterine polypi, 212.
„ „ muscular (so-called fibrous), 218.
Typhoid fever, with double pneumonia, followed by hydatids of left lung, 44.
„ „ specimen of intestine in, 142.
Typhus fever, unorganized deposit in spleen, consequent on, 170.

Ulceration, extensive, of stomach, hæmatemesis, hepatic peritonitis, &c., 133; report on, 136.
„ of fibrous lamina of membrana tympani, 251.
„ of intervertebral cartilage, 27.
„ of portal vein, with abscesses in liver, 165.
„ at the pyloric orifice of stomach, 121.
„ stricture, and perforation of small intestines, 152.
Ulcers of stomach cicatrized, 140.
Umbilical cord, malformations of, 241.
Ungual phalanx of great toe, disease of, 243.
Ureters, renal calculi in, 192.
Urethra, quasi-organized fibrin from, 205.
„ complete obstruction of, 206.
Uric acid crystals, peculiar form of, 203.
Uterine fibres, fatty degeneration of, 209.
„ polypi, 212, 214.
„ polypus; large ovarian tumor, 233.
„ tumors, 210.
Uterus, encephaloid cancer of, involving neighbouring lymphatic glands, &c., 224.
„ fibro-cystic tumor of, 215.
„ muscular (so-called fibrous) tumors of, 218.
„ unusually large, fleshy mole discharged from, 217.

Vagina and rectum, fatty matters discharged from a tumor between, 236.
Valve, aortic, atheromatous deposit on, and rupture of, 100.
„ diseased mitral, 103.
Valves, aortic, diseased, 102.
„ „ „ with fibrinous deposits, 99.
„ „ malformation of, in an infant, 96, 101.
„ „ congenital union of two, 100.
„ „ malformed, aneurism of commencement of aorta, 108.
„ „ pulmonary sigmoid, malformation of, 102.
Ventricle, cancerous nodule of the endocardium of, 39.
„ left, rupture of, in fatty degeneration of heart, 80.
„ right, aneurism of ascending aorta bulging into, 112.
„ single: production of cyanosis, 87; report on, 94.
Vermiform process, adhesion of, to ovary, causing internal strangulation, 146.
Vertebræ, last dorsal, fracture of, 1.
„ dorsal, caries of, 4.
Villous cancer of large intestine, 154.

Walls of chest, morbid growth, involving, 268.
White cells in blood, excessive number of, 261.

London: Printed by J. W. Roche, 1, Ann's Terrace.

Digitized by Google

Digitized by Google

Digitized by Google

Digitized by Google

Digitized by Google

Digitized by Google

Digitized by Google

Digitized by Google

Digitized by Google

UNIVERSITY OF MICHIGAN
3 9015 05136 2682

BOUND
JUN 25 1936
UNIV. OF MICH.
LIBRARY

Digitized by Google

Digitized by Google